National Comprehensive Cancer Network®

NCCN Clinical Practice Guidelines in Oncology (NCCN Guidelines®)

Cutaneous Lymphomas

Version 2.2026 — February 13, 2026

NCCN recognizes the importance of clinical trials and encourages participation when applicable and available. Trials should be designed to maximize inclusiveness and broad representative enrollment.

NCCN Guidelines for Patients® available at www.nccn.org/patients

Version 2.2026, 02/13/26 © 2026 National Comprehensive Cancer Network® (NCCN®), All rights reserved. NCCN Guidelines® and this illustration may not be reproduced in any form without the express written permission of NCCN.

PLEASE NOTE that use of this NCCN Content is governed by the End-User License Agreement, and you MAY NOT distribute this Content or use it with any artificial intelligence model or tool.
Printed by Galya Basol Kochav on 2/16/2026 9:44:21 AM. Copyright © 2026 National Comprehensive Cancer Network, Inc. All Rights Reserved.

***Steven M. Horwitz, MD/Chair † Þ**
Memorial Sloan Kettering Cancer Center

***Stephen Ansell, MD, PhD/Vice-Chair ‡**
Mayo Clinic Comprehensive Cancer Center

Weiyun Z. Ai, MD, PhD † ‡
UCSF Helen Diller Family Comprehensive Cancer Center

Jeffrey Barnes, MD, PhD †
Mass General Cancer Center

Stefan K. Barta, MD, MRCP, MS † ‡
Abramson Cancer Center at the University of Pennsylvania

Jonathan Brammer, MD ‡
The Ohio State University Comprehensive Cancer Center - James Cancer Hospital and Solove Research Institute

Mark W. Clemens, MD ʘ
The University of Texas MD Anderson Cancer Center

Utpal P. Davé, MD † ‡
Indiana University Melvin and Bren Simon Comprehensive Cancer Center

Ahmet Dogan, MD, PhD ≠
Memorial Sloan Kettering Cancer Center

Francine Foss, MD † ‡ ξ
Yale Cancer Center/Smilow Cancer Hospital

Zachary Frosch, MD, MSHP ‡
Fox Chase Cancer Center

Joan Guitart, MD ≠ ϖ
Robert H. Lurie Comprehensive Cancer Center of Northwestern University

Ahmad Halwani, MD ‡
Huntsman Cancer Institute at the University of Utah

Bradley M. Haverkos, MD, MPH, MS †
University of Colorado Cancer Center

Richard T. Hoppe, MD §
Stanford Cancer Institute

Eric Jacobsen, MD †
Dana-Farber/Brigham and Women's Cancer Center

Deepa Jagadeesh, MD, MPH † ‡
Case Comprehensive Cancer Center/ University Hospitals Seidman Cancer Center and Cleveland Clinic Taussig Cancer Institute

Allison Jones, MD ϖ
St. Jude Children's Research Hospital/The University of Tennessee Health Science Center

***Youn H. Kim, MD ϖ †**
Stanford Cancer Institute

Kiran Kumar, MD, MBA §
UT Southwestern Simmons Comprehensive Cancer Center

Maria Estela Martinez Escala, MD, PhD ϖ
The UChicago Medicine Comprehensive Cancer Center

Neha Mehta-Shah, MD, MSCI † ‡
Siteman Cancer Center at Barnes-Jewish Hospital and Washington University School of Medicine

Elise A. Olsen, MD ϖ †
Duke Cancer Institute

Chelsea Peterson, DO ‡
Roswell Park Comprehensive Cancer Center

Christina Poh, MD ‡
City of Hope National Medical Center

Saurabh A. Rajguru, MD † ‡
University of Wisconsin Carbone Cancer Center

***Sima Rozati, MD, PhD ϖ**
Johns Hopkins Kimmel Cancer Center

Jonathan Said, MD ≠
UCLA Jonsson Comprehensive Cancer Center

Aaron Shaver, MD, PhD ≠
Vanderbilt-Ingram Cancer Center

Lauren Shea, MD ‡
O'Neal Comprehensive Cancer Center at UAB

***Michi M. Shinohara, MD ϖ ≠**
Fred Hutchinson Cancer Center

Matthew Stephany, MD ϖ
Fred & Pamela Buffett Cancer Center

Susan Thornton ¥
Patient advocate

Carlos Torres-Cabala, MD ≠
The University of Texas MD Anderson Cancer Center

Ryan Wilcox, MD, PhD † ‡
University of Michigan Rogel Cancer Center

Peggy Wu, MD, MPH ϖ
UC Davis Comprehensive Cancer Center

Yumeng Zhang, MD ‡
Moffitt Cancer Center

NCCN
Mary Dwyer, MS
Nicholas Sansone, MFA
Hema Sundar, PhD

ξ Bone marrow transplantation	≠ Pathology
ϖ Dermatology	¥ Patient advocacy
‡ Hematology/Hematology oncology	ʘ Plastic surgery
Þ Internal medicine	§ Radiotherapy/Radiation oncology
† Medical oncology	* Discussion Section Writing Committee Member

NCCN Guidelines Panel Disclosures

Version 2.2026, 02/13/26 © 2026 National Comprehensive Cancer Network® (NCCN®), All rights reserved. NCCN Guidelines® and this illustration may not be reproduced in any form without the express written permission of NCCN.

PLEASE NOTE that use of this NCCN Content is governed by the End-User License Agreement, and you MAY NOT distribute this Content or use it with any artificial intelligence model or tool.
Printed by Galya Basol Kochav on 2/16/2026 9:44:21 AM. Copyright © 2026 National Comprehensive Cancer Network, Inc. All Rights Reserved.

NCCN Cutaneous Lymphomas Panel Members
Summary of the Guidelines Updates

Primary Cutaneous B-Cell Lymphomas
- Principles of Primary Cutaneous B-Cell Lymphomas (CUTB/INTRO)
- Diagnosis and Workup (CUTB-1)
- Primary Cutaneous Marginal Zone Lymphoma (CUTB-2)
- Primary Cutaneous Follicle Center Lymphoma (CUTB-2)
- TNM Classification of Cutaneous Lymphoma Other Than MF/SS (CUTB-A)
- Treatment References (CUTB-B)

Mycosis Fungoides/Sézary Syndrome (MF/SS)
- Principles for Mycosis Fungoides/Sézary Syndrome (MFSS/INTRO-1)
- General Principles (MFSS/INTRO-2)
- Diagnosis (MFSS-1)
- Workup (MFSS-2)
- TNMB Classification and Staging (MFSS-3)
- Clinical Staging (MFSS-4)
- Stage IA (Limited Skin Involvement Alone, <10% BSA) (MFSS-6)
- Stage IB (Skin-Only Disease with ≥10% BSA) - Stage IIA (MFSS-7)
- Stage IIB (Tumor Stage Disease) (MFSS-8)
- Stage III (Erythrodermic Disease) (MFSS-10)
- Stage IV (MFSS-11)
- Large Cell Transformation (LCT) (MFSS-12)
- Suggested Treatment Regimens (MFSS-A)
- Supportive Care (MFSS-B)
- Principles of Phototherapy (MFSS-C)

Primary Cutaneous CD30+ T-Cell Lymphoproliferative Disorders
- Principles of Primary Cutaneous CD30+ T-Cell Lymphoproliferative Disorders (PCTLD/INTRO-1)
- Diagnosis (PCTLD-1)
- Workup (PCTLD-2)
- Primary Cutaneous ALCL (PCTLD-4)
- Lymphomatoid Papulosis (PCTLD-5)
- Therapy References (PCTLD-A)

Subcutaneous Panniculitis-Like T-Cell Lymphoma
- Principles for Subcutaneous Panniculitis-Like T-Cell Lymphoma (SPTCL-INTRO-1)
- Diagnosis and Workup (SPTCL-1)
- SPTCL with HLH, Systemic Disease, or High Tumor Burden (SPTCL-2)
- SPTCL Without HLH and Low Tumor Burden (SPTCL-3)

Primary Cutaneous Indolent T-Cell Lymphoproliferative Disorders (LPD)
- Definition and Clinical Presentation (INCTLD-1)
- Clinical/Histologic Features, Diagnosis, Prognosis, and Staging (INCTLD-2)

Find an NCCN Member Institution: https://www.nccn.org/home/member-institutions.

NCCN Categories of Evidence and Consensus: All recommendations are category 2A unless otherwise specified.

See NCCN Categories of Evidence and Consensus.

NCCN Categories of Preference: All recommendations are considered appropriate.

See NCCN Categories of Preference.

Principles of Radiation Therapy (PCLYM-A)

Principles of Biomarker Testing in Cutaneous Lymphomas (PCLYM-B)

Supportive Care (PCLYM-C)

Use of Immunophenotyping/Genetic Testing in Differential Diagnosis of Mature B-Cell and NK/T-Cell Neoplasms (See NCCN Guidelines for B-Cell Lymphomas - NHODG-A)

Classification (ST-1)
Abbreviations (ABBR-1)

The NCCN Guidelines® are a statement of evidence and consensus of the authors regarding their views of currently accepted approaches to treatment. Any clinician seeking to apply or consult the NCCN Guidelines is expected to use independent medical judgment in the context of individual clinical circumstances to determine any patient's care or treatment. The National Comprehensive Cancer Network® (NCCN®) makes no representations or warranties of any kind regarding their content, use or application and disclaims any responsibility for their application or use in any way. The NCCN Guidelines are copyrighted by National Comprehensive Cancer Network®. All rights reserved. The NCCN Guidelines and the illustrations herein may not be reproduced in any form without the express written permission of NCCN. ©2026.

PLEASE NOTE that use of this NCCN Content is governed by the End-User License Agreement, and you MAY NOT distribute this Content or use it with any artificial intelligence model or tool.
Printed by Galya Basol Kochav on 2/16/2026 9:44:21 AM. Copyright © 2026 National Comprehensive Cancer Network, Inc. All Rights Reserved.

Updates in Version 2.2026 of the NCCN Guidelines for Cutaneous Lymphomas include:

Mycosis Fungoides/Sézary Syndrome
MFSS-A (9 of 12)
- Footnote b revised: Peginterferon alfa-2a *or ropeginterferon alfa-2b-njft (if peginterferon alfa-2a is unavailable)* may be substituted for other alpha interferon preparations (Schiller M, et al. J Eur Acad Dermatol Venerol 2017;31:1841-1847; Patsatsi A, et al. J Eur Acad Dermatol Venereol 2022;36:e291-e293; Osman S, et al. Dermatologic Therapy 2023;2023:7171937*; Mesa R et al. Ann Hematol 2025;104:2571-2573*). (Also for PCTLD-4)

Discussion
MS-1
- The discussion section has been updated to reflect the changes in the algorithm.

Updates in Version 1.2026 of the NCCN Guidelines for Cutaneous Lymphomas include:

Global changes
- Guideline title revised: NCCN Guidelines for ~~Primary~~ Cutaneous Lymphomas.
- References updated throughout the guideline.
- Alpha, beta, delta, and gamma symbols were converted to text.
- "TCR" revised to "TRB, TRG," "TRB and TRG," or "TRG."

New subtype
- Primary Cutaneous Indolent T-Cell Lymphoproliferative Disorders added (INTCLD-1).

Primary Cutaneous B-Cell Lymphomas
CUTB-1
- Diagnosis
  - Useful in certain circumstances
    - ◊ 1st bullet revised: Additional ~~immunohistochemical~~ *IHC panel* ~~studies~~ to establish lymphoma subtype
    - ◊ 3rd bullet revised: Cytogenetics (*fluorescence in situ hybridization [*FISH*]* ~~and karyotype~~ *or conventional chromosome analysis*): t(14;18) if systemic FL is suspected
    - ◊ 5th bullet revised: ~~Next generation sequencing (NGS)~~ *Multigene panel testing (MGPT)* for MYD88 and CD79B mutations (to further help in distinguishing PC-DLBCL, leg type from PCFCL)
- Workup, Essential
  - 5th bullet revised: Chest/~~abdominal~~ *abdomen*/pelvic *(C/A/P)* CT with contrast and/or FDG-PET/CT scan (may be omitted if clinically indicated)
  - 7th bullet added: Assess for distress. (Also for MFSS-2, PCTLD-2, PCTLD-3, and SPTCL-1)
- Footnote f added: Refer to the NCCN Distress Thermometer and Problem List, which includes social determinants of health. See NCCN Guidelines for Distress Management (DIS-A). (Also for MFSS-2, PCTLD-2, PCTLD-3, and SPTCL-1)
- Footnote i revised: Fertility preservation options include: sperm banking~~, semen cryopreservation~~, in vitro fertilization (IVF), or ovarian tissue or oocyte cryopreservation. (Also for MFSS-2, PCTLD-2, and PCTLD-3)

Continued

Version 2.2026, 02/13/26 © 2026 National Comprehensive Cancer Network® (NCCN®), All rights reserved. NCCN Guidelines® and this illustration may not be reproduced in any form without the express written permission of NCCN.

PLEASE NOTE that use of this NCCN Content is governed by the End-User License Agreement, and you MAY NOT distribute this Content or use it with any artificial intelligence model or tool.
Printed by Galya Basol Kochav on 2/16/2026 9:44:21 AM. Copyright © 2026 National Comprehensive Cancer Network, Inc. All Rights Reserved.

Updates in Version 1.2026 of the NCCN Guidelines for Cutaneous Lymphomas include:

Mycosis Fungoides/Sézary Syndrome

MFSS/INTRO-2
- General Principles
  - 7th bullet, 2nd sub-bullet revised: ~~Most treatments for MF/SS do not result in durable remissions off of treatment.~~ *Durable remissions off treatment are uncommon as most patients experience relapse after discontinuation of therapy.*
  - 10th bullet revised: ~~Responses can vary between the different compartments (ie, skin, blood, lymph nodes). Often decisions to continue or switch therapy are on a clinical basis.~~ *Therapeutic responses often differ across disease compartments—including skin, blood, lymph nodes, and viscera— due to the compartmentalized nature of disease biology and variable drug penetration. For example, agents such as mogamulizumab may demonstrate greater efficacy in the blood and skin than in lymph nodes, while histone deacetylase inhibitors may have variable responses across disease compartments. Consequently, treatment decisions—whether to continue, switch, or combine therapies—are frequently guided by clinical assessment of the dominant disease compartment and symptom burden rather than uniform criteria.*

MFSS-1
- Diagnosis, Useful in Certain Circumstances, 3rd bullet added: Consider FISH or MGPT in selected cases
- Footnote a revised: Principles of *Biomarker Testing* ~~Molecular Analysis~~ in ~~Primary~~ Cutaneous Lymphomas (PCLYM-B). (Also for footnote f, MFSS-2, and PCTLD-1)

MFSS-2
- Essential, Imaging studies, 1st sub-bullet revised: ~~Chest/abdomen/pelvis (C/A/P) CT with contrast or integrated whole body FDG-PET/CTI for T3 or T4 (arms/legs included when disease assessment of entire body is needed)~~ *Integrated whole body FDG-PET/CTI (preferred) or C/A/P CT with contrast for ≥T2b or LCT or FMF, or with palpable adenopathy or abnormal laboratory studies; consider for T2a (patch disease with ≥10% BSA) or otherwise clinically indicated*
- Useful in Certain Circumstances
  - 3rd bullet revised: Rebiopsy skin if suspicious of LCT or FMF ~~and~~ *(*not previously confirmed pathologically*)* or aggressive clinical behavior
  - 4th bullet removed and added to Imaging studies 1st sub-bullet.

MFSS-6
- Treatment and Response Assessment, Inadequate response pathway revised: Persistent *and/or symptomatic* T1 skin disease (Also for MFSS-7)

MFSS-A (2 of 12)
- Skin-Limited/Local (For Limited/Localized Involvement), Useful in Certain Circumstances, 1st bullet revised: Topical calcineurin inhibitor*s* (Pimecrolimus*, Tacrolimus*)
- Treatment Considerations, bullet 9 revised: Topical calcineurin inhibitors can be considered *for affected areas of facial and genital skin and of skin folds* ~~for perioral and periorbital affected areas of skin~~ as a steroid-sparing treatment. *Further efficacy and safety data on long-term use is needed.*

MFSS-A (8 of 12)
- Table 7, Suggested Regimens revised:
  - Added Duvelisib
  - Added Lenalidomide
  - Removed Bortezomib (category 2B)

Continued

Version 2.2026, 02/13/26 © 2026 National Comprehensive Cancer Network® (NCCN®), All rights reserved. NCCN Guidelines® and this illustration may not be reproduced in any form without the express written permission of NCCN.

PLEASE NOTE that use of this NCCN Content is governed by the End-User License Agreement, and you MAY NOT distribute this Content or use it with any artificial intelligence model or tool.
Printed by Galya Basol Kochav on 2/16/2026 9:44:21 AM. Copyright © 2026 National Comprehensive Cancer Network, Inc. All Rights Reserved.

Updates in Version 1.2026 of the NCCN Guidelines for Cutaneous Lymphomas include:

MFSS-A (9 of 12) (continued)
- Footnote e revised: Rapid progression has been reported in patients *receiving pembrolizumab*, who ~~are~~ *test* positive for HTLV~~, receiving pembrolizumab~~. Disease flare is seen in some patients (especially in ~~erythrodermic skin/Sézary patients~~ *patients with erythrodermic MF or SS*) and should be distinguished from disease progression (Khodadoust MS, et al. J Clin Oncol 2020:38:20-28).
- Footnote f revised: Lower doses of alemtuzumab administered subcutaneously have shown lower incidence of infectious complications. While alemtuzumab is no longer commercially available, it may be obtained for clinical use. Recommend CMV monitoring ~~or~~ *and pneumocystis jirovecii pneumonia (PJP)* prophylaxis (PCLYM-C).
- Footnote g added: Duvelisib dosing used in this series is lower than that used in other studies. Initial duvelisib dosing was 15 mg daily with subsequent dose modification based on patient weight (eg, increase to 15 mg BID was considered for a weight >90 kg) and tolerability. Doses ultimately ranged from 15 mg once every other day to BID. One patient received 25 mg once-daily duvelisib (due to the patient's phenobarbital decreasing duvelisib absorption). Bazewicz C, Verardi N, Akilov O. Utility of low-dose duvelisib for advanced mycosis fungoides: a single-institution study. Oncologist 2024;29:272-274.
- Footnote h added: Lenalidomide dosing in the trial initially was 25 mg daily for 21 days but due to a frequently observed combination of debilitating fatigue and transient tumor flare reactions, the study was amended and subsequent patients initiated treatment at a dose of 10 mg daily. The dose was then increased by 5 mg every 28 days to a maximum of 25 mg daily, based on patient tolerability and response. Querfeld C, Rosen S, Guitart J, et al. Results of an open-label multicenter phase 2 trial of lenalidomide monotherapy in refractory mycosis fungoides and Sézary syndrome. Blood 2014;123:1159-1166.

Subcutaneous Panniculitis-Like T-Cell Lymphoma
SPTCL-1
- Useful in Certain Circumstances, 4th bullet revised: ~~Comprehensive genomic profiling~~ *MGPT*
- Essential, 6th bullet: Whole body FDG-PET/CT scanc to assess the extent of ~~subcutaneous~~ *extracutaneous* involvement ~~and exclude systemic involvement~~

Principles of Radiation Therapy
PCLYM-A 3 of 3
- General dose guidelines
  - PC-ALCL, 1st sub-bullet revised: RT for curative treatment: 24~~–30~~ Gy
  - SPTCL, 1st sub-bullet revised: RT for curative treatment: ~~36-45 Gy~~ *adequate dose is uncertain, consensus organizations recommend up to 40 Gy*

Principles of Biomarker Testing in Cutaneous Lymphomas
PCLYM-B 1 of 2
- 1st bullet revised: ~~Genetic~~ *Biomarker* testing, including high-throughput sequencing (HTS)~~, array-based comparative hybridization (CGH)~~, *MGPT, conventional chromosome analysis,* ~~karyotype,~~ or FISH to detect somatic mutations or genetic abnormalities are often informative and in some cases essential for an accurate and precise diagnostic and prognostic assessment of ~~primary~~ cutaneous lymphomas ~~(PCL)~~.
- Heading revised: DUSP22-IRF4 Gene *Fusion* ~~Rearrangement~~

PCLYM-B 2 of 2
- JAK2 Gene Rearrangements added.

Supportive Care
PCLYM-C
- Heading revised: Supportive Care ~~For Patients with Cutaneous Lymphomas~~

Discussion
MS-1
- The discussion section has been updated to reflect the changes in the algorithm.

Version 2.2026, 02/13/26 © 2026 National Comprehensive Cancer Network® (NCCN®), All rights reserved. NCCN Guidelines® and this illustration may not be reproduced in any form without the express written permission of NCCN.

PLEASE NOTE that use of this NCCN Content is governed by the End-User License Agreement, and you MAY NOT distribute this Content or use it with any artificial intelligence model or tool.
Printed by Galya Basol Kochav on 2/16/2026 9:44:21 AM. Copyright © 2026 National Comprehensive Cancer Network, Inc. All Rights Reserved.

PRINCIPLES FOR PRIMARY CUTANEOUS B-CELL LYMPHOMAS (PC-BCL)

Overview & Definition

Three subtypes of PC-BCL:

1. **Primary cutaneous follicle center lymphoma (PCFCL)**
   - **Most common subtype of PC-BCL (57%),[1,2] located primarily in the scalp, face, forehead, and trunk, usually with indolent course and excellent prognosis (5-year overall survival [OS] rate is >95%).**
   - **Typically presents as solitary, firm, and pink to violaceous papules, nodules, plaques, or tumors. Multifocal skin lesions are seen in 15% of cases.[1,2] Ulceration is rare.**
   - **Dissemination to extracutaneous sites is extremely uncommon; cutaneous recurrences occur near the initial site in approximately 30% of cases.**
2. **Primary cutaneous marginal zone lymphoma (PCMZL) (WHO5)/Primary cutaneous marginal zone lymphoproliferative disorder (International Consensus Classification [ICC])**
   - **Second most common subtype of PC-BCL (24%–31%)[1] with distribution primarily on the trunk, upper extremities, and head. Typically presents as solitary or multiple erythematous to violaceous papules, small nodules, plaques, or tumors with indolent course and excellent prognosis (5-year survival rate is 99%).**
   - **Relapses in the skin occur in 50% of patients.**
3. **Primary cutaneous diffuse large B-cell lymphoma (PC-DLBCL, leg type)**
   - **The rarest subtype of PC-BCL (11%–19%), constituting 4% of all primary cutaneous lymphomas. It is distributed mostly to the leg, but not uncommonly (10%–15%) can be found in other sites.[1]**
   - **Typical clinical presentation is red to bluish plaques or tumors located on one or both legs that can ulcerate.**
   - **It is usually aggressive and associated with a poor prognosis (high frequency of extracutaneous relapses) (5-year OS rate is 50%).[2,3]**
   - **Multiple skin lesions, inactivation of *CDKN2A*, and *MYD88* L265P associated with inferior prognosis.**

Continued

References on CUTB/INTRO-A

Note: All recommendations are category 2A unless otherwise indicated.

Version 2.2026, 02/13/26 © 2026 National Comprehensive Cancer Network® (NCCN®), All rights reserved. NCCN Guidelines® and this illustration may not be reproduced in any form without the express written permission of NCCN.

PLEASE NOTE that use of this NCCN Content is governed by the End-User License Agreement, and you MAY NOT distribute this Content or use it with any artificial intelligence model or tool.
Printed by Galya Basol Kochav on 2/16/2026 9:44:21 AM. Copyright © 2026 National Comprehensive Cancer Network, Inc. All Rights Reserved.

PRINCIPLES FOR PRIMARY CUTANEOUS B-CELL LYMPHOMAS (PC-BCL)

Diagnosis

- **PCFCL: punch biopsy/incision/excision of skin lesion preferred to shave biopsy**
  - **Immunophenotype – cells express CD20, CD79a, and BCL6; surface Ig light chain typically positive but cytoplasmic Ig light chain is negative. CD10 can be negative in cases with diffuse growth pattern. BCL2 is usually negative, or minimally expressed.**
  - **When CD10 and BCL2 are strongly expressed, or BCL2 is rearranged, consider a nodal follicular lymphoma (FL) with secondary skin involvement.**
  - **PCFCL is most frequently germinal center B-cell (GCB) subtype.[4] Germinal (or follicle) center phenotype with diffuse large cells in a skin lesion may still be consistent with PCFCL. PCFCL can also present with a mixed nodular/diffuse or purely diffuse pattern that is similar to GCB immunophenotype, which can be easily misdiagnosed as diffuse large B-cell lymphoma (DLBCL).**
- **PCMZL: punch biopsy/incision/excision of skin lesion preferred to shave biopsy**
  - **Immunophenotype – cells are negative for CD10 and BCL6, but are often positive for BCL2, CD20, and CD79a. IgG4 can be expressed in about a third of cases.**
  - **Can be divided into 2 groups with different prognosis based on the immunoglobulin heavy chain *IgH* gene rearrangement: 1) CXCR3-negative and Ig class-switched subtype (IgG, IgA, and IgE), characterized by nodular infiltrates of plasma cells; and 2) a less common subtype that is CXCR3-positive and IgM positive (non class-switched), which may have extracutaneous extension.[5-8] IgG class-switched subtype is a clonal chronic lymphoproliferative disorder (LPD), with indolent course.[8,9]**
- **PC-DLBCL, leg type: punch biopsy/incision/excision of skin lesion preferred to shave biopsy**
  - **Immunophenotype – cells express CD20, CD79a, monotypic immunoglobulins, BCL2 (strong), IRF/MUM1, FOXP1, IgM, and occasionally MYC. CD10 staining is usually negative. Immunophenotype may vary with poor correlation with Hans algorithm, but most cases are positive for MUM1 and BCL2 with variable expression of other markers.**
  - **Gene expression profiling: PC-DLBCL, leg type has been demonstrated to be most commonly activated B-cell (ABC) subtype. Gain-of-function mutations in *MYD88* and *CD79B* co-occur in the so-called "MCD" subtype, and are specific to PC-DLBCL, leg type.[4]**

General Principles

- **PCFCL, PCMZL: If the pathology or clinical presentation is not typical, complete staging with chest/abdomen/pelvis (C/A/P) CT and/or fluorodeoxyglucose (FDG)-PET/CT scan to rule out systemic involvement. Low-dose localized radiation therapy (RT), topical or intralesional steroids, or observation are excellent treatment options.**
- **PC-DLBCL, leg type: Complete staging with FDG-PET/CT scan. Treat with chemoimmunotherapy and localized RT. (See NCCN Guidelines for B-Cell Lymphomas - DLBCL.)**

References on CUTB/INTRO-A

Note: All recommendations are category 2A unless otherwise indicated.

Version 2.2026, 02/13/26 © 2026 National Comprehensive Cancer Network® (NCCN®), All rights reserved. NCCN Guidelines® and this illustration may not be reproduced in any form without the express written permission of NCCN.

PLEASE NOTE that use of this NCCN Content is governed by the End-User License Agreement, and you MAY NOT distribute this Content or use it with any artificial intelligence model or tool.
Printed by Galya Basol Kochav on 2/16/2026 9:44:21 AM. Copyright © 2026 National Comprehensive Cancer Network, Inc. All Rights Reserved.

PRINCIPLES FOR PRIMARY CUTANEOUS B-CELL LYMPHOMAS (PC-BCL)
REFERENCES

[1] Willemze R, Cerroni L, Kempf W, et al. The 2018 update of the WHO-EORTC classification for primary cutaneous lymphomas. Blood 2019;133:1703-1714.
[2] Zinzani PL, Quaglino P, Pimpinelli N, et al. Prognostic factors in primary cutaneous B-cell lymphoma: the Italian Study Group for Cutaneous Lymphomas. J Clin Oncol 2006;24:1376-1382.
[3] Felcht M, Klemke CD, Nicolay JP, et al. Primary cutaneous diffuse large B-cell lymphoma, NOS and leg type: Clinical, morphologic and prognostic differences. J Dtsch Dermatol Ges 2019;17:275-285.
[4] Zhang Y, LeWitt TM, Louissaint A Jr, et al. Disease-defining molecular features of primary cutaneous B-cell lymphomas: Implications for classification and treatment. J Invest Dermatol 2023;143:189-196.
[5] van Maldegem F, van Dijk R, Wormhoudt TA, et al. The majority of cutaneous marginal zone B-cell lymphomas expresses class-switched immunoglobulins and develops in a T-helper type 2 inflammatory environment. Blood 2008;112:3355-3361.
[6] Edinger JT, Kant JA, Swerdlow SH. Cutaneous marginal zone lymphomas have distinctive features and include 2 subsets. Am J Surg Pathol 2010;34:1830-1841.
[7] Kogame T, Takegami T, Sakai TR, et al. Immunohistochemical analysis of class-switched subtype of primary cutaneous marginal zone lymphoma in terms of inducible skin-associated lymphoid tissue. J Eur Acad Dermatol Venereol 2019;33:e401-e403.
[8] Carlsen ED, Swerdlow SH, Cook JR, Gibson SE. Class-switched primary cutaneous marginal zone lymphomas are frequently IgG4-positive and have features distinct from IgM-positive cases. Am J Surg Pathol 2019;43:1403-1412.
[9] Gibson SE, Swerdlow SH. How I diagnose primary cutaneous marginal zone lymphoma. Am J Clin Pathol 2020;154:428-449.

Note: All recommendations are category 2A unless otherwise indicated.

Version 2.2026, 02/13/26 © 2026 National Comprehensive Cancer Network® (NCCN®), All rights reserved. NCCN Guidelines® and this illustration may not be reproduced in any form without the express written permission of NCCN.

PLEASE NOTE that use of this NCCN Content is governed by the End-User License Agreement, and you MAY NOT distribute this Content or use it with any artificial intelligence model or tool.
Printed by Galya Basol Kochav on 2/16/2026 9:44:21 AM. Copyright © 2026 National Comprehensive Cancer Network, Inc. All Rights Reserved.

DIAGNOSIS[a,b]

ESSENTIAL:
- Biopsy of suspicious skin sites
  - Multiple biopsies may be necessary to capture the pathologic variability of disease at diagnosis
- Review of a sufficient number of slides with adequate material to perform a comprehensive workup as described below and/or at least one paraffin block representative of the tumor should be done by a pathologist with expertise in the diagnosis of PC-BCL. Rebiopsy if pathologic findings are non-diagnostic and/or discordant with the clinical presentation
- Adequate biopsy (by punch, incisional, excisional) of all types of clinical lesions present will aid in final diagnosis
- Adequate immunophenotyping to establish diagnosis[c]
  - Immunohistochemistry (IHC) panel may include: CD20, CD3, CD10, BCL2, BCL6, IRF4/MUM1

USEFUL IN CERTAIN CIRCUMSTANCES:
- Additional IHC panel to establish lymphoma subtype
  - IHC panel may include: Ki-67, CD5, CD43, CD21, CD23, cyclin D1, kappa/lambda, MYC (IHC or ISH)
  - Assessment of IgM[d] and FOXP1 expression (to further help in distinguishing PC-DLBCL, leg type from PCFCL)
- EBER-ISH
- Cytogenetics (fluorescence in situ hybridization [FISH] or conventional chromosome analysis): t(14;18) if systemic FL is suspected
- FISH for *BCL2* and *BCL6* rearrangements if MYC (IHC or ISH) is positive
- If adequate biopsy material is available, flow cytometry or molecular analysis to detect IgH gene rearrangement can be useful in determining B-cell clonality
- Multigene panel testing (MGPT) for *MYD88*[d] and *CD79B* mutations (to further help in distinguishing PC-DLBCL, leg type from PCFCL)

WORKUP

ESSENTIAL[e]:
- History and physical exam, including complete skin exam
- Complete blood count (CBC) with differential
- Comprehensive metabolic panel
- Lactate dehydrogenase (LDH)
- C/A/P CT with contrast and/or FDG-PET/CT scan (may be omitted if clinically indicated)
- Pregnancy testing in patients of childbearing potential (if chemotherapy or RT planned)
- Assess for distress[f]

USEFUL IN CERTAIN CIRCUMSTANCES:
- Bone marrow biopsy[g]
- Peripheral blood flow cytometry, if CBC demonstrates lymphocytosis
- SPEP/quantitative immunoglobulins for PCMZL
- HIV testing
- Hepatitis B and C testing[h]
- Discuss fertility preservation[i]

→ PCMZL (CUTB-2)
→ PCFCL (CUTB-2)
→ PC-DLBCL, Leg Type (See NCCN Guidelines for B-Cell Lymphomas - DLBCL)

[a] A multidisciplinary team approach involving hematology/oncology, dermatology, pathology (with expertise in cutaneous lymphoma), and radiation oncology is often optimal for the diagnosis and comprehensive care of patients with PC-BCL.
[b] For non-cutaneous extranodal B-cell lymphomas, see Extranodal MZL of Nongastric Sites in the NCCN Guidelines for B-Cell Lymphomas. A germinal (or follicle) center phenotype and large cells in a skin lesion is not equivalent to DLBCL but is consistent with primary cutaneous germinal/follicle center lymphoma.
[c] See Use of Immunophenotyping/Genetic Testing in Differential Diagnosis of Mature NK/T-Cell Neoplasms in the NCCN Guidelines for T-Cell Lymphomas.
[d] IgM expression should be checked if *MYD88* mutations are identified since these are the cases likely to have systemic involvement.
[e] Rule out drug-induced cutaneous lymphoid hyperplasia.
[f] Refer to the NCCN Distress Thermometer and Problem List, which includes social determinants of health. See NCCN Guidelines for Distress Management (DIS-A).
[g] Often reserved for patients with unexplained cytopenias or if there is clinical suspicion of other subtypes (eg, PC-DLBCL, leg type).
[h] Hepatitis B testing is indicated because of the risk of reactivation with immunotherapy + chemotherapy. See monoclonal antibody and viral reactivation in the NCCN Guidelines B-Cell Lymphomas. Tests include hepatitis B surface antigen and core antibody for a patient with no risk factors. For patients with risk factors or previous history of hepatitis B, add e-antigen. If positive, check viral load and consult with a gastroenterologist.
[i] Fertility preservation options include: sperm banking, in vitro fertilization (IVF), or ovarian tissue or oocyte cryopreservation.

Note: All recommendations are category 2A unless otherwise indicated.

Version 2.2026, 02/13/26 © 2026 National Comprehensive Cancer Network® (NCCN®), All rights reserved. NCCN Guidelines® and this illustration may not be reproduced in any form without the express written permission of NCCN.

PLEASE NOTE that use of this NCCN Content is governed by the End-User License Agreement, and you MAY NOT distribute this Content or use it with any artificial intelligence model or tool.
Printed by Galya Basol Kochav on 2/16/2026 9:44:21 AM. Copyright © 2026 National Comprehensive Cancer Network, Inc. All Rights Reserved.

PRIMARY CUTANEOUS MARGINAL ZONE LYMPHOMA OR FOLLICLE CENTER LYMPHOMA[j]

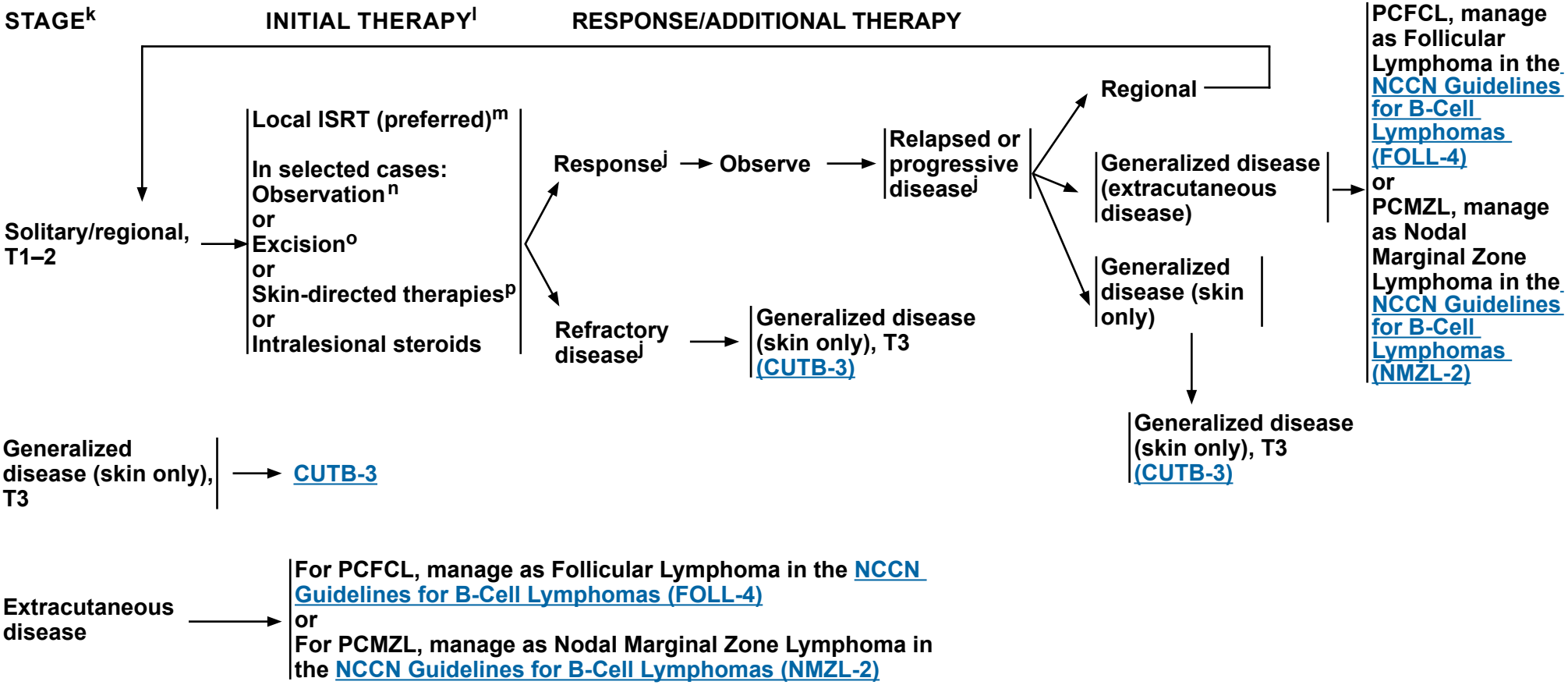

[j] Additional imaging studies during the course of treatment are not needed. FDG-PET/CT or C/A/P CT with contrast at the end of treatment may be needed to assess response or if there is clinical suspicion of progressive disease.
[k] TNM Classification of Cutaneous Lymphoma Other Than MF/SS (CUTB-A).
[l] Treatment References (CUTB-B).
[m] Local ISRT is the preferred initial treatment, but not necessarily the preferred treatment for relapse. See Principles of Radiation Therapy (PCLYM-A).
[n] When ISRT or surgical treatment is neither feasible nor desired.
[o] Small lesions may be excised with minimal non-disfiguring surgery.
[p] There are case reports showing efficacy of skin-directed therapies, which include topical steroids, imiquimod, nitrogen mustard, and bexarotene (useful in pediatric patients).

Note: All recommendations are category 2A unless otherwise indicated.

Version 2.2026, 02/13/26 © 2026 National Comprehensive Cancer Network® (NCCN®), All rights reserved. NCCN Guidelines® and this illustration may not be reproduced in any form without the express written permission of NCCN.

PLEASE NOTE that use of this NCCN Content is governed by the End-User License Agreement, and you MAY NOT distribute this Content or use it with any artificial intelligence model or tool.
Printed by Galya Basol Kochav on 2/16/2026 9:44:21 AM. Copyright © 2026 National Comprehensive Cancer Network, Inc. All Rights Reserved.

PRIMARY CUTANEOUS MARGINAL ZONE LYMPHOMA OR FOLLICLE CENTER LYMPHOMA[j]

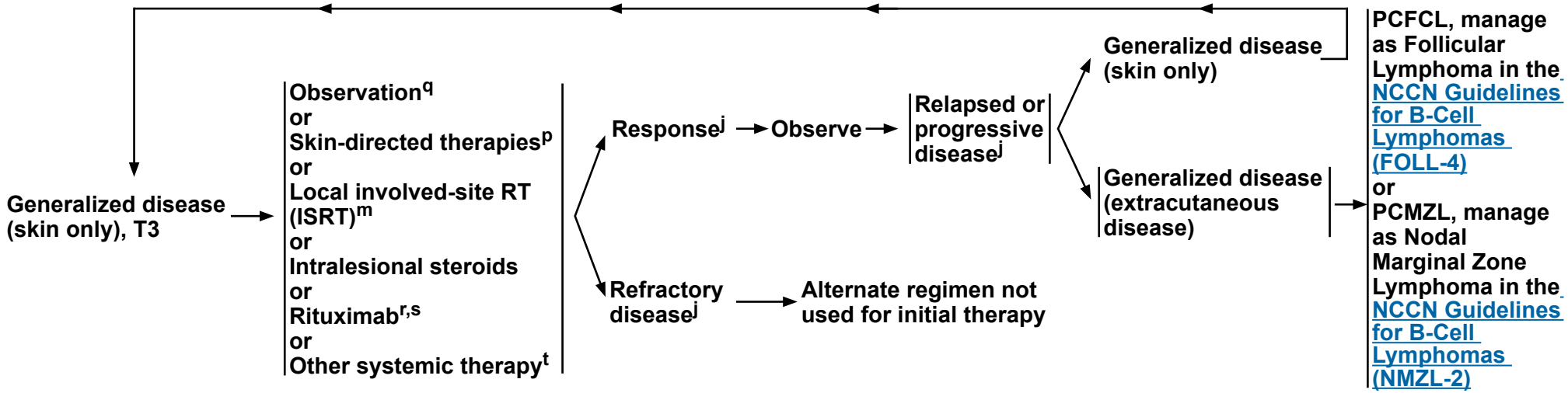

[j] Additional imaging studies during the course of treatment are not needed. FDG-PET/CT or C/A/P CT with contrast at the end of treatment may be needed to assess response or if there is clinical suspicion of progressive disease.
[k] TNM Classification of Cutaneous Lymphoma Other Than MF/SS (CUTB-A).
[l] Treatment References (CUTB-B).
[m] Local ISRT is the preferred initial treatment, but not necessarily the preferred treatment for relapse. See Principles of Radiation Therapy (PCLYM-A).
[p] There are case reports showing efficacy of skin-directed therapies, which include topical steroids, imiquimod, nitrogen mustard, and bexarotene (useful in pediatric patients).
[q] Considered appropriate in asymptomatic patients.
[r] See monoclonal antibody and viral reactivation in the NCCN Guidelines for B-Cell Lymphomas.
[s] Rituximab and hyaluronidase human injection for subcutaneous use may be substituted for rituximab after patients have received the first full dose of rituximab by intravenous infusion. This substitution cannot be made for rituximab used in combination with ibritumomab tiuxetan. An FDA-approved biosimilar is an appropriate substitute for any recommended systemic biologic therapy in the NCCN Guidelines.
[t] In rare circumstances for very extensive or refractory disease, other combination chemoimmunotherapy regimens listed in NCCN Guidelines for B-Cell Lymphomas, FOLL-B can be used.

Note: All recommendations are category 2A unless otherwise indicated.

Version 2.2026, 02/13/26 © 2026 National Comprehensive Cancer Network® (NCCN®), All rights reserved. NCCN Guidelines® and this illustration may not be reproduced in any form without the express written permission of NCCN.

PLEASE NOTE that use of this NCCN Content is governed by the End-User License Agreement, and you MAY NOT distribute this Content or use it with any artificial intelligence model or tool.
Printed by Galya Basol Kochav on 2/16/2026 9:44:21 AM. Copyright © 2026 National Comprehensive Cancer Network, Inc. All Rights Reserved.

TNM CLASSIFICATION OF CUTANEOUS LYMPHOMA OTHER THAN MF/SS[a,b]

TNM		Size/location of lesions		
T				
	T_0*	Absence of clinically suspicious lesions		
	T_1	Solitary lesion	T_{1A}	Solitary lesion <5 cm diameter
			T_{1B}	Solitary ≥5 cm diameter
	T_2	Multiple lesions limited to 1 body region or 2 contiguous body regions[b]	T_{2A}	All disease encompassing a <15-cm-diameter circular area
			T_{2B}	All disease encompassing a 15 to <30 cm diameter circular area
			T_{2C}	All disease encompassing a ≥30 cm diameter circular area
	T_3	Generalized skin involvement	T_{3A}	Multiple lesions involving 2 noncontiguous body regions[b]
			T_{3B}	Multiple lesions involving ≥3 body regions[b]
N				
	N_0	No clinical or pathologic LN involvement		
	N_1	Involvement of 1 peripheral LN region[c] that drains an area of current or prior skin involvement: biopsy positive for lymphoma		
	N_2	Involvement of >2 peripheral LN regions[c] or involvement of any LN region that does not drain an area of current or prior skin involvement: biopsy positive for lymphoma		
	N_3	Involvement of central lymph nodes: biopsy positive for lymphoma		
	N_X	Clinically abnormal peripheral or central LN but no pathologic determination. Other surrogate means of determining involvement may be determined by Tri-Society consensus		
M				
	M_0	No visceral involvement		
	M_1	Visceral involvement		
	M_X	Visceral involvement is neither confirmed nor refuted by available pathologic or imaging assessment		

[a] This work was originally published in Blood. Olsen EA, Whittaker S, Willemze R, et al. Primary cutaneous lymphoma: recommendations for clinical trial design and staging update from the ISCL, USCLC, and EORTC. Blood 2022;140:419-437. © The American Society of Hematology.
[b] For definition of body regions, see Body Regions for the Designation of T (Skin Involvement) Category (CUTB-A 2 of 2).
[c] Definition of LN regions is consistent with the Ann Arbor system: Peripheral sites: antecubital, cervical, supraclavicular, axillary, inguinal-femoral, and popliteal. Central sites: mediastinal, pulmonary hilar, paraaortic, and iliac.

Note: All recommendations are category 2A unless otherwise indicated.

Version 2.2026, 02/13/26 © 2026 National Comprehensive Cancer Network® (NCCN®), All rights reserved. NCCN Guidelines® and this illustration may not be reproduced in any form without the express written permission of NCCN.

PLEASE NOTE that use of this NCCN Content is governed by the End-User License Agreement, and you MAY NOT distribute this Content or use it with any artificial intelligence model or tool.
Printed by Galya Basol Kochav on 2/16/2026 9:44:21 AM. Copyright © 2026 National Comprehensive Cancer Network, Inc. All Rights Reserved.

BODY REGIONS FOR THE DESIGNATION OF T (SKIN INVOLVEMENT) CATEGORY[a,d,e]

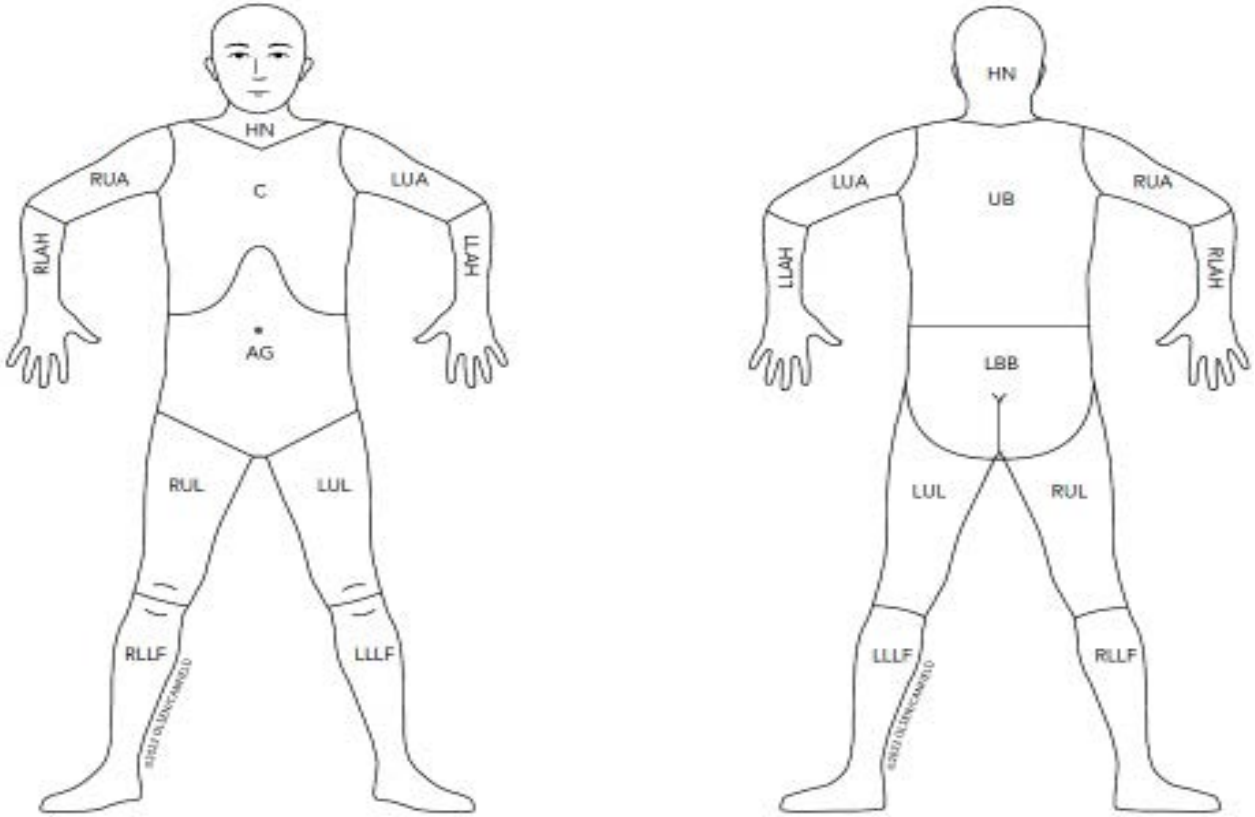

[a] This work was originally published in Blood. Olsen EA, Whittaker S, Willemze R, et al. Primary cutaneous lymphoma: recommendations for clinical trial design and staging update from the ISCL, USCLC, and EORTC. Blood 2022;140:419-437. © The American Society of Hematology.

[d] Left and right extremities are assessed as separate body regions. The designation of these body regions is based on regional lymph node drainage patterns.

[e] Definition of body regions: Head and neck (HN), inferior borders = clavicles anterior and T1 spinous process posterior; left upper arm (LUA), superior border = glenohumeral joint (exclusive of axilla), inferior border = ulnar/radial/humeral (elbow) joint; left lower arm and hand (LLAH), superior border = ulnar/radial/humeral (elbow) joint; right upper arm (RUA), superior border = glenohumeral joint (exclusive of axilla), inferior border = ulnar/radial/humeral (elbow) joint; right lower arm and hand (RLAH), superior border = ulnar/radial/humeral (elbow) joint; chest (C), superior border = superior border clavicles, inferior border = inferior margin rib cage, lateral borders = midaxillary lines and glenohumeral joints (inclusive of axilla); abdomen/genital (AG), superior border = inferior margin rib cage, inferior border = inguinal folds and anterior perineum; upper back (UB), superior border = T1 spinous process, inferior border = inferior margin rib cage, lateral borders = midaxillary lines; lower back/buttocks (LBB), superior border = inferior margin rib cage, inferior border = inferior gluteal fold and anterior perineum (inclusive of perineum), lateral borders = midaxillary lines; left upper leg (LUL), superior border = inguinal fold and gluteal folds, inferior border = midpatella anterior and mid–popliteal fossa posterior; left lower leg and foot (LLLF), superior border = midpatella anterior and mid–popliteal fossa posterior; right upper leg (RUL), superior border = inguinal fold and gluteal folds, inferior border = midpatella anterior and mid–popliteal fossa posterior; right lower leg and foot (RLLF), superior border = midpatella anterior, and mid–popliteal fossa posterior.

Note: All recommendations are category 2A unless otherwise indicated.

Version 2.2026, 02/13/26 © 2026 National Comprehensive Cancer Network® (NCCN®), All rights reserved. NCCN Guidelines® and this illustration may not be reproduced in any form without the express written permission of NCCN.

PLEASE NOTE that use of this NCCN Content is governed by the End-User License Agreement, and you MAY NOT distribute this Content or use it with any artificial intelligence model or tool.
Printed by Galya Basol Kochav on 2/16/2026 9:44:21 AM. Copyright © 2026 National Comprehensive Cancer Network, Inc. All Rights Reserved.

TREATMENT REFERENCES

Skin-directed therapies

Topical/intralesional corticosteroids

Bekkenk MW, Vermeer MH, Geerts ML, et al. Treatment of multifocal primary cutaneous B-cell lymphoma: a clinical follow-up study of 29 patients. J Clin Oncol 1999;17:2471-2478.

Perry A, Vincent BJ, Parker SR. Intralesional corticosteroid therapy for primary cutaneous B-cell lymphoma. Br J Dermatol 2010;163:223-225.

Topical nitrogen mustard

Bachmeyer C, Orlandini V, Aractingi S. Topical mechlorethamine and clobetasol in multifocal primary cutaneous marginal zone-B cell lymphoma. B J Dermatol 2006;154:1207-1209.

Topical bexarotene

Trent JT, Romanelli P, Kerdel FA. Topical targretin and intralesional interferon alfa for cutaneous lymphoma of the scalp. Arch Dermatol 2002;138:1421-1423.

Topical imiquimod

Coors EA, Schuler G, Von Den Driesch P. Topical imiquimod as treatment for different kinds of cutaneous lymphoma. Eur J Dermatol 2006;16:391-393.

Stavrakoglou A, Brown VL, Coutts I. Successful treatment of primary cutaneous follicle centre lymphoma with topical 5% imiquimod. Br J Dermatol 2007;157:620-622.

Rituximab

Morales AV, Advani R, Horwitz SM, et al. Indolent primary cutaneous B-cell lymphoma: experience using systemic rituximab. J Am Acad Dermatol 2008;59:953-957.

Heinzerling LM, Urbanek M, Funk JO, et al. Reduction of tumor burden and stabilization of disease by systemic therapy with anti-CD20 antibody (rituximab) in patients with primary cutaneous B-cell lymphoma. Cancer 2000;89:1835-1844.

Valencak J, Weihsengruber F, Rappersberger K, et al. Rituximab monotherapy for primary cutaneous B-cell lymphoma: Response and follow-up in 16 patients. Ann Oncol 2009;20:326-330.

Senff NJ, Noordijk EM, Kim YH, et al. European Organization for Research and Treatment of Cancer and International Society for Cutaneous Lymphoma consensus recommendations for the management of cutaneous B-cell lymphomas. Blood 2008;112:1600-1609.

Heinzerling L, Dummer R, Kempf W, et al. Intralesional therapy with anti-CD20 monoclonal antibody rituximab in primary cutaneous B-cell lymphoma. Arch Dermatol 2000;136:374-378.

Chemotherapy/Chemoimmuotherapy

Bekkenk MW, Vermeer MH, Geerts ML, et al. Treatment of multifocal primary cutaneous B-cell lymphoma: a clinical follow-up study of 29 patients. J Clin Oncol 1999;17:2471-2478.

Brice P, Cazals D, Mounier N, et al. Primary cutaneous large-cell lymphoma: analysis of 49 patients included in the LNH87 prospective trial of polychemotherapy for high-grade lymphomas. Groupe d'Etude des Lymphomes de l'Adulte. Leukemia 1998;12:213-219.

Hoefnagel JJ, Vermeer MH, Jansen PM, et al. Primary cutaneous marginal zone B-cell lymphoma: Clinical and therapeutic features in 50 cases. Arch Dermatol 2005;141:1139-1145.

Grange F, Beylot-Barry M, Courville P, et al. Primary cutaneous diffuse large B-cell lymphoma, leg type: clinicopathologic features and prognostic analysis in 60 cases. Arch Dermatol 2007;143:1144-1150.

Grange F, Joly P, Barbe C, et al. Improvement of survival in patients with primary cutaneous diffuse large B-cell lymphoma, leg type, in France. JAMA Dermatol 2014;150:535-541.

Rijlaarsdam JU, Toonstra J, Meijer OW, et al. Treatment of primary cutaneous B-cell lymphomas of follicle center cell origin: A clinical follow-up study of 55 patients treated with radiotherapy or polychemotherapy. J Clin Oncol 1996;14:549-555.

Senff NJ, Noordijk EM, Kim YH, et al. European Organization for Research and Treatment of Cancer and International Society for Cutaneous Lymphoma consensus recommendations for the management of cutaneous B-cell lymphomas. Blood 2008;112:1600-1609.

Vermeer MH, Geelen FA, van Haselen CW, et al. Primary cutaneous large B-cell lymphomas of the legs. A distinct type of cutaneous B-cell lymphoma with an intermediate prognosis. Dutch Cutaneous Lymphoma Working Group. Arch Dermatol 1996;132:1304-1308.

Palliative low-dose RT

Neelis KJ, Schimmel EC, Vermeer MH, et al. Low-dose palliative radiotherapy for cutaneous B- and T-cell lymphomas. Int J Radiat Oncol Biol Phys 2009;74:154-158.

Note: All recommendations are category 2A unless otherwise indicated.

Version 2.2026, 02/13/26 © 2026 National Comprehensive Cancer Network® (NCCN®), All rights reserved. NCCN Guidelines® and this illustration may not be reproduced in any form without the express written permission of NCCN.

PLEASE NOTE that use of this NCCN Content is governed by the End-User License Agreement, and you MAY NOT distribute this Content or use it with any artificial intelligence model or tool.
Printed by Galya Basol Kochav on 2/16/2026 9:44:21 AM. Copyright © 2026 National Comprehensive Cancer Network, Inc. All Rights Reserved.

PRINCIPLES FOR MYCOSIS FUNGOIDES/SÉZARY SYNDROME (MF/SS)

Definition

- **Mycosis fungoides (MF)**
  - **MF is the most common cutaneous T-cell lymphoma (CTCL) and many clinicopathologic variants of MF have been described.[1,2]**
  - **Most patients with MF exhibit an indolent clinical course with intermittent, stable, or slow progression of the lesions.**
  - **Extracutaneous involvement may be seen in advanced stages, with involvement of lymph nodes (LNs), blood, or less commonly other organs.[1,2]**
- **Sézary syndrome (SS)**
  - **SS represents the leukemic variant of CTCL and is closely related to MF but has unique characteristics. SS is rare, accounting for <5% of cutaneous lymphomas and predominantly affects older individuals.**
  - **SS is characterized by the presence of atypical T cells (Sézary cells) in skin causing diffuse erythema (erythroderma) and significant blood involvement with abnormal T cells (>1000 abnormal cells/uL) defined as Sézary cells by cytopathologic assessment or flow cytometry (abnormal subsets including but not limited to CD4+CD7- or CD4+CD26- cells); TRBC1 may contribute in detecting clonality and can improve the specificity of detecting Sézary cells when CD7 and CD26 are lost.[3]**
  - **SS is thought to arise from thymic memory T cells, while skin resident effector memory T cells are the cells of origin of MF. This supports the contention that SS is a process distinct from MF.[4] Cases presenting clinically as an overlap of these two conditions exist.**

Diagnosis

- **The histopathologic findings of MF, even in cases showing classic features, need to be correlated with clinical presentation in order to reach a definitive diagnosis.[5]**
- **Patch lesions are often difficult for conclusive diagnosis; thus, in some instances multiple skin biopsies may be necessary for diagnosis. Stopping skin-directed therapy for 2–3 weeks or longer to individual lesions before obtaining a skin biopsy is advisable and may aid in diagnosis.[1,2]**
- **Awareness of specific clinicopathologic variants may aid in accurate diagnosis:**
  - **Lesions may be hyper- or hypopigmented.**
  - **Folliculotropic MF (FMF) may present as folliculocentric papules or nodules or areas of alopecia in any hair-bearing area of the body. A skin biopsy reaching the deep dermis may be required to assess adnexal structures.**
  - **Unilesional, pagetoid reticulosis and CD8+ MF variants tend to be associated with an indolent course.**
  - **Granulomatous slack skin is rare and presents with redundant skin resembling cutis laxa on flexural areas.**
- **By IHC, the tumor cells are usually CD3+, CD4+, and CD8-, although CD8+ variants are not uncommon. In selected cases, additional IHC markers and molecular studies to evaluate clonal *TRB* and *TRG* gene rearrangements are necessary for diagnosis.**
- **Large-cell transformation (LCT) of MF is defined histologically as >25% of the tumor cells displaying large size. CD30 expression may be seen but is not included in the definition of LCT.[6]**
- **The histopathologic findings of SS in skin are generally similar to, but may be more subtle than those seen in MF. Correlation with clinical and laboratory findings in blood is essential for a definitive diagnosis.**

General Principles on MFSS/INTRO-2

References on MFSS/INTRO-A

Note: All recommendations are category 2A unless otherwise indicated.

Version 2.2026, 02/13/26 © 2026 National Comprehensive Cancer Network® (NCCN®), All rights reserved. NCCN Guidelines® and this illustration may not be reproduced in any form without the express written permission of NCCN.

PLEASE NOTE that use of this NCCN Content is governed by the End-User License Agreement, and you MAY NOT distribute this Content or use it with any artificial intelligence model or tool.
Printed by Galya Basol Kochav on 2/16/2026 9:44:21 AM. Copyright © 2026 National Comprehensive Cancer Network, Inc. All Rights Reserved.

PRINCIPLES FOR MYCOSIS FUNGOIDES/SÉZARY SYNDROME (MF/SS)

General Principles

- Multidisciplinary team approach (hematology/oncology, dermatology, pathology, and radiation oncology) with expertise in CTCL is often optimal for the comprehensive care of patients with MF/SS, particularly those with advanced disease.
- Given the rarity of the disease, it is preferred that treatment or consultation occur at centers with expertise in the management of CTCL.
- Evaluation of skin and/or nodal biopsies by a pathologist with expertise in CTCL at a referral center is recommended.
- Folliculotropism and LCT are histologic features that can occur irrespective of stage.
- Recent studies have reported that FMF presents with two distinct patterns of clinicopathologic features with different prognostic implications (early stage and advanced stage); in a subgroup of patients with early skin-limited disease, FMF has an indolent disease course and a favorable prognosis.[7,8,9] Early-stage cutaneous disease is associated with significantly higher disease-specific survival compared to advanced-stage cutaneous disease. Treatment may require skin-directed therapy that reaches the subcutaneous tissue (eg, psoralen plus ultraviolet A [PUVA], ISRT) or the addition of systemic therapy as used for stages I–IIB in patients with disease not responding to skin-directed therapy alone.
- The incidence of LCT is strongly dependent on the disease stage at diagnosis.[10,11] LCT often but not always corresponds to a more aggressive growth rate requiring systemic therapies (MFSS-12).
- Goals of therapy should be individualized but often include:
  - Attain adequate response in order to reduce and control symptoms and minimize risk of progression.
  - Durable remissions off treatment are uncommon as most patients experience disease relapse after discontinuation of therapy.
  - Therapies with lower side-effect profiles and an absence of cumulative toxicity are often given in an ongoing or maintenance fashion to improve and maintain disease control and quality of life.
  - Other than allogeneic hematopoietic cell transplant (HCT), therapies are not given with curative intent.
- Generally, skin-directed therapies and systemic therapy regimens that can be tolerated for longer durations of therapy with lower rates of cumulative toxicity, less immunosuppression, and/or higher efficacy are used in earlier lines of therapy.
- In patients requiring chemotherapy, single agents are preferred over combination chemotherapy, due to the higher toxicity profiles associated with multiagent regimens and the short-lived responses seen with time-limited combination chemotherapy.
- Therapeutic responses often differ across disease compartments—including skin, blood, LNs, and viscera—due to the compartmentalized nature of disease biology and variable drug penetration. For example, agents such as mogamulizumab may demonstrate greater efficacy in the blood and skin than in LNs, while histone deacetylase (HDAC) inhibitors may have variable responses across disease compartments. Consequently, treatment decisions—whether to continue, switch, or combine therapies—are frequently guided by clinical assessment of the dominant disease compartment and symptom burden rather than uniform criteria.
- Disease relapse after discontinuation of therapy may respond to re-treatment with previous therapy.
- Patients having partial responses (PRs) with suboptimal quality of life should be treated with other or additional primary treatment options.
- Use of supportive care measures to minimize risk of skin infections and treat pruritus is an important part of disease and symptom control (MFSS-B).

References on MFSS/INTRO-A

Note: All recommendations are category 2A unless otherwise indicated.

Version 2.2026, 02/13/26 © 2026 National Comprehensive Cancer Network® (NCCN®), All rights reserved. NCCN Guidelines® and this illustration may not be reproduced in any form without the express written permission of NCCN.

PLEASE NOTE that use of this NCCN Content is governed by the End-User License Agreement, and you MAY NOT distribute this Content or use it with any artificial intelligence model or tool.
Printed by Galya Basol Kochav on 2/16/2026 9:44:21 AM. Copyright © 2026 National Comprehensive Cancer Network, Inc. All Rights Reserved.

PRINCIPLES FOR MYCOSIS FUNGOIDES/SÉZARY SYNDROME (MF/SS) REFERENCES

[1] WHO Classification of Tumours Editorial Board. Haematolymphoid tumours. (WHO classification of tumours series, 5th ed.; vol. 11). Lyon (France): International Agency for Research on Cancer; 2024.
[2] Campo E, Jaffe ES, Cook JR, et al. The International Consensus Classification of Mature Lymphoid Neoplasms: a report from the Clinical Advisory Committee. Blood 2022;140:1229-1253.
[3] Olsen E, Whittaker S, Kim YH, et al. Clinical end points and response criteria in mycosis fungoides and Sézary syndrome: a consensus statement of the International Society for Cutaneous Lymphomas, the United States Cutaneous Lymphoma Consortium, and the Cutaneous Lymphoma Task Force of the European Organisation for Research and Treatment of Cancer. J Clin Oncol 2011;29:2598-2607.
[4] Campbell JJ, Clark RA, Watanabe R, Kupper TS. Sezary syndrome and mycosis fungoides arise from distinct T-cell subsets: a biologic rationale for their distinct clinical behaviors. Blood 2010;116:767-771.
[5] Pimpinelli N, Olsen EA, Santucci M, et al. Defining early mycosis fungoides. J Am Acad Dermatol 2005;53:1053-1063.
[6] Talpur R, Sui D, Gangar P, et al. Retrospective analysis of prognostic factors in 187 cases of transformed mycosis fungoides. Clin Lymphoma Myeloma Leuk 2016;16:49-56.
[7] Hodak E, Amitay-Laish I, Atzmony L, et al. New insights into folliculotropic mycosis fungoides (FMF): A single-center experience. J Am Acad Dermatol 2016;75:347-355.
[8] van Santen S, Roach RE, van Doorn R, et al. Clinical staging and prognostic factors in folliculotropic mycosis fungoides. JAMA Dermatol 2016;152:992-1000.
[9] van Santen S, van Doorn R, Neelis KJ, et al. Recommendations for treatment in folliculotropic mycosis fungoides: report of the Dutch Cutaneous Lymphoma Group. Br J Dermatol 2017;177:223-228.
[10] Vergier B, de Muret A, Beylot-Barry M, et al. Transformation of mycosis fungoides: clinicopathological and prognostic features of 45 cases. French Study Group of Cutaneious Lymphomas. Blood 2000;95:2212-2218.
[11] Arulogun SO, Prince HM, Ng J, et al. Long-term outcomes of patients with advanced-stage cutaneous T-cell lymphoma and large cell transformation. Blood 2008;112:3082-3087.

Note: All recommendations are category 2A unless otherwise indicated.

Version 2.2026, 02/13/26 © 2026 National Comprehensive Cancer Network® (NCCN®), All rights reserved. NCCN Guidelines® and this illustration may not be reproduced in any form without the express written permission of NCCN.

PLEASE NOTE that use of this NCCN Content is governed by the End-User License Agreement, and you MAY NOT distribute this Content or use it with any artificial intelligence model or tool.
Printed by Galya Basol Kochav on 2/16/2026 9:44:21 AM. Copyright © 2026 National Comprehensive Cancer Network, Inc. All Rights Reserved.

DIAGNOSIS[a]

ESSENTIAL:

- **Biopsy of suspicious skin sites**
  - **Multiple biopsies may be necessary to capture the pathologic variability of disease at diagnosis**
- **Review of a sufficient number of slides with adequate material to perform a comprehensive workup as described below and/or at least one paraffin block representative of the lesion should be done by a pathologist with expertise in the diagnosis of CTCLs. Rebiopsy if pathologic findings are non-diagnostic and/or discordant with the clinical presentation[b]**
- **IHC panel of skin biopsy may include[c,d,e]:**
  - **CD2, CD3, CD4, CD5, CD7, CD8, CD20, CD30**
- **Molecular analysis to detect clonal *TRB* and *TRG* gene rearrangements or other assessment of clonality[a,f]**

USEFUL IN CERTAIN CIRCUMSTANCES:

- **Assessment of peripheral blood for Sézary cells (extensive skin disease where skin biopsy is not diagnostic, extensive patch or erythrodermic skin disease, and/or strongly suggestive but not diagnostic of advanced-stage disease):**
  - **Flow cytometry to assess and quantitate an expanded T-cell population with aberrant immunophenotype.[a] See MFSS-3 for specifics.**
    - ◊ **Flow cytometry panel may include CD3, CD4, CD7, CD8, CD26, CD45, TRBC1[g] to assess for expanded CD4+ cells with increased CD4/CD8 ratio or with abnormal immunophenotype, including loss of CD7 or CD26**
  - **Sézary cell preparation is less useful than flow cytometry due to the subjective nature of the process but may still be useful in cases where an aberrant immunophenotype is not detected.**
- **IHC panel of skin biopsy may include[b,c]:**
  - **CD25, CD56, TIA1, granzyme B, TCR beta, TCR delta; CCR4,[h] CXCL13, inducible T-cell co-stimulator (ICOS), and programmed cell death protein 1 (PD-1)**
- **Consider FISH or MGPT in selected cases.[a]**
- **Assessment of human T-cell lymphotropic virus (HTLV)-1/2[i] by serology or other methods is encouraged as results can impact therapy.**

→ **Workup (MFSS-2)**

[a] Principles of Biomarker Testing in Cutaneous Lymphomas (PCLYM-B).
[b] Presence of LCT or areas of folliculotropism may have important implications for selection of therapy and outcome and should be included in pathology reports.
[c] Pimpinelli N, et al. J Am Acad Dermatol 2005;53:1053-1063.
[d] Use of Immunophenotyping/Genetic Testing in Differential Diagnosis of NK/T-Cell Neoplasms (see NCCN Guidelines for T-Cell Lymphomas).
[e] Typical immunophenotype: CD2+, CD3+, CD5+, CD7-, CD4+, CD8- (rarely CD8+), CD30-/+, cytotoxic granule proteins negative.
[f] Clonal *TRB* and *TRG* gene rearrangements alone are not sufficient for diagnosis, as these can also be seen in patients with non-malignant conditions. Results should be interpreted in the context of overall presentation. See Principles of Biomarker Testing in Cutaneous Lymphomas (PCLYM-B).
[g] TRBC1 may contribute in detecting clonality and can improve the specificity of detecting Sézary cells when CD7 and CD26 are lost.
[h] The loss of CCR4 expression and emergence of *CCR4* genomic alterations might be associated with resistance to mogamulizumab (Beygi S, et al. Blood 2022;139:3732-3736).
[i] See map for prevalence of HTLV-1/2 by geographic region. HTLV-1 has been described in patients in non-endemic areas.

Note: All recommendations are category 2A unless otherwise indicated.

Version 2.2026, 02/13/26 © 2026 National Comprehensive Cancer Network® (NCCN®), All rights reserved. NCCN Guidelines® and this illustration may not be reproduced in any form without the express written permission of NCCN.

PLEASE NOTE that use of this NCCN Content is governed by the End-User License Agreement, and you MAY NOT distribute this Content or use it with any artificial intelligence model or tool.
Printed by Galya Basol Kochav on 2/16/2026 9:44:21 AM. Copyright © 2026 National Comprehensive Cancer Network, Inc. All Rights Reserved.

WORKUP

ESSENTIAL:

- History and complete physical examination:
  - Complete skin examination: assessment of % body surface area (BSA) (palm plus all 5 digits ≈1% BSA) and type of skin lesion (ie, patch/plaque, tumor, erythroderma)
  - Palpation of peripheral LN regions
  - Palpation for organomegaly/masses
- Laboratory studies[j]:
  - CBC with differential and determination of absolute lymphocyte count
  - Flow cytometry to assess and quantitate an expanded T-cell population with aberrant phenotype (optional for T1[k]) (MFSS-3)
    - Recommended for any patient with T2–4 skin classification, any suspected extracutaneous disease including adenopathy
  - Clonal *TRB* and *TRG* gene rearrangement in peripheral blood lymphocytes if blood involvement suspected[a]
  - Comprehensive metabolic panel
  - LDH
- Imaging studies:
  - Integrated whole body FDG-PET/CT[l] (preferred) or C/A/P CT with contrast for ≥T2b or LCT or FMF, or with palpable adenopathy or abnormal laboratory studies; consider for T2a (patch disease with ≥10% BSA) or otherwise clinically indicated[m]
- Assess for distress[n]

USEFUL IN CERTAIN CIRCUMSTANCES:

- Bone marrow biopsy in patients with unexplained hematologic abnormality
- Biopsy of enlarged LN or suspected extracutaneous sites. Excisional or adequate core needle biopsy is preferred. A fine-needle aspiration (FNA) biopsy alone is insufficient for the initial diagnosis of lymphoma. Rebiopsy if pathologic findings are nondiagnostic and/or discordant with the clinical presentation.
- Rebiopsy skin if suspicious of LCT or FMF (not previously confirmed pathologically) or aggressive clinical behavior
- Neck CT with contrast if whole body FDG-PET/CT not done
- Pregnancy testing in patients of childbearing potential if contemplating treatments that are contraindicated in pregnancy[o]
- Discuss fertility preservation[p]

→ For TNMB Classification, see MFSS-3 and For Clinical Staging of MF and SS, see MFSS-4

[a] Principles of Biomarker Testing in Cutaneous Lymphomas (PCLYM-B).
[j] Sézary syndrome (B2) is as defined on MFSS-3.
[k] See Discussion for when Sézary flow cytometric study is appropriate in T1 disease.
[l] Patients with cutaneous lymphomas have extranodal disease, which may be inadequately imaged by CT. PET scan may be preferred in these instances.
[m] New significant adenopathy on clinical exam, abnormal laboratory results concerning of lymphoma, or accelerated skin disease.
[n] Refer to the NCCN Distress Thermometer and Problem List, which includes social determinants of health. See NCCN Guidelines for Distress Management (DIS-A).
[o] Many skin-directed and systemic therapies are contraindicated or of unknown safety in pregnancy. Refer to full prescribing information for individual drugs.
[p] Fertility preservation options include: sperm banking, IVF, or ovarian tissue or oocyte cryopreservation.

Note: All recommendations are category 2A unless otherwise indicated.

Version 2.2026, 02/13/26 © 2026 National Comprehensive Cancer Network® (NCCN®), All rights reserved. NCCN Guidelines® and this illustration may not be reproduced in any form without the express written permission of NCCN.

PLEASE NOTE that use of this NCCN Content is governed by the End-User License Agreement, and you MAY NOT distribute this Content or use it with any artificial intelligence model or tool.
Printed by Galya Basol Kochav on 2/16/2026 9:44:21 AM. Copyright © 2026 National Comprehensive Cancer Network, Inc. All Rights Reserved.

NCCN Guidelines Version 2.2026
Mycosis Fungoides/Sezary Syndrome

Changes or confirmation of staging are noted in bold in table below and in further description on MFSS-3A. Options for characterizing clonality further by designation as A (clone negative or equivocal) and B (clone positive and identical to skin) are presented. If a clone in LN or viscera is detected but different from that identified in the skin, another concurrent lymphoproliferative process should be considered.

TNMB			TNMB Classification and Staging of Mycosis Fungoides and Sézary Syndrome[q,r,s,t,u,v]		Clinical Staging of MF and SS (MFSS-4)
Skin (T)	T_0[w]		Absence of clinically suspicious lesions		
	T_1		Patches, plaques, or papules <10% BSA	T_{1A}	Patch only lesions
				T_{1B}	Plaque/papule ± patch lesions
	T_2		Patches, plaques, or papules ≥10% BSA	T_{2A}	Patch only
				T_{2B}	Plaque ± patch
	T_3		One or more tumors ≥1 cm in diameter		
	T_4		Confluence of erythema covering ≥80% BSA[u]		
Node (N)[x]	N_0		No clinically abnormal LN; no biopsy necessary		
	N_1	N_{1A}	Pathology Dutch grade 1 or NCI LN 0-2: clone negative **or equivocal**		Dutch Criteria for Lymph Nodes on MFSS-5
		N_{1B}	Pathology Dutch grade 1 or NCI LN 0-2: clone positive **and identical to skin**		NCI Lymph Node Classification on MFSS-5
	N_2	N_{2A}	Dutch grade 2, NCI LN3: clone negative **or equivocal**		
		N_{2B}	Dutch grade 2, NCI LN3: clone positive **and identical to skin**		
	N_3w	N_{3A}	Dutch grade 3-4, NCI LN4: clone negative or equivocal		
		N_{3B}	Dutch grade 3-4, NCI LN4: clone positive **and identical to skin**		
	N_X		Clinically abnormal peripheral or central lymph node but no pathologic determination of representative LN. **Other surrogate means of determining involvement may be determined by Tri-Society consensus**		
Visceral (M)	M_0		No visceral involvement		
	M_{1a}	**BM only involvement**	**Clone positive and identical to skin**		
			Clone negative or indeterminate		
	M_{1b}	**Non-BM visceral involvement**	**Clone positive and identical to skin**		
			Clone negative or indeterminate		
	M_X		Visceral involvement is neither confirmed nor refuted by available pathologic **or imaging assessment**		
Blood (B)[y]	B_0	B_{0A}	Clone negative **or equivocal**	Absence of significant blood involvement	
		B_{0B}	Clone positive **and identical to skin**		
	B_1	B_{1A}	Clone negative **or equivocal**	Low blood tumor burden	
		B_{1B}	Clone positive **and identical to skin**		
	B_2	B_{2A}	Clone negative **or equivocal**	High blood tumor burden	
		B_{2B}	Clone positive **and identical to skin**		
	B_X	**B_{XA}**	Clone negative **or equivocal**	**Unable to quantify blood involvement according to agreed upon guidelines**	
		B_{XB}	Clone positive **and identical to skin**		

Note: All recommendations are category 2A unless otherwise indicated.

Footnotes on MFSS-3A

Version 2.2026, 02/13/26 © 2026 National Comprehensive Cancer Network® (NCCN®), All rights reserved. NCCN Guidelines® and this illustration may not be reproduced in any form without the express written permission of NCCN.

PLEASE NOTE that use of this NCCN Content is governed by the End-User License Agreement, and you MAY NOT distribute this Content or use it with any artificial intelligence model or tool.
Printed by Galya Basol Kochav on 2/16/2026 9:44:21 AM. Copyright © 2026 National Comprehensive Cancer Network, Inc. All Rights Reserved.

FOOTNOTES

[q] This work was originally published in Blood. Olsen EA, Whittaker S, Willemze R, et al. Primary cutaneous lymphoma: recommendations for clinical trial design and staging update from the ISCL, USCLC, and EORTC. Blood 2022;140:419-437. © The American Society of Hematology.

[r] Sézary syndrome is defined by B2 blood involvement and a clonal rearrangement of *TCR* in the blood (clones should be relevant to clone in the skin).

[s] Patch = Any size skin lesion without significant elevation or induration. Presence/absence of hypo- or hyperpigmentation, scale, crusting, and/or poikiloderma should be noted.

[t] Plaque = Any size skin lesion that is elevated or indurated. Presence or absence of scale, crusting, and/or poikiloderma should be noted. Histologic features such as folliculotropism or LCT (≥25% large cells), CD30+ or CD30-, and clinical features such as ulceration are important to document.

[u] Tumor = at least one ≥1 cm diameter solid or nodular lesion with evidence of depth and/or vertical growth. Note total number of lesions, total volume of lesions, largest size lesion, and region of body involved. Also note if histologic evidence of LCT has occurred. Phenotyping for CD30 is encouraged.

[v] Patients with both erythroderma and tumors may be designated as $T_4(T_3)$. The BSA of 80% is used to define erythroderma in MF/SS at study entry, but any decrease in BSA during the study does not affect the entry classification.

[w] T_0 is used for clinical trials in order to track clearance of lesions in the skin compartment. No patient with cutaneous lymphoma at time of diagnosis should be T_0.

[x] Abnormal LNs are those now >1.5 cm longest diameter (LDi) according to the Lugano classification and confirmed by imaging. The pathological findings of a representative abnormal LN may apply to all abnormal LNs.

[y] Blood staging for MF/SS is defined currently as B_0 = 250/μL of CD4+/CD26- or CD4+/CD7- cells, B_1 = does not meet criteria for B_0 or B_2, and B_2 = ≥1000/μL of CD4+/CD26- or CD4+/CD7- cells or other aberrant population of lymphocytes identified by flow cytometry. It is expected that patients with high blood tumor burden (B_2) will have a clone in the blood that is identical to that in the skin. Nonidentical T-cell clones are often detected in peripheral blood with increasing age and are of unknown clinical significance. Patients with lymphopenia (defined as <1000 absolute lymphocytes) may potentially have an underestimation of aberrant lymphocyte burden if assessed only by the absolute number and not also by the percentage of immunophenotypically abnormal lymphocytes.

Note: All recommendations are category 2A unless otherwise indicated.

Version 2.2026, 02/13/26 © 2026 National Comprehensive Cancer Network® (NCCN®), All rights reserved. NCCN Guidelines® and this illustration may not be reproduced in any form without the express written permission of NCCN.

PLEASE NOTE that use of this NCCN Content is governed by the End-User License Agreement, and you MAY NOT distribute this Content or use it with any artificial intelligence model or tool.
Printed by Galya Basol Kochav on 2/16/2026 9:44:21 AM. Copyright © 2026 National Comprehensive Cancer Network, Inc. All Rights Reserved.

CLINICAL STAGING OF MF AND SS[z]

Clinical Stage[aa]	T (Skin)	N (Node)	M (Visceral)	B (Blood Involvement)	Guidelines Page
IA (Limited skin involvement)	T1 (Patches, papules, and/or plaques covering <10% body surface area [BSA])	N0	M0	B0 or B1	MFSS-6
IB (Skin-only disease)	T2 (Patches, papules, and/or plaques covering ≥10% BSA)	N0	M0	B0 or B1	MFSS-7
IIA	T1–2	N1–2	M0	B0 or B1	MFSS-7
IIB (Tumor stage disease)	T3 (One or more tumors [≥1 cm in diameter])	N0–2	M0	B0 or B1	MFSS-8
IIIA (Erythrodermic disease)	T4 (Confluence of erythema ≥80% BSA)	N0–2	M0	B0	MFSS-10
IIIB (Erythrodermic disease)	T4 (Confluence of erythema ≥80% BSA)	N0–2	M0	B1	MFSS-10
IVA_1 (Sézary syndrome)	T1–4	N0–2	M0	B2	MFSS-11
IVA_2 (Sézary syndrome or Non-Sézary)	T1–4	N3	M0	B0 or B1 or B2	MFSS-11
IVB (Visceral disease)	T1–4	N0–3	M1A or M1B	B0 or B1 or B2	MFSS-11
	Large-cell transformation (LCT)[bb]				MFSS-12

[z] Olsen EA, et al. Blood 2022;140:419-437.
[aa] Folliculotropism is a histologic feature that can occur irrespective of stage. Histologic evidence of FMF is associated with higher risk of disease progression. In selected cases or inadequate response, consider primary treatment for stage IIB (tumor stage disease).
[bb] LCT is a histologic feature that can occur irrespective of clinical stage. LCT often but not always corresponds to a more aggressive growth rate requiring systemic therapies.

TNMB Classification on MFSS-3

Note: All recommendations are category 2A unless otherwise indicated.

Version 2.2026, 02/13/26 © 2026 National Comprehensive Cancer Network® (NCCN®), All rights reserved. NCCN Guidelines® and this illustration may not be reproduced in any form without the express written permission of NCCN.

PLEASE NOTE that use of this NCCN Content is governed by the End-User License Agreement, and you MAY NOT distribute this Content or use it with any artificial intelligence model or tool.
Printed by Galya Basol Kochav on 2/16/2026 9:44:21 AM. Copyright © 2026 National Comprehensive Cancer Network, Inc. All Rights Reserved.

LYMPH NODE (LN) CLASSIFICATION IN MF AND SS

NCI-VA Lymph Node Classification

LN0: no atypical lymphocytes
LN1: occasional and isolated atypical lymphocytes (not arranged in clusters)
LN2: many atypical lymphocytes or in 3–6 cell clusters
LN3: aggregates of atypical lymphocytes; nodal architecture preserved
LN4: partial/complete effacement of nodal architecture by atypical lymphocytes or frankly neoplastic cells

Clendenning WE, Rappaport HW. Report of the Committee on Pathology of Cutaneous T Cell Lymphomas. Cancer Treat Rep 1979;63:719-724.

Dutch Criteria for Lymph Nodes

Grade 1: Dermatopathic lymphadenopathy
Grade 2: Early involvement by mycosis fungoides (presence of cerebriform nuclei >7.5 micrometers)
Grade 3: Partial effacement of lymph node architecture; many atypical cerebriform mononuclear cells
Grade 4: Complete effacement of lymph node architecture

Scheffer E, Meijer CJLM, van Vloten WA. Dermatopathic lymphadenopathy and lymph node involvement in mycosis fungoides. Cancer 1980;45:137-148.

Note: All recommendations are category 2A unless otherwise indicated.

Version 2.2026, 02/13/26 © 2026 National Comprehensive Cancer Network® (NCCN®), All rights reserved. NCCN Guidelines® and this illustration may not be reproduced in any form without the express written permission of NCCN.

PLEASE NOTE that use of this NCCN Content is governed by the End-User License Agreement, and you MAY NOT distribute this Content or use it with any artificial intelligence model or tool.
Printed by Galya Basol Kochav on 2/16/2026 9:44:21 AM. Copyright © 2026 National Comprehensive Cancer Network, Inc. All Rights Reserved.

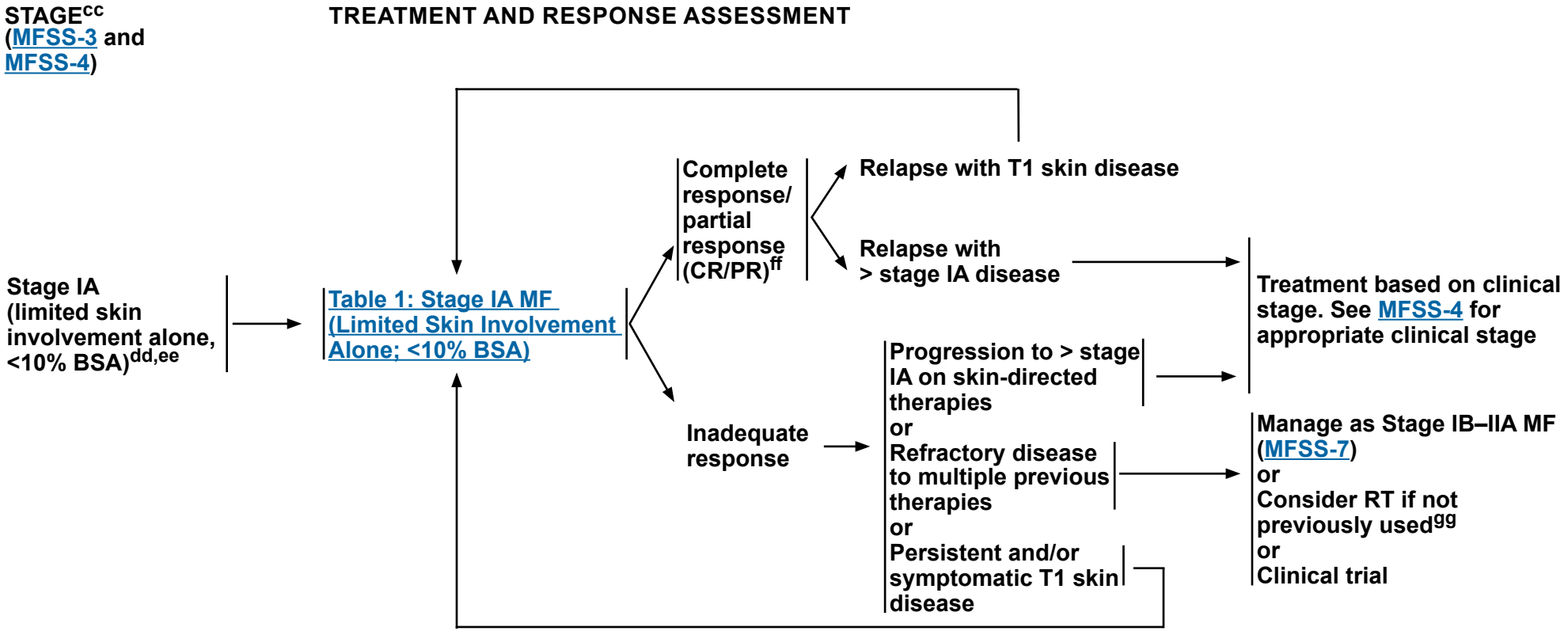

[cc] Principles for Mycosis Fungoides/Sézary Syndrome (MFSS/INTRO-1) and General Considerations for the Treatment of Patients with MF and SS (MFSS-A 1 of 12).
[dd] In rare cases of confirmed unilesional MF, RT has been shown to provide long-term remission.
[ee] Rebiopsy if LCT is suspected; if histologic evidence of LCT, see MFSS-12.
[ff] Patients with disease achieving a clinical benefit and/or those with disease responding to primary treatment should be considered for maintenance or tapering of regimens to optimize response duration.
[gg] Principles of Radiation Therapy (PCLYM-A).

Note: All recommendations are category 2A unless otherwise indicated.

Version 2.2026, 02/13/26 © 2026 National Comprehensive Cancer Network® (NCCN®), All rights reserved. NCCN Guidelines® and this illustration may not be reproduced in any form without the express written permission of NCCN.

PLEASE NOTE that use of this NCCN Content is governed by the End-User License Agreement, and you MAY NOT distribute this Content or use it with any artificial intelligence model or tool.
Printed by Galya Basol Kochav on 2/16/2026 9:44:21 AM. Copyright © 2026 National Comprehensive Cancer Network, Inc. All Rights Reserved.

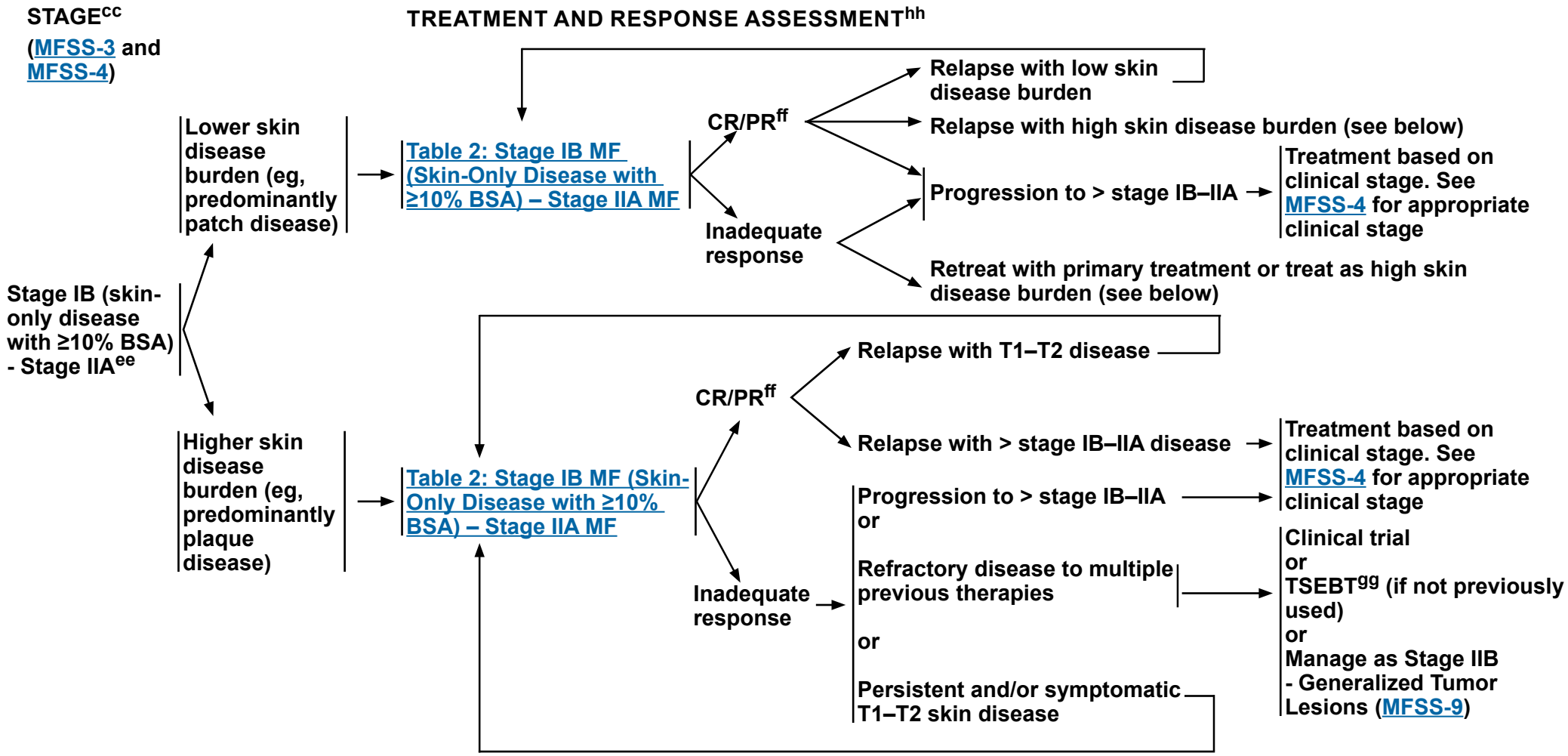

[cc] Principles for Mycosis Fungoides/Sézary Syndrome (MFSS/INTRO-1) and General Considerations for the Treatment of Patients with MF and SS (MFSS-A 1 of 12).
[ee] Rebiopsy if LCT is suspected; if histologic evidence of LCT, see MFSS-12.
[ff] Patients with disease achieving a clinical benefit and/or those with disease responding to primary treatment should be considered for maintenance or tapering of regimens to optimize response duration.
[gg] Principles of Radiation Therapy (PCLYM-A).
[hh] Imaging (with modalities used in workup) indicated when suspicious of clinical extracutaneous disease.

Note: All recommendations are category 2A unless otherwise indicated.

Version 2.2026, 02/13/26 © 2026 National Comprehensive Cancer Network® (NCCN®), All rights reserved. NCCN Guidelines® and this illustration may not be reproduced in any form without the express written permission of NCCN.

PLEASE NOTE that use of this NCCN Content is governed by the End-User License Agreement, and you MAY NOT distribute this Content or use it with any artificial intelligence model or tool.
Printed by Galya Basol Kochav on 2/16/2026 9:44:21 AM. Copyright © 2026 National Comprehensive Cancer Network, Inc. All Rights Reserved.

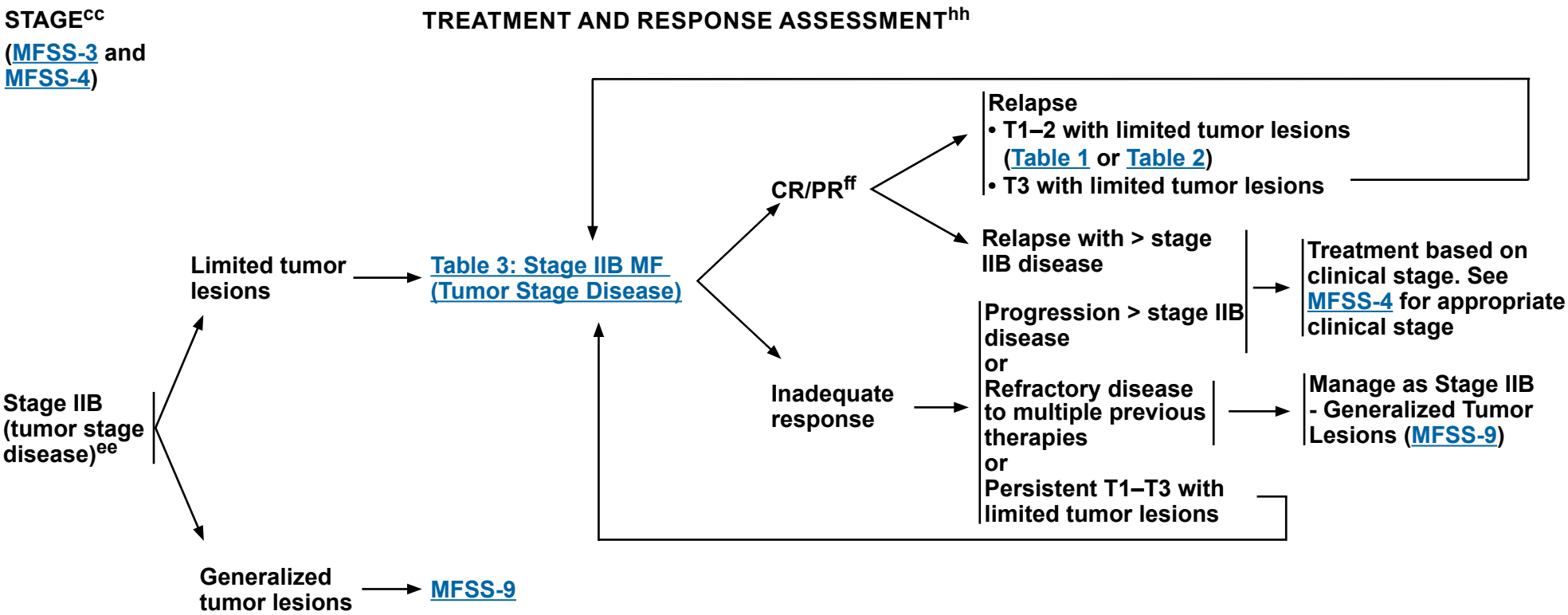

[cc] Principles for Mycosis Fungoides/Sézary Syndrome (MFSS/INTRO-1) and General Considerations for the Treatment of Patients with MF and SS (MFSS-A 1 of 12).
[ee] Rebiopsy if LCT is suspected; if histologic evidence of LCT, see MFSS-12.
[ff] Patients with disease achieving a clinical benefit and/or those with disease responding to primary treatment should be considered for maintenance or tapering of regimens to optimize response duration.
[hh] Imaging (with modalities used in workup) indicated when suspicious of clinical extracutaneous disease.

Note: All recommendations are category 2A unless otherwise indicated.

Version 2.2026, 02/13/26 © 2026 National Comprehensive Cancer Network® (NCCN®), All rights reserved. NCCN Guidelines® and this illustration may not be reproduced in any form without the express written permission of NCCN.

PLEASE NOTE that use of this NCCN Content is governed by the End-User License Agreement, and you MAY NOT distribute this Content or use it with any artificial intelligence model or tool.
Printed by Galya Basol Kochav on 2/16/2026 9:44:21 AM. Copyright © 2026 National Comprehensive Cancer Network, Inc. All Rights Reserved.

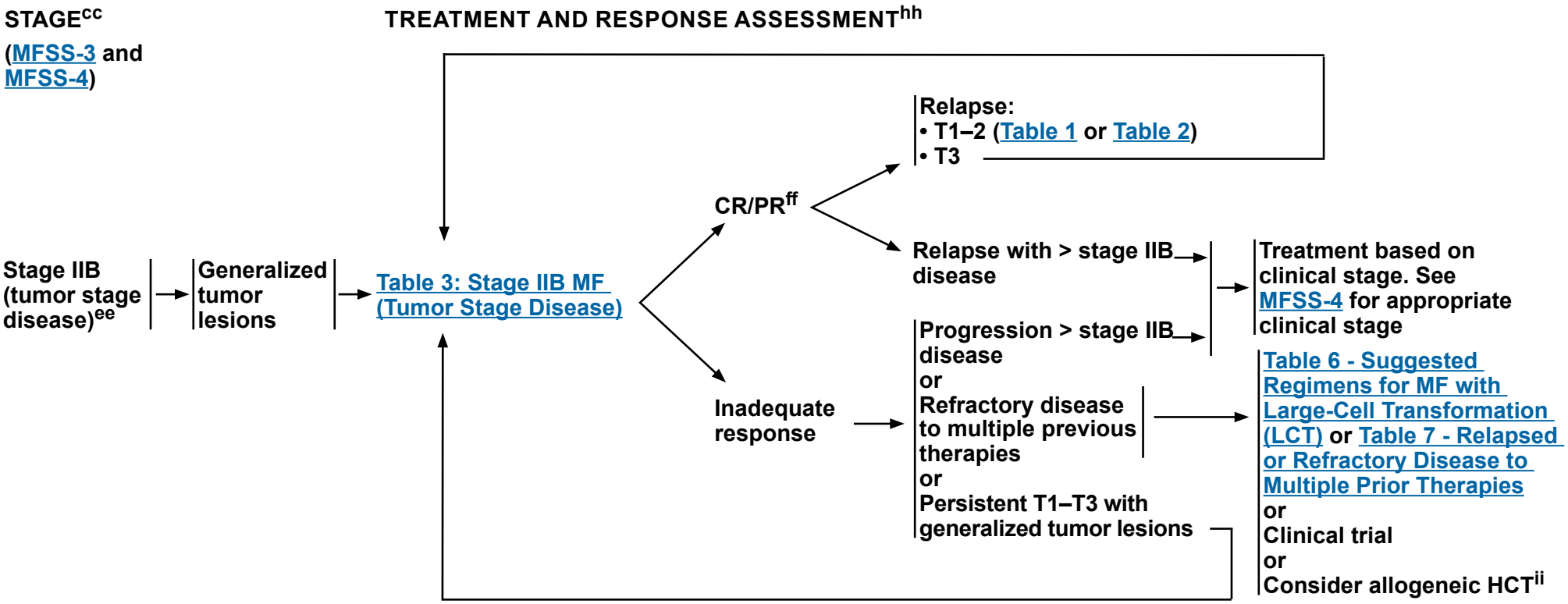

[cc] Principles for Mycosis Fungoides/Sézary Syndrome (MFSS/INTRO-1) and General Considerations for the Treatment of Patients with MF and SS (MFSS-A 1 of 12).
[ee] Rebiopsy if LCT is suspected, if histologic evidence of LCT, see MFSS-12.
[ff] Patients with disease achieving a clinical benefit and/or those with disease responding to primary treatment should be considered for maintenance or tapering of regimens to optimize response duration.
[hh] Imaging (with modalities used in workup) indicated when suspicious of clinical extracutaneous disease.
[ii] Allogeneic HCT is associated with better outcomes in patients with disease responding to primary treatment prior to transplant. See Discussion for further details.

Note: All recommendations are category 2A unless otherwise indicated.

Version 2.2026, 02/13/26 © 2026 National Comprehensive Cancer Network® (NCCN®), All rights reserved. NCCN Guidelines® and this illustration may not be reproduced in any form without the express written permission of NCCN.

PLEASE NOTE that use of this NCCN Content is governed by the End-User License Agreement, and you MAY NOT distribute this Content or use it with any artificial intelligence model or tool.
Printed by Galya Basol Kochav on 2/16/2026 9:44:21 AM. Copyright © 2026 National Comprehensive Cancer Network, Inc. All Rights Reserved.

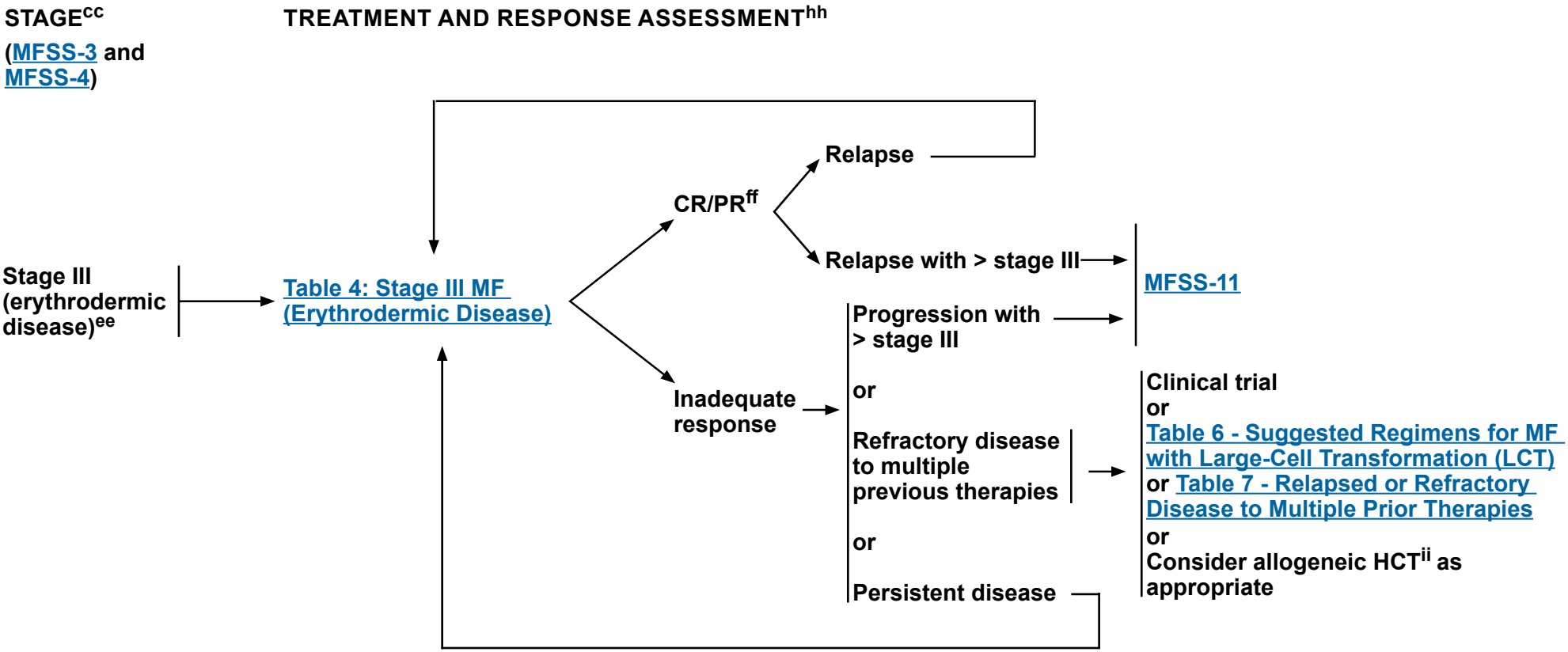

[cc] Principles for Mycosis Fungoides/Sézary Syndrome (MFSS/INTRO-1) and General Considerations for the Treatment of Patients with MF and SS (MFSS-A 1 of 12).
[ee] Rebiopsy if LCT is suspected; if histologic evidence of LCT, see MFSS-12.
[ff] Patients with disease achieving a clinical benefit and/or those with disease responding to primary treatment should be considered for maintenance or tapering of regimens to optimize response duration.
[hh] Imaging (with modalities used in workup) indicated when suspicious of clinical extracutaneous disease.
[ii] Allogeneic HCT is associated with better outcomes in patients with disease responding to primary treatment prior to transplant. See Discussion for further details.

Note: All recommendations are category 2A unless otherwise indicated.

Version 2.2026, 02/13/26 © 2026 National Comprehensive Cancer Network® (NCCN®), All rights reserved. NCCN Guidelines® and this illustration may not be reproduced in any form without the express written permission of NCCN.

PLEASE NOTE that use of this NCCN Content is governed by the End-User License Agreement, and you MAY NOT distribute this Content or use it with any artificial intelligence model or tool.
Printed by Galya Basol Kochav on 2/16/2026 9:44:21 AM. Copyright © 2026 National Comprehensive Cancer Network, Inc. All Rights Reserved.

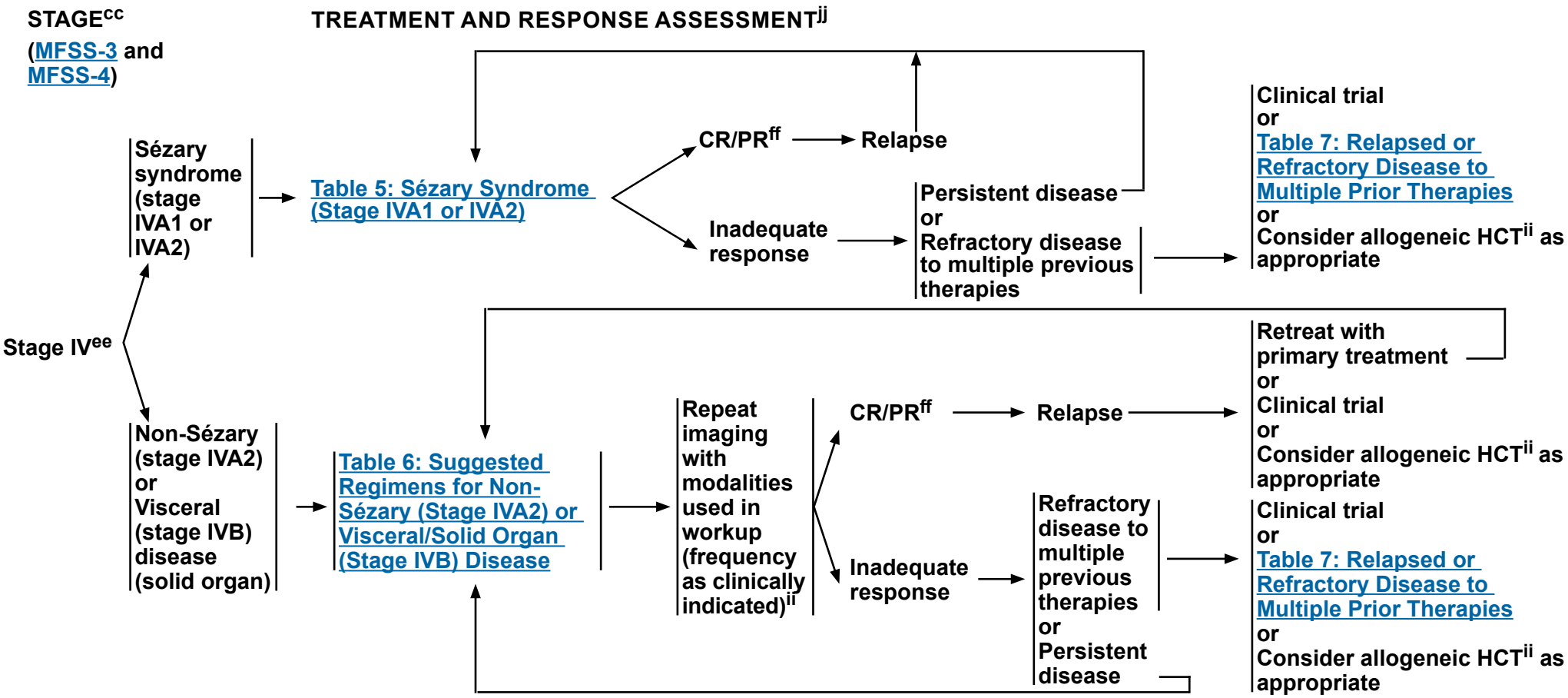

[cc] Principles for Mycosis Fungoides/Sézary Syndrome (MFSS/INTRO-1) and General Considerations for the Treatment of Patients with MF and SS (MFSS-A 1 of 12).

[ee] Rebiopsy if LCT is suspected; if histologic evidence of LCT, see MFSS-12.

[ff] Patients with disease achieving a clinical benefit and/or those with disease responding to primary treatment should be considered for maintenance or tapering of regimens to optimize response duration.

[ii] Allogeneic HCT is associated with better outcomes in patients with disease responding to primary treatment prior to transplant. See Discussion for further details.

[jj] If disease in LNs and/or viscera or suspicious of disease progression, imaging (with modalities used in workup) as clinically indicated based on distribution of disease.

Note: All recommendations are category 2A unless otherwise indicated.

Version 2.2026, 02/13/26 © 2026 National Comprehensive Cancer Network® (NCCN®), All rights reserved. NCCN Guidelines® and this illustration may not be reproduced in any form without the express written permission of NCCN.

PLEASE NOTE that use of this NCCN Content is governed by the End-User License Agreement, and you MAY NOT distribute this Content or use it with any artificial intelligence model or tool.
Printed by Galya Basol Kochav on 2/16/2026 9:44:21 AM. Copyright © 2026 National Comprehensive Cancer Network, Inc. All Rights Reserved.

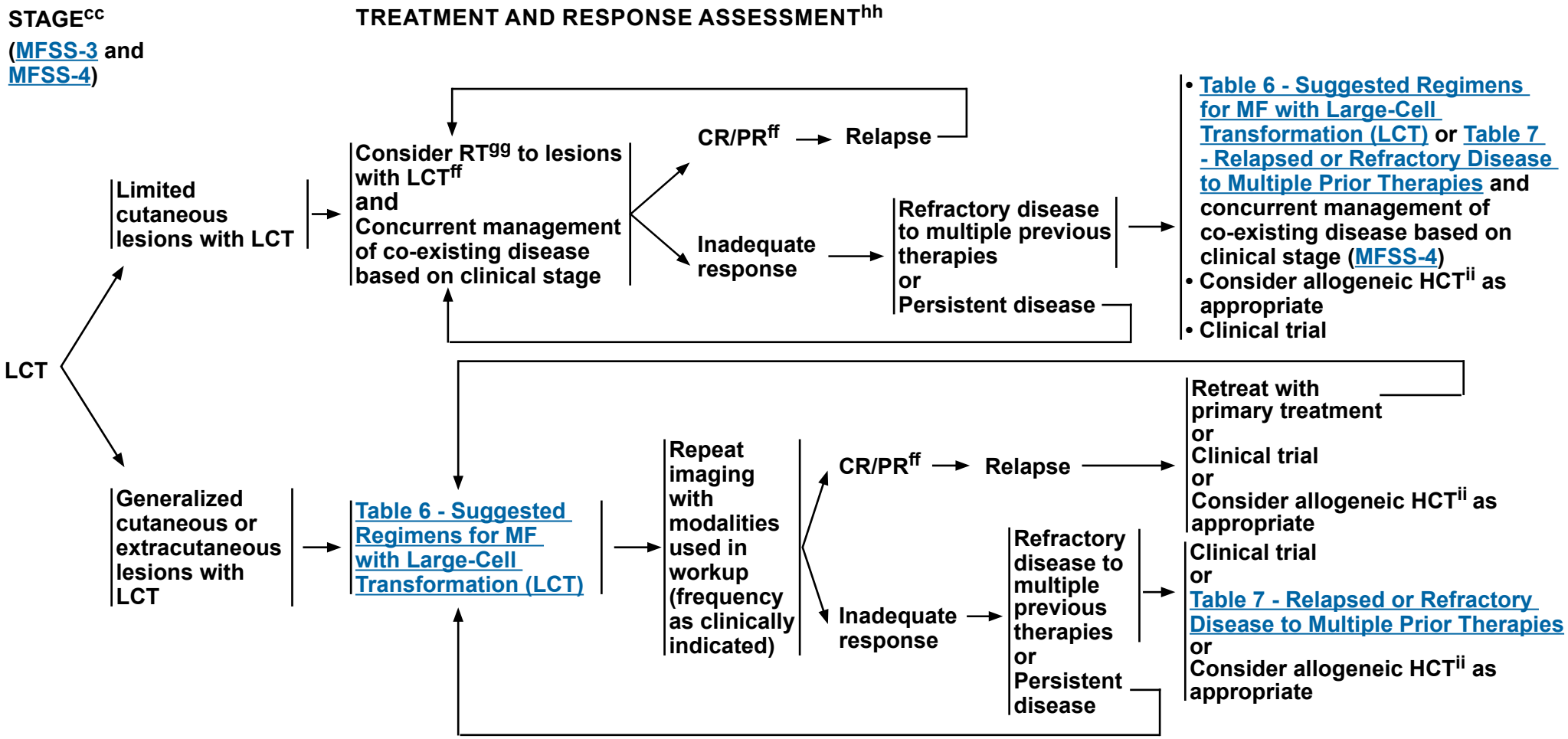

[cc] Principles for Mycosis Fungoides/Sézary Syndrome (MFSS/INTRO-1) and General Considerations for the Treatment of Patients with MF and SS (MFSS-A 1 of 12).
[ff] Patients with disease achieving a clinical benefit and/or those with disease responding to primary treatment should be considered for maintenance or tapering of regimens to optimize response duration.
[gg] Principles of Radiation Therapy (PCLYM-A).
[hh] Imaging (with modalities used in workup) indicated when suspicious of clinical extracutaneous disease.
[ii] Allogeneic HCT is associated with better outcomes in patients with disease responding to primary treatment prior to transplant. See Discussion for further details.

Note: All recommendations are category 2A unless otherwise indicated.

Version 2.2026, 02/13/26 © 2026 National Comprehensive Cancer Network® (NCCN®), All rights reserved. NCCN Guidelines® and this illustration may not be reproduced in any form without the express written permission of NCCN.

PLEASE NOTE that use of this NCCN Content is governed by the End-User License Agreement, and you MAY NOT distribute this Content or use it with any artificial intelligence model or tool.
Printed by Galya Basol Kochav on 2/16/2026 9:44:21 AM. Copyright © 2026 National Comprehensive Cancer Network, Inc. All Rights Reserved.

GENERAL CONSIDERATIONS FOR THE TREATMENT OF PATIENTS WITH MF AND SS

- **Generally, skin-directed therapies and systemic therapy regimens that can often be tolerated for longer durations of therapy with lower rates of cumulative toxicity, less immunosuppression, and/or higher efficacy are used in earlier lines of therapy before moving on to treatment options that carry a higher risk of cumulative toxicity and/or immunosuppression.**
- **Therapies with lower side effect profiles and an absence of cumulative toxicity are often given in an ongoing or maintenance fashion to improve and maintain disease control and quality of life.**
- **Systemic therapy is often combined with skin-directed therapy to maximize clinical responses in the skin compartment and to provide additive efficacy without cumulative toxicities.**
- **Bexarotene, brentuximab vedotin, denileukin diftitox-cxdl, mogamulizumab, romidepsin, and vorinostat are approved by the U.S. Food and Drug Administration (FDA) for the treatment of MF and SS. Other systemic therapies such as interferons (alfa and gamma), methotrexate, and other retinoids (acitretin and isotretinoin) also offer clinical benefit but have only been evaluated in small studies.**
- **The optimal treatment for any patient at any given time is often individualized based on symptoms of disease, route of administration, toxicities, and overall goals of therapy.**
- **Use of supportive care measures to minimize risk of skin infections and treat pruritus is an important part of disease and symptom control (MFSS-B).**

Note: All recommendations are category 2A unless otherwise indicated.

Version 2.2026, 02/13/26 © 2026 National Comprehensive Cancer Network® (NCCN®), All rights reserved. NCCN Guidelines® and this illustration may not be reproduced in any form without the express written permission of NCCN.

PLEASE NOTE that use of this NCCN Content is governed by the End-User License Agreement, and you MAY NOT distribute this Content or use it with any artificial intelligence model or tool.
Printed by Galya Basol Kochav on 2/16/2026 9:44:21 AM. Copyright © 2026 National Comprehensive Cancer Network, Inc. All Rights Reserved.

SUGGESTED REGIMENS: SKIN-DIRECTED THERAPIES

SKIN-LIMITED/LOCAL (FOR LIMITED/LOCALIZED SKIN INVOLVEMENT)	TREATMENT CONSIDERATIONS
• Local radiation (involved-site RT [ISRT]) ▸ 8–12 Gy; 24–30 Gy for unilesional presentation • Phototherapy (See MFSS-C) ▸ UVB or narrowband UVB (NB-UVB) • Topical corticosteroids • Topical Imiquimod • Topical Mechlorethamine (nitrogen mustard) • Topical retinoids (Bexarotene, Tazarotene) • Topical Carmustine (category 2B) Useful in Certain Circumstances • Topical calcineurin inhibitors (Pimecrolimus, Tacrolimus)	1. Skin-directed therapies can be used alone or in combination with other skin-directed therapies. 2. Cumulative dose of UV, in particular PUVA, which carries a higher risk than NB-UVB, is associated with increased risk of UV-associated skin neoplasms; thus, phototherapy use should be balanced against these risks in patients with a history of extensive squamoproliferative skin neoplasms or basal cell carcinomas or who have had melanoma. 3. TSEBT, and in certain cases PUVA or UVA1 may be considered for widespread thicker plaques or tumors. 4. Low-dose local RT (8–12 Gy) is given with palliative intent (usually as combined modality therapy). Some Member Institutions are exploring the use of lower dose options (eg, 4 Gy). Up to 8 Gy can be given in a single fraction, although lower dose per fraction (3–5 Gy) may be preferred depending on skin condition, irradiation volume, and prior RT. For rare initial unilesional presentations, RT (24–30 Gy) is given as monotherapy with curative intent. 5. Optimal use of topical steroids is often dependent on lesion type and location of disease. This is best done in consultation with a dermatologist or physician with experience in the use of topical steroids. In general, high-potency steroids may be less well-tolerated intertriginous body areas or other areas such as the face. Potency of steroid and extent/duration of skin treated can result in systemic absorption and/or skin atrophy. 6. Topical imiquimod can be considered (often in consultation with a dermatologist or physician with experience in its safety and use) for areas with few patches/plaques/small tumors that are recalcitrant to treatment or on sun-damaged skin such as forearms, scalp, and face. 7. Topical mechlorethamine has no significant systemic absorption, and can be used alone or in combination with other skin-directed therapies, in particular topical steroids. Topical mechlorethamine use, in particular gel preparation, can be complicated by dermatitis, and can result in skin irritation when used on face and intertriginous body areas. Initiating at less than daily use can be useful to determine tolerability and topical steroids can be considered as needed to alleviate skin reactions from topical mechlorethamine gel. If used with phototherapy, topical mechlorethamine gel should be applied after exposure to UV light. 8. Topical retinoids can cause skin irritation including redness, peeling, and dermatitis when used on face and intertriginous body areas. 9. Topical calcineurin inhibitors can be considered for affected areas of facial and genital skin and of skin folds as a steroid-sparing treatment. Further efficacy and safety data on long-term use are needed. 10. It is common practice to follow TSEBT with systemic therapies to maintain response. There are limited safety data for the use of TSEBT in combination with systemic retinoids, HDAC inhibitors (such as vorinostat or romidepsin), or mogamulizumab, or combining phototherapy with vorinostat or romidepsin.
SKIN-GENERALIZED (FOR GENERALIZED SKIN INVOLVEMENT)	
• Phototherapy (See MFSS-C) ▸ UVB or NB-UVB ▸ PUVA ▸ UVA1 (if available) • Topical corticosteroids • Topical Mechlorethamine (nitrogen mustard) • Total skin electron beam therapy (TSEBT) (12–36 Gy)	

Note: All recommendations are category 2A unless otherwise indicated.

Version 2.2026, 02/13/26 © 2026 National Comprehensive Cancer Network® (NCCN®), All rights reserved. NCCN Guidelines® and this illustration may not be reproduced in any form without the express written permission of NCCN.

PLEASE NOTE that use of this NCCN Content is governed by the End-User License Agreement, and you MAY NOT distribute this Content or use it with any artificial intelligence model or tool.
Printed by Galya Basol Kochav on 2/16/2026 9:44:21 AM. Copyright © 2026 National Comprehensive Cancer Network, Inc. All Rights Reserved.

TABLE 1: STAGE IA MF (Limited Skin Involvement Alone; <10% BSA) - MFSS-6[a,b]

SUGGESTED REGIMENS	TREATMENT CONSIDERATIONS (SEE ALSO GENERAL CONSIDERATIONS ON MFSS-A [1 of 12])
• Skin-directed therapies (alone or in combination with other skin-directed therapies) [Skin-Limited/Local (for Limited/Localized Skin Involvement, MFSS-A 2 of 12)] OR • Skin-directed therapy (Skin-Limited/Local) in combination with systemic therapy (in selected cases) Preferred (alphabetical order) • Systemic therapy + skin-directed therapy (limited/local or generalized including phototherapy as indicated for stage of disease) ▸ Bexarotene ▸ Interferon alfa[b] ▸ Methotrexate Useful in Certain Circumstances (alphabetical order) • Systemic therapy + skin-directed therapy (limited/local or generalized including phototherapy as indicated for stage of disease) ▸ Acitretin ▸ Extracorporeal photopheresis (ECP) ▸ Interferon gamma-1b ▸ Isotretinoin	1. Stage IA MF most often can be treated with skin-directed therapies (alone or in combination with other skin-directed therapies). 2. In patients with histologic evidence of FMF, skin disease may be less responsive to topical therapies. 3. Systemic therapies (single agents or combination therapies) should be reserved for patients with blood involvement or for whom skin-directed therapies do not provide sufficient disease control or who have disease that is not amenable to skin-directed therapy (eg, in regions where topical therapies are difficult to apply regularly). 4. Alternative retinoids (acitretin or isotretinoin) could be considered in place of bexarotene. 5. In stage IA, ECP is primarily reserved for the rare patient with stage IA MF with low-level blood involvement (B1). 6. Patients with disease achieving a clinical benefit and/or those with disease responding to primary treatment should be considered for maintenance or tapering of regimens to optimize response duration.

Footnotes on MFSS-A 9 of 12

Note: All recommendations are category 2A unless otherwise indicated.

Version 2.2026, 02/13/26 © 2026 National Comprehensive Cancer Network® (NCCN®), All rights reserved. NCCN Guidelines® and this illustration may not be reproduced in any form without the express written permission of NCCN.

PLEASE NOTE that use of this NCCN Content is governed by the End-User License Agreement, and you MAY NOT distribute this Content or use it with any artificial intelligence model or tool.
Printed by Galya Basol Kochav on 2/16/2026 9:44:21 AM. Copyright © 2026 National Comprehensive Cancer Network, Inc. All Rights Reserved.

TABLE 2: STAGE IB MF (Skin-Only Disease With ≥10% BSA) – STAGE IIA MF - MFSS-7[a,b,c]

SUGGESTED REGIMENS	TREATMENT CONSIDERATIONS (SEE ALSO GENERAL CONSIDERATIONS ON MFSS-A [1 of 12])
• Skin-directed therapies (alone or in combination with other skin-directed therapies) ▸ Lower skin disease burden (eg, predominantly patch disease): Skin-Limited/Local (for Limited/Localized Skin Involvement) ▸ Higher skin disease burden (eg, predominantly plaque disease): Skin-Generalized (for Generalized Skin Involvement) OR • Systemic therapy + skin-directed therapy (limited/local or generalized including phototherapy as indicated for stage of disease) Preferred (alphabetical order) • Bexarotene • Brentuximab vedotin • Interferon alfa[b] • Methotrexate • Mogamulizumab • Romidepsin • Vorinostat Useful in Certain Circumstances (alphabetical order by category) • Acitretin • Denileukin diftitox-cxdl[d] • ECP • Interferon gamma-1b • Isotretinoin • Alemtuzumab (category 2B) • Gemcitabine (category 2B) • Liposomal Doxorubicin (category 2B) • Pembrolizumab (category 2B) • Pralatrexate (category 2B)	1. Stage IB–IIA MF can be treated with skin-directed therapies (alone or in combination with other skin-directed therapies). ***Limited patches/plaques:*** Skin-directed therapy can be considered as monotherapy. ***Extensive skin involvement:*** Phototherapy may be given alone or in combination with other skin-directed therapies. TSEBT maybe given alone or in combination with topical corticosteroids. 2. In patients with histologic evidence of FMF, skin disease may be less responsive to topical therapies. 3. Systemic therapies (single agents or combination therapies) should be considered for patients with extensive skin involvement, higher skin disease burden, predominantly plaque disease, blood involvement, and/or inadequate response to skin-directed therapy. 4. In the randomized ALCANZA trial (Prince HM, et al. Lancet 2017;390:555-566), brentuximab vedotin was more effective than methotrexate or bexarotene in patients with previously treated MF (≥ stage IB). Patients with SS were excluded from the ALCANZA trial. 5. In the randomized MAVORIC trial (Kim YH, et al. Lancet Oncol 2018;19:1192-1204), mogamulizumab was more effective than vorinostat in patients with previously treated MF (≥ stage IB) and SS. Responses were higher in patients with blood involvement (stage III or stage IV disease) than those with stage IIB or stage IB/IIA disease. Patients with MF-LCT were excluded from the MAVORIC trial. 6. Alternative retinoids (acitretin or isotretinoin) could be considered in place of bexarotene. 7. In stage IB/IIA, ECP is primarily reserved for patients with low-level blood involvement (B1). 8. There are limited safety data for the use of TSEBT in combination with systemic retinoids, HDAC inhibitors (such as vorinostat or romidepsin), or mogamulizumab, or combining phototherapy with vorinostat or romidepsin. 9. Patients with disease achieving a clinical benefit and/or those with disease responding to treatment should be considered for maintenance or tapering of regimens to optimize response duration. 10. LCT-MF was not an exclusion criteria for Study 302, which evaluated a reformulated version of denileukin diftitox, but no patients with LCT-MF were enrolled in the study.

Note: All recommendations are category 2A unless otherwise indicated.

Footnotes on MFSS-A 9 of 12

Version 2.2026, 02/13/26 © 2026 National Comprehensive Cancer Network® (NCCN®), All rights reserved. NCCN Guidelines® and this illustration may not be reproduced in any form without the express written permission of NCCN.

PLEASE NOTE that use of this NCCN Content is governed by the End-User License Agreement, and you MAY NOT distribute this Content or use it with any artificial intelligence model or tool.
Printed by Galya Basol Kochav on 2/16/2026 9:44:21 AM. Copyright © 2026 National Comprehensive Cancer Network, Inc. All Rights Reserved.

TABLE 3: STAGE IIB MF (Tumor Stage Disease)[a,b,c]

LIMITED TUMOR DISEASE	GENERALIZED TUMOR DISEASE	TREATMENT CONSIDERATIONS (SEE ALSO GENERAL CONSIDERATIONS ON MFSS-A [1 of 12])
• Local RT and/or skin-directed therapy OR • Systemic therapy ± local RT ± skin-directed therapy (limited/ local or generalized including phototherapy as indicated for stage of disease) Preferred (alphabetical order) • Bexarotene • Brentuximab vedotin • Interferon alfa[b] • Methotrexate • Mogamulizumab • Romidepsin Other Recommended • Vorinostat • Pembrolizumab (category 2B) Useful in Certain Circumstances (alphabetical order) • Acitretin • Denileukin diftitox-cxdl[d] • ECP • Interferon gamma-1b • Isotretinoin	• TSEBT OR • Systemic therapy + skin-directed therapy (limited/ local or generalized including phototherapy as indicated for stage of disease) OR • Combination therapies Preferred (alphabetical order) • Single agents ▸ Bexarotene ▸ Brentuximab vedotin ▸ Denileukin diftitox-cxdl[d] ▸ Gemcitabine ▸ Interferon alfa[b] ▸ Liposomal Doxorubicin ▸ Methotrexate ▸ Mogamulizumab ▸ Pralatrexate ▸ Romidepsin • Combination therapy ▸ Retinoid + Interferon alfa[b] Other Recommended • Pembrolizumab • Vorinostat Useful in Certain Circumstances (alphabetical order) • Single agents ▸ Acitretin ▸ ECP ▸ Interferon gamma-1b ▸ Isotretinoin • Combination therapy ▸ ECP + Interferon alfa[b] or retinoid ▸ ECP + Interferon alfa[b] + retinoid	1. RT is preferred for limited tumor lesions. Topical therapies alone are often inadequate for tumor stage disease. 2. In patients with histologic evidence of FMF, skin disease may be less responsive to topical therapies. 3. Adjuvant systemic biologic therapy may be considered after TSEBT for generalized tumor lesions to improve response duration. 4. In the randomized ALCANZA trial (Prince HM, et al. Lancet 2017;390:555-566), brentuximab vedotin was more effective than methotrexate or bexarotene in patients with previously treated MF (≥ stage IB). Patients with SS were excluded from the ALCANZA trial. 5. In the randomized MAVORIC trial (Kim YH, et al. Lancet Oncol 2018;19:1192-1204), mogamulizumab was more effective than vorinostat in patients with previously treated MF (≥ stage IB) and SS. Responses were higher in patients with blood involvement (stage III or stage IV disease) than those with stage IIB or stage IB/IIA disease. Patients with MF-LCT were excluded from the MAVORIC trial. 6. Alternative retinoids (acitretin or isotretinoin) could be considered in place of bexarotene. 7. ECP may be more appropriate as systemic therapy in patients with some blood involvement (B1 or B2). 8. There are limited safety data for the use of TSEBT in combination with systemic retinoids, HDAC inhibitors (such as vorinostat or romidepsin), or mogamulizumab, or combining phototherapy with vorinostat or romidepsin. 9. Patients with disease achieving a clinical benefit and/ or those with disease responding to treatment should be considered for maintenance or tapering of regimens to optimize response duration. 10. LCT-MF was not an exclusion criteria for Study 302, which evaluated a reformulated version of denileukin diftitox, but no patients with LCT-MF were enrolled in the study.

Footnotes on MFSS-A 9 of 12

Note: All recommendations are category 2A unless otherwise indicated.

Version 2.2026, 02/13/26 © 2026 National Comprehensive Cancer Network® (NCCN®), All rights reserved. NCCN Guidelines® and this illustration may not be reproduced in any form without the express written permission of NCCN.

PLEASE NOTE that use of this NCCN Content is governed by the End-User License Agreement, and you MAY NOT distribute this Content or use it with any artificial intelligence model or tool.
Printed by Galya Basol Kochav on 2/16/2026 9:44:21 AM. Copyright © 2026 National Comprehensive Cancer Network, Inc. All Rights Reserved.

TABLE 4: STAGE III MF (Erythrodermic Disease) - MFSS-10[a,b,c,e]

SUGGESTED REGIMENS	TREATMENT CONSIDERATIONS (SEE ALSO GENERAL CONSIDERATIONS ON MFSS-A [1 of 12])
• Systemic therapy + skin-directed therapy (limited/local or generalized including phototherapy as indicated for stage of disease) Preferred (alphabetical order) • Single agents ▸ Bexarotene ▸ Brentuximab vedotin ▸ ECP ▸ Interferon alfa[b] ▸ Methotrexate ▸ Mogamulizumab ▸ Romidepsin • Combination therapy ▸ ECP + Interferon alfa[b] or retinoid ▸ ECP + Interferon alfa[b] + retinoid ▸ Retinoid + Interferon alfa[b] Other Recommended • Vorinostat Useful in Certain Circumstances (alphabetical order) • Single agents ▸ Acitretin ▸ Alemtuzumab ▸ Denileukin Diftitox-cxdl[d] ▸ Gemcitabine ▸ Interferon gamma-1b ▸ Isotretinoin ▸ Liposomal Doxorubicin ▸ Pembrolizumab ▸ Pralatrexate • Skin-directed therapy ▸ Phototherapy ▸ TSEBT (category 2B)	1. In the randomized ALCANZA trial (Miles Prince H, et al. Lancet 2017;390:555-566), brentuximab vedotin was more effective than methotrexate or bexarotene in patients with previously treated MF (≥ stage IB). Patients with SS were excluded from the ALCANZA trial. 2. In the randomized MAVORIC trial (Kim YH, et al. Lancet Oncol 2018;19:1192-1204), mogamulizumab was more effective than vorinostat in patients with previously treated MF (≥ stage IB) and SS. Responses were higher in patients with blood involvement (stage III or stage IV disease) than those with stage IIB or stage IB/IIA disease. Patients with MF-LCT were excluded from the MAVORIC trial. 3. Alternative retinoids (acitretin or isotretinoin) could be considered in place of bexarotene. 4. ECP may be more appropriate as systemic therapy in patients with some blood involvement (B1 or B2). 5. Phototherapy and TSEBT may be associated with increased toxicity in patients with erythroderma and modification is dose/schedule may be considered. 6. There are limited safety data for the use of TSEBT in combination with systemic retinoids, HDAC inhibitors (such as vorinostat or romidepsin), or mogamulizumab, or combining phototherapy with vorinostat or romidepsin. 7. Patients with disease achieving a clinical benefit and/or those with disease responding to treatment should be considered for maintenance or tapering of regimens to optimize response duration. 8. Patients with erythrodermic disease are at increased risk for secondary infection with skin pathogens and systemic antibiotic therapy should be considered. See MFSS-B. 9. LCT-MF was not an exclusion criteria for Study 302 LCT-MF was not an exclusion criteria for Study 302, which evaluated a reformulated version of denileukin diftitox, but no patients with LCT-MF were enrolled in the study.

Footnotes on MFSS-A 9 of 12

Note: All recommendations are category 2A unless otherwise indicated.

Version 2.2026, 02/13/26 © 2026 National Comprehensive Cancer Network® (NCCN®), All rights reserved. NCCN Guidelines® and this illustration may not be reproduced in any form without the express written permission of NCCN.

PLEASE NOTE that use of this NCCN Content is governed by the End-User License Agreement, and you MAY NOT distribute this Content or use it with any artificial intelligence model or tool.
Printed by Galya Basol Kochav on 2/16/2026 9:44:21 AM. Copyright © 2026 National Comprehensive Cancer Network, Inc. All Rights Reserved.

TABLE 5: SÉZARY SYNDROME (Stage IVA1 or IVA2) - MFSS-11[a,b,c,e]

SUGGESTED REGIMENS		TREATMENT CONSIDERATIONS (SEE ALSO GENERAL CONSIDERATIONS ON MFSS-A [1 of 12])
Low-Intermediate Burden (eg, ASC <5 K/mm³)	**High Burden (eg, ASC >5 K/mm³)**	
• Systemic therapy + skin-directed therapy (limited/local or generalized including phototherapy as indicated for stage of disease) Preferred (alphabetical order) • Single agents ▸ Bexarotene ▸ ECP ▸ Interferon alfa[b] ▸ Methotrexate ▸ Mogamulizumab ▸ Romidepsin ▸ Vorinostat • Combination therapy ▸ ECP + Interferon alfa[b] or retinoid ▸ ECP + Interferon alfa[b] + retinoids ▸ Retinoid + Interferon alfa[b] Other Recommended (alphabetical order) • Alemtuzumab • Brentuximab vedotin • Gemcitabine • Liposomal Doxorubicin • Pembrolizumab • Pralatrexate Useful in Certain Circumstances (alphabetical order) • Acitretin • Interferon gamma-1b • Isotretinoin	• Systemic therapy + skin-directed therapy (limited/local or generalized including phototherapy as indicated for stage of disease) Preferred (alphabetical order) • Single agents ▸ Mogamulizumab ▸ Romidepsin • Combination therapy ▸ ECP + Interferon alfa[b] or retinoid ▸ ECP + Interferon alfa[b] + retinoids ▸ Retinoid + Interferon alfa[b] Other Recommended (alphabetical order) • Alemtuzumab • Bexarotene • Brentuximab vedotin • ECP • Gemcitabine • Interferon alfa[b] • Liposomal Doxorubicin • Methotrexate • Pembrolizumab • Pralatrexate • Vorinostat Useful in Certain Circumstances (alphabetical order) • Acitretin • Interferon gamma-1b • Isotretinoin	1. In the randomized ALCANZA trial (Miles Prince H, et al. Lancet 2017;390:555-566), brentuximab vedotin was more effective than methotrexate or bexarotene in patients with previously treated MF (≥ stage IB). Patients with SS were excluded from the ALCANZA trial. 2. In the randomized MAVORIC trial (Kim YH, et al. Lancet Oncol 2018;19:1192-1204), mogamulizumab was more effective than vorinostat in patients with previously treated MF (≥ stage IB) and SS. Responses were higher in patients with blood involvement (stage III or stage IV disease) than those with stage IIB or stage IB/IIA disease. Patients with MF-LCT were excluded from the MAVORIC trial. 3. Alternative retinoids (acitretin or isotretinoin) could be considered in place of bexarotene. 4. There are limited safety data for the use of TSEBT in combination with systemic retinoids, HDAC inhibitors (such as vorinostat or romidepsin), or mogamulizumab, or combining phototherapy with vorinostat or romidepsin. 5. Patients with disease achieving a clinical benefit and/or those with disease responding to treatment should be considered for maintenance or tapering of regimens to optimize response duration.

Footnotes on MFSS-A 9 of 12

Note: All recommendations are category 2A unless otherwise indicated.

Version 2.2026, 02/13/26 © 2026 National Comprehensive Cancer Network® (NCCN®), All rights reserved. NCCN Guidelines® and this illustration may not be reproduced in any form without the express written permission of NCCN.

PLEASE NOTE that use of this NCCN Content is governed by the End-User License Agreement, and you MAY NOT distribute this Content or use it with any artificial intelligence model or tool.
Printed by Galya Basol Kochav on 2/16/2026 9:44:21 AM. Copyright © 2026 National Comprehensive Cancer Network, Inc. All Rights Reserved.

TABLE 6: STAGE IV MF (Non-Sézary/Visceral Organ Disease) AND MF WITH LARGE CELL TRANSFORMATION (MF-LCT)[c,e,f]

SUGGESTED REGIMENS		TREATMENT CONSIDERATIONS (SEE ALSO GENERAL CONSIDERATIONS ON MFSS-A [1 of 12])
Non-Sézary (stage IVA2) or Visceral/Solid Organ (stage IVB) Disease (MFSS-11)	**MF-LCT (MFSS-12)**	
• Systemic therapy ± RT for local control Preferred (alphabetical order) • Brentuximab vedotin • Gemcitabine • Liposomal Doxorubicin • Pralatrexate • Romidepsin Other Recommended • Mogamulizumab • Multiagent chemotherapy regimens (see NCCN Guidelines for T-Cell Lymphomas - PTCL-B 3 of 8 for regimens listed for peripheral T-cell lymphoma not otherwise specified [PTCL-NOS])	• TSEBT OR • Systemic therapy + skin-directed therapy Preferred (alphabetical order) • Brentuximab vedotin • Gemcitabine • Liposomal Doxorubicin • Pralatrexate • Romidepsin • Multiagent chemotherapy regimens (see NCCN Guidelines for T-Cell Lymphomas - PTCL-B 3 of 8 for regimens listed for PTCL-NOS) Other Recommended • Pembrolizumab	1. In the MAVORIC trial (Kim YH, et al. Lancet Oncol 2018;19:1192-1204), mogamulizumab was more effective than vorinostat in patients with previously treated MF and SS. Response rates were higher in the blood compartment than in LNs or viscera. Patients with MF-LCT were excluded from the MAVORIC trial. 2. There are limited safety data for the use of TSEBT in combination with systemic retinoids, HDAC inhibitors (such as vorinostat or romidepsin), or mogamulizumab, or combining phototherapy with vorinostat or romidepsin. 3. In patients requiring chemotherapy, single agents are preferred over combination chemotherapy, due to the higher toxicity profiles associated with multiagent regimens and the short-lived responses seen with time-limited combination chemotherapy. 4. Multiagent chemotherapy regimens are generally reserved for patients with relapsed/refractory or extracutaneous disease. Most patients are treated with multiple single-agent systemic therapies before receiving multiagent chemotherapy.

TABLE 7: RELAPSED OR REFRACTORY DISEASE TO MULTIPLE PRIOR THERAPIES

SUGGESTED REGIMENS
Useful in Certain Circumstances (alphabetical order by category) • Alemtuzumab • Chlorambucil • Cyclophosphamide • Duvelisib[g] • Etoposide • Lenalidomide[h] • Pembrolizumab • Pentostatin • Temozolomide for central nervous system (CNS) involvement at some NCCN Member Institutions • Multiagent chemotherapy regimens (see NCCN Guidelines for T-Cell Lymphomas - PTCL-B 3 of 8 for regimens listed for PTCL-NOS)

Note: All recommendations are category 2A unless otherwise indicated.

Footnotes on MFSS-A 9 of 12

Version 2.2026, 02/13/26 © 2026 National Comprehensive Cancer Network® (NCCN®), All rights reserved. NCCN Guidelines® and this illustration may not be reproduced in any form without the express written permission of NCCN.

PLEASE NOTE that use of this NCCN Content is governed by the End-User License Agreement, and you MAY NOT distribute this Content or use it with any artificial intelligence model or tool.
Printed by Galya Basol Kochav on 2/16/2026 9:44:21 AM. Copyright © 2026 National Comprehensive Cancer Network, Inc. All Rights Reserved.

FOOTNOTES

[a] Laboratory studies for triglycerides, and thyroid function tests (with free thyroxine T4) are recommended for patients receiving bexarotene.

[b] Peginterferon alfa-2a or ropeginterferon alfa-2b-njft (if peginterferon alfa-2a is unavailable) may be substituted for other alpha interferon preparations (Schiller M, et al. J Eur Acad Dermatol Venerol 2017;31:1841-1847; Patsatsi A, et al. J Eur Acad Dermatol Venereol 2022;36:e291-e293; Osman S, et al. Dermatologic Therapy 2023;2023:7171937; Mesa R et al. Ann Hematol 2025;104:2571-2573).

[c] In the ALCANZA trial, brentuximab vedotin was associated with superior clinical outcome in patients with previously treated CD30+ MF (CD30 positivity was defined as CD30 expression in ≥10% of total lymphoid cells). Interpretation of CD30 expression is not universally standardized. Responses have been seen in patients with a low level of CD30 positivity and any level of CD30 positivity is acceptable for the use of brentuximab vedotin.

[d] In Study 302, CD25 positivity was defined as detectable CD25 in ≥20% of total lymphoid cells in biopsy specimen by IHC. However, there was no correlation between the CD25 expression and the efficacy of denileukin diftitox.

[e] Rapid progression has been reported in patients receiving pembrolizumab, who test positive for HTLV. Disease flare is seen in some patients (especially in patients with erythrodermic MF or SS) and should be distinguished from disease progression (Khodadoust MS, et al. J Clin Oncol 2020:38:20-28).

[f] Lower doses of alemtuzumab administered subcutaneously have shown lower incidence of infectious complications. While alemtuzumab is no longer commercially available, it may be obtained for clinical use. Recommend cytomegalovirus (CMV) monitoring and *pneumocystis jirovecii* pneumonia (PJP) prophylaxis (PCLYM-C).

[g] Duvelisib dosing used in this series is lower than that used in other studies. Initial duvelisib dosing was 15 mg daily with subsequent dose modification based on patient weight (eg, increase to 15 mg BID was considered for a weight >90 kg) and tolerability. Doses ultimately ranged from 15 mg once every other day to BID. One patient received 25 mg once-daily duvelisib (due to the patient's phenobarbital decreasing duvelisib absorption). Bazewicz C, Verardi N, Akilov O. Utility of low-dose duvelisib for advanced mycosis fungoides: a single-institution study. Oncologist 2024;29:272-274.

[h] Lenalidomide dosing in the trial initially was 25 mg daily for 21 days but due to a frequently observed combination of debilitating fatigue and transient tumor flare reactions, the study was amended and subsequent patients initiated treatment at a dose of 10 mg daily. The dose was then increased by 5 mg every 28 days to a maximum of 25 mg daily, based on patient tolerability and response. Querfeld C, Rosen S, Guitart J, et al. Results of an open-label multicenter phase 2 trial of lenalidomide monotherapy in refractory mycosis fungoides and Sézary syndrome. Blood 2014;123:1159-1166.

Note: All recommendations are category 2A unless otherwise indicated.

Version 2.2026, 02/13/26 © 2026 National Comprehensive Cancer Network® (NCCN®), All rights reserved. NCCN Guidelines® and this illustration may not be reproduced in any form without the express written permission of NCCN.

PLEASE NOTE that use of this NCCN Content is governed by the End-User License Agreement, and you MAY NOT distribute this Content or use it with any artificial intelligence model or tool.
Printed by Galya Basol Kochav on 2/16/2026 9:44:21 AM. Copyright © 2026 National Comprehensive Cancer Network, Inc. All Rights Reserved.

SUGGESTED TREATMENT REGIMENS
REFERENCES

Skin-Directed Therapies

Topical corticosteroids

Zackheim HS, Kashani-Sabet M, Amin S. Topical corticosteroids for mycosis fungoides. Experience in 79 patients. Arch Dermatol 1998;134:949-954.

Zackheim HS. Treatment of patch stage mycosis fungoides with topical corticosteroids. Dermatol Ther 2003;16:283-287.

Mechlorethamine hydrochloride (nitrogen mustard)

Alexander-Savino CV, Chung CG, Gilmore ES, et al. Randomized mechlorethamine/chlormethine induced dermatitis assessment study (MIDAS) establishes benefit of topical triamcinolone 0.1% ointment cotreatment in mycosis fungoides. Dermatol Ther (Heidelb) 2022;12:643-654.

Kim EJ, Guitart J, Querfeld C, et al. The PROVe study: US real-world experience with chlormethine/mechlorethamine gel in combination with other therapies for patients with mycosis fungoides cutaneous T-cell lymphoma. Am J Clin Dermato 2021;22:407-414.

Lessin SR, Duvic M, Guitart J, et al. Topical chemotherapy in cutaneous T-cell lymphoma: positive results of a randomized, controlled, multicenter trial testing the efficacy and safety of a novel mechlorethamine, 0.02%, gel in mycosis fungoides. JAMA Dermatol 2013;149:25-32.

Querfeld C, Geskin LJ, Kim EJ, et al. Lack of systemic absorption of topical mechlorethamine gel in patients with mycosis fungoides cutaneous T-cell lymphoma. J Invest Dermatol 2021;141:1601-1604.e2.

Local radiation

Wilson LD, Kacinski BM, Jones GW. Local superficial radiotherapy in the management of minimal stage IA cutaneous T-cell lymphoma (Mycosis Fungoides). Int J Radiat Oncol Biol Phys 1998;40:109-115.

Neelis KJ, Schimmel EC, Vermeer MH, et al. Low-dose palliative radiotherapy for cutaneous B- and T-cell lymphomas. Int J Radiat Oncol Biol Phys 2009;74:154-158.

Specht L, Dabaja B, Illidge T, et al. Modern radiation therapy for primary cutaneous lymphomas: field and dose guidelines from the International Lymphoma Radiation Oncology Group. Int J Radiat Oncol Biol Phys 2015;92:32-39.

Thomas TO, Agrawal P, Guitart J, et al. Outcome of patients treated with a single-fraction dose of palliative radiation for cutaneous T-cell lymphoma. Int J Radiat Oncol Biol Phys 2013;85:747-753.

Topical bexarotene

Breneman D, Duvic M, Kuzel T, et al. Phase 1 and 2 trial of bexarotene gel for skin-directed treatment of patients with cutaneous T-cell lymphoma. Arch Dermatol 2002;138:325-332.

Heald P, Mehlmauer M, Martin AG, et al. Topical bexarotene therapy for patients with refractory or persistent early-stage cutaneous T-cell lymphoma: results of the phase III clinical trial. J Am Acad Dermatol 2003;49:801-815.

Tazarotene gel

Apisarnthanarax N, Talpur R, Ward S, et al. Tazarotene 0.1% gel for refractory mycosis fungoides lesions: an open-label pilot study. J Am Acad Dermatol 2004;50:600-607.

Topical imiquimod

Deeths MJ, Chapman JT, Dellavalle RP, et al. Treatment of patch and plaque stage mycosis fungoides with imiquimod 5% cream. J Am Acad Dermatol 2005;52:275-280.

Topical calcineurin inhibitors

Ortiz-Romero PL, Jiménez LM, Muniesa C, et al. Activity and safety of topical pimecrolimus in patients with early stage mycosis fungoides (PimTo-MF): a single-arm, multicentre, phase 2 trial. Lancet Haematol 2022;9:e425-e433.

Weiner DM, Clark AK, Bhansali RS, et al. Usage and safety of topical tacrolimus in patients with mycosis fungoides. Clin Exp Dermatol 2022;47:1200-1201.

Phototherapy (UVB and PUVA)

Gathers RC, Scherschun L, Malick F, et al. Narrowband UVB phototherapy for early-stage mycosis fungoides. J Am Acad Dermatol 2002;47:191-197.

Querfeld C, Rosen ST, Kuzel TM, et al. Long-term follow-up of patients with early-stage cutaneous T-cell lymphoma who achieved complete remission with psoralen plus UV-A monotherapy. Arch Dermatol 2005;141:305-311.

Ponte P, Serrao V, Apetato M. Efficacy of narrowband UVB vs. PUVA in patients with early-stage mycosis fungoides. J Eur Acad Dermatol Venereol 2010;24:716-721.

Olsen EA, Hodak E, Anderson T, et al. Guidelines for phototherapy of mycosis fungoides and Sézary syndrome: A consensus statement of the United States Cutaneous Lymphoma Consortium. J Am Acad Dermatol 2018;74:27-58.

UVA1

Trovato E, Pellegrino M, Filippi F, et al. Clinical and histological evaluation in patients with mycosis fungoides treated with UVA1. G Ital Dermatol Venereol 2020;155:306-311.

Adışen E, Tektaş V, Erduran F, et al. Ultraviolet A1 phototherapy in the treatment of early mycosis fungoides. Dermatology 2017;233:192-198.

Olek-Hrab K, Silny W, Dańczak-Pazdrowska A, et al. Ultraviolet A1 phototherapy for mycosis fungoides. Clin Exp Dermatol 2013;38:126-130.

Jang MS, Jang JY, Park JB, et al. Erratum: Folliculotropic mycosis fungoides in 20 Korean cases: Clinical and histopathologic features and response to ultraviolet A-1 and/or photodynamic therapy. Ann Dermatol 2018;30:510.

Zane C, Leali C, Airò P, et al. "High-dose" UVA1 therapy of widespread plaque-type, nodular, and erythrodermic mycosis fungoides. J Am Acad Dermatol 2001;44:629-633.

Total skin electron beam therapy (TSEBT)

Chinn DM, Chow S, Kim YH, Hoppe RT. Total skin electron beam therapy with or without adjuvant topical nitrogen mustard or nitrogen mustard alone as initial treatment of T2 and T3 mycosis fungoides. Int J Radiat Oncol Biol Phys 1999;43:951-958.

Ysebaert L, Truc G, Dalac S, et al. Ultimate results of radiation therapy for T1-T2 mycosis fungoides. Int J Radiat Oncol Biol Phys 2004;58:1128-1134.

Hoppe RT, Harrison C, Tavallaee M, et al. Low-dose total skin electron beam therapy as an effective modality to reduce disease burden in patients with mycosis fungoides: results of a pooled analysis from 3 phase-II clinical trials. J Am Acad Dermatol 2015;72:286-292.

Morris S, Scarisbrick J, Frew J, et al. The results of low-dose total skin electron beam radiation therapy (TSEB) in patients with mycosis fungoides from the UK Cutaneous Lymphoma Group. Int J Radiat Oncol Biol Phys 2017;99:627-633.

Specht L, Dabaja B, Illidge T, et al. Modern radiation therapy for primary cutaneous lymphomas: field and dose guidelines from the International Lymphoma Radiation Oncology Group. Int J Radiat Oncol Biol Phys 2015;92:32-39.

Continued

Note: All recommendations are category 2A unless otherwise indicated.

Version 2.2026, 02/13/26 © 2026 National Comprehensive Cancer Network® (NCCN®), All rights reserved. NCCN Guidelines® and this illustration may not be reproduced in any form without the express written permission of NCCN.

PLEASE NOTE that use of this NCCN Content is governed by the End-User License Agreement, and you MAY NOT distribute this Content or use it with any artificial intelligence model or tool.
Printed by Galya Basol Kochav on 2/16/2026 9:44:21 AM. Copyright © 2026 National Comprehensive Cancer Network, Inc. All Rights Reserved.

SUGGESTED TREATMENT REGIMENS
REFERENCES

Systemic Therapies

Alemtuzumab
Lundin J, Hagberg H, Repp R, et al. Phase 2 study of alemtuzumab (anti-CD52 monoclonal antibody) in patients with advanced mycosis fungoides/Sezary syndrome. Blood 2003;101:4267-4272.
Bernengo MG, Quaglino P, Comessatti A, et al. Low-dose intermittent alemtuzumab in the treatment of Sezary syndrome: clinical and immunologic findings in 14 patients. Haematologica 2007;92:784-794.
Gautschi O, Blumenthal N, Streit M, et al. Successful treatment of chemotherapy-refractory Sezary syndrome with alemtuzumab (Campath-1H). Eur J Haematol 2004;72:61-63.
Querfeld C, Mehta N, Rosen ST, et al. Alemtuzumab for relapsed and refractory erythrodermic cutaneous T-cell lymphoma: a single institution experience from the Robert H. Lurie Comprehensive Cancer Center. Leuk Lymphoma 2009;50:1969-1976.

Brentuximab vedotin
Kim YH, Tavallaee M, Sundram U, et al. Phase II investigator-initiated study of brentuximab vedotin in mycosis fungoides and Sezary syndrome with variable CD30 expression level: A multi-institution collaborative project. J Clin Oncol 2015;33:3750-3758.
Prince HM, Kim YH, Horwitz SM, et al. Brentuximab vedotin or physician's choice in CD30-positive cutaneous T-cell lymphoma (ALCANZA): an international, open-label, randomised, phase 3, multicentre trial. Lancet 2017;390:555-566.

Denileukin diftitox-cxdl
Foss FM, Kim YH, Prince HM, et al. Efficacy and safety of denileukin diftitox-cxdl, an improved purity formulation of denileukin diftitox, in patients with relapsed or refractory cutaneous T-cell lymphoma. J Clin Oncol 2025;43:1198-1209.

Extracorporeal photopheresis (ECP)
Talpur R, Demierre MF, Geskin L, et al. Multicenter photopheresis intervention trial in early-stage mycosis fungoides. Clin Lymphoma Myeloma Leuk 2011;11:219-227.
Knobler R, Duvic M, Querfeld C, et al. Long-term follow-up and survival of cutaneous T-cell lymphoma patients treated with extracorporeal photopheresis. Photodermatol Photoimmunol Photomed 2012;28:250-257.
Atilla E, Atilla PA, Bozdag SC, et al. Extracorporeal photochemotherapy in mycosis fungoides. Transfus Clin Biol 2017;24:454-457.
Gao C, McCormack C, van der Weyden C, et al. Prolonged survival with the early use of a novel extracorporeal photopheresis regimen in patients with Sezary syndrome. Blood 2019;134:1346-1350.

Gemcitabine
Duvic M, Talpur R, Wen S, et al. Phase II evaluation of gemcitabine monotherapy for cutaneous T-cell lymphoma. Clin Lymphoma Myeloma 2006;7:51-58.
Marchi E, Alinari L, Tani M, et al. Gemcitabine as frontline treatment for cutaneous T-cell lymphoma: phase II study of 32 patients. Cancer 2005;104:2437-2441.
Zinzani PL, Baliva G, Magagnoli M, et al. Gemcitabine treatment in pretreated cutaneous T-cell lymphoma: experience in 44 patients. J Clin Oncol 2000;18:2603-2606.
Zinzani PL, Venturini F, Stefoni V, et al. Gemcitabine as single agent in pretreated T-cell lymphoma patients: evaluation of the long-term outcome. Ann Oncol 2010;21:860-863.
Awar O, Duvic M. Treatment of transformed mycosis fungoides with intermittent low-dose gemcitabine. Oncology 2007;73:130-135.

Interferon
Olsen EA. Interferon in the treatment of cutaneous T-cell lymphoma. Dermatol Ther 2003;16:311-321.
Kaplan EH, Rosen ST, Norris DB, et al. Phase II study of recombinant human interferon gamma for treatment of cutaneous T-cell lymphoma. J Natl Cancer Inst 1990;82:208-212.

Liposomal doxorubicin
Pulini S, Rupoli S, Goteri G, et al. Pegylated liposomal doxorubicin in the treatment of primary cutaneous T-cell lymphomas. Haematologica 2007;92:686-689.
Quereux G, Marques S, Nguyen JM, et al. Prospective multicenter study of pegylated liposomal doxorubicin treatment in patients with advanced or refractory mycosis fungoides or Sezary syndrome. Arch Dermatol 2008;144:727-733.
Dummer R, Quaglino P, Becker JC, et al. Prospective international multicenter phase II trial of intravenous pegylated liposomal doxorubicin monochemotherapy in patients with stage IIB, IVA, or IVB advanced mycosis fungoides: final results from EORTC 21012. J Clin Oncol 2012;30:4091-4097.
Weiner D, Ly A, Talluru S, et al. Efficacy of single-agent chemotherapy with pegylated liposomal doxorubicin or gemcitabine in a diverse cohort of patients with recalcitrant cutaneous T-cell lymphoma. Br J Dermatol 2024;190:436-438.
Falkenhain-Lopez D, Fulgencio-Barbarin J, Puerta-Pena M, et al. Single-centre experience of using pegylated liposomal doxorubicin as maintenance treatment in mycosis fungoides. Br J Dermatol 2022;186:363-365.

Methotrexate
Zackheim HS, Kashani-Sabet M, Hwang ST. Low-dose methotrexate to treat erythrodermic cutaneous T-cell lymphoma: results in twenty-nine patients. J Am Acad Dermatol 1996;34:626-631.
Zackheim HS, Kashani-Sabet M, McMillan A. Low-dose methotrexate to treat mycosis fungoides: a retrospective study in 69 patients. J Am Acad Dermatol 2003;49:873-878.

Mogamulizumab
Kim YH, Bagot M, Pinter-Brown L, et al. Mogamulizumab versus vorinostat in previously treated cutaneous T-cell lymphoma (MAVORIC): An international, open-label, randomised, controlled phase 3 trial. Lancet Oncol 2018;19:1192-1204.

Pembrolizumab
Khodadoust MS, Rook AH, Porcu P, et al. Pembrolizumab in relapsed and refractory mycosis fungoides and Sezary syndrome: A multicenter phase II study. J Clin Oncol 2020;38:20-28.

Pentostatin
Cummings FJ, Kim K, Neiman RS, et al. Phase II trial of pentostatin in refractory lymphomas and cutaneous T-cell disease. J Clin Oncol 1991;9:565-571.
Greiner D, Olsen EA, Petroni G. Pentostatin (2'-deoxycoformycin) in the treatment of cutaneous T-cell lymphoma. J Am Acad Dermatol 1997;36:950-955.
Tsimberidou AM, Giles F, Duvic M, et al. Phase II study of pentostatin in advanced T-cell lymphoid malignancies. Update on an M.D. Anderson Cancer Center Series. Cancer 2004;100;342-349.

Continued

Note: All recommendations are category 2A unless otherwise indicated.

Version 2.2026, 02/13/26 © 2026 National Comprehensive Cancer Network® (NCCN®), All rights reserved. NCCN Guidelines® and this illustration may not be reproduced in any form without the express written permission of NCCN.

PLEASE NOTE that use of this NCCN Content is governed by the End-User License Agreement, and you MAY NOT distribute this Content or use it with any artificial intelligence model or tool.
Printed by Galya Basol Kochav on 2/16/2026 9:44:21 AM. Copyright © 2026 National Comprehensive Cancer Network, Inc. All Rights Reserved.

SUGGESTED TREATMENT REGIMENS
REFERENCES

Systemic Therapies (continued)

Pralatrexate

Horwitz SM, Kim YH, Foss F, et al. Identification of an active, well-tolerated dose of pralatrexate in patients with relapsed or refractory cutaneous T-cell lymphoma. Blood 2012;119:4115-4122.

Foss F, Horwitz SM, Coiffier B, et al. Pralatrexate is an effective treatment for relapsed or refractory transformed mycosis fungoides: a subgroup efficacy analysis from the PROPEL study. Clin Lymphoma Myeloma Leuk 2012;12:238-243.

Romidepsin

Piekarz RL, Frye R, Turner M, et al. Phase II multi-institutional trial of the histone deacetylase inhibitor romidepsin as monotherapy for patients with cutaneous T-cell lymphoma. J Clin Oncol 2009;27:5410-5417.

Whittaker SJ, Demierre MF, Kim EJ, et al. Final results from a multicenter, international, pivotal study of romidepsin in refractory cutaneous T-cell lymphoma. J Clin Oncol 2010;28:4485-4491.

Retinoids

Zhang C, Duvic M. Treatment of cutaneous T-cell lymphoma with retinoids. Dermatol Ther 2006;19:264-271.

Duvic M, Martin AG, Kim Y, et al. Phase 2 and 3 clinical trial of oral bexarotene (Targretin capsules) for the treatment of refractory or persistent early-stage cutaneous T-cell lymphoma. Arch Dermatol 2001;137:581-593.

Duvic M, Hymes K, Heald P, et al. Bexarotene is effective and safe for treatment of refractory advanced-stage cutaneous T-cell lymphoma: multinational phase II-III trial results. J Clin Oncol 2001;19:2456-2471.

Temozolomide

Tani M, Fina M, Alinari L, et al. Phase II trial of temozolomide in patients with pretreated cutaneous T-cell lymphoma. Haematologica 2005;90:1283-1284.

Querfeld C, Rosen ST, Guitart J, et al. Multicenter phase II trial of temozolomide in mycosis fungoides/sezary syndrome: correlation with O^6-methylguanine-DNA methyltransferase and mismatch repair proteins. Clin Cancer Res 2011;17:5748-5754.

Vorinostat

Duvic M, Talpur R, Ni X, et al. Phase 2 trial of oral vorinostat (suberoylanilide hydroxamic acid, SAHA) for refractory cutaneous T-cell lymphoma (CTCL). Blood 2007;109:31-39.

Olsen EA, Kim YH, Kuzel TM, et al. Phase IIb multicenter trial of vorinostat in patients with persistent, progressive, or treatment refractory cutaneous T-cell lymphoma. J Clin Oncol 2007;25:3109-3115.

Duvic M, Olsen EA, Breneman D, et al. Evaluation of the long-term tolerability and clinical benefit of vorinostat in patients with advanced cutaneous T-cell lymphoma. Clin Lymphoma Myeloma 2009;9:412-416.

Combination Therapies

Systemic + skin-directed

Rupoli S, Goteri G, Pulini S, et al. Long-term experience with low-dose interferon-alpha and PUVA in the management of early mycosis fungoides. Eur J Haematol 2005;75:136-145.

Kuzel T, Roenigk H Jr, Samuelson E, et al. Effectiveness of interferon alfa-2a combined with phototherapy for mycosis fungoides and the Sézary syndrome. J Clin Oncol 1995;13:257-263.

McGinnis K, Shapiro M, Vittorio C, et al. Psoralen plus long-wave UV-A (PUVA) and bexarotene therapy: An effective and synergistic combined adjunct to therapy for patients with advanced cutaneous T cell lymphoma. Arch Dermatol 2003;139:771-775.

Wilson LD, Jones GW, Kim D, et al. Experience with total skin electron beam therapy in combination with extracorporeal photopheresis in the management of patients with erythrodermic (T4) mycosis fungoides. J Am Acad Dermatol 2000;43:54-60.

Stadler R, Otte HG, Luger T, et al. Prospective randomized multicenter clinical trial on the use of interferon alpha -2a plus acitretin versus interferon alpha -2a plus PUVA in patients with cutaneous T-cell lymphoma stages I and II. Blood 1998;92:3578-3581.

Systemic + systemic

Straus DJ, Duvic M, Kuzel T, et al. Results of a phase II trial of oral bexarotene (Targretin) combined with interferon alfa-2b (Intron-A) for patients with cutaneous T-cell lymphoma. Cancer 2007;109:1799-1803.

Talpur R, Ward S, Apisarnthanarax N, et al. Optimizing bexarotene therapy for cutaneous T-cell lymphoma. J Am Acad Dermatol 2002;47:672-684.

Suchin KR, Cucchiara AJ, Gottleib SL, et al. Treatment of cutaneous T-cell lymphoma with combined immunomodulatory therapy: a 14-year experience at a single institution. Arch Dermatol 2002;138:1054-1060.

Raphael BA, Shin DB, Suchin KR, et al. High clinical response rate of Sezary syndrome to immunomodulatory therapies: prognostic markers of response. Arch Dermatol 2011;147:1410-1415.

Allogeneic HCT

de Masson A, Beylot-Barry M, Bouaziz JD, et al. Allogeneic stem cell transplantation for advanced cutaneous T-cell lymphomas: a study from the French Society of Bone Marrow Transplantation and French Study Group on Cutaneous Lymphomas. Haematologica 2014;99:527-534.

de Masson A, Beylot-Barry M, Ram-Wolff C, et al. Allogeneic transplantation in advanced cutaneous T-cell lymphomas (CUTALLO): a propensity score matched controlled prospective study. Lancet 2023;401:1941-1950.

Duarte R, Boumendil A, Onida F, et al. Long-term outcome of allogeneic hematopoietic cell transplantation for patients with mycosis fungoides and Sézary syndrome: a European society for blood and marrow transplantation lymphoma working party extended analysis. J Clin Oncol 2014;32:3347-3348.

Duarte RF, Schmitz N, Servitje O, Sureda A. Haematopoietic stem cell transplantation for patients with primary cutaneous T-cell lymphoma. Bone Marrow Transplant 2008;41:597-604.

Hosing C, Bassett R, Dabaja B, et al. Allogeneic stem-cell transplantation in patients with cutaneous lymphoma: updated results from a single institution. Ann Oncol 2015;26:2490-2495.

Iqbal M, Reljic T, Ayala E, et al. Efficacy of allogeneic hematopoietic cell transplantation in cutaneous T cell lymphoma: Results of a systematic review and meta-analysis. Biol Blood Marrow Transplant 2020;26:76-82.

Johnson WT, Mukherji R, Kartan S, et al. Allogeneic hematopoietic stem cell transplantation in advanced stage mycosis fungoides and Sezary syndrome: a concise review. Chin Clin Oncol 2019;8:12.

Lechowicz M, Lazarus HM, Carreras J, et al. Allogeneic hematopoietic cell transplantation for mycosis fungoides and Sezary syndrome. Bone Marrow Transplant 2014;49:1360-1365.

Weng WK, Arai S, Rezvani A, et al. Nonmyeloablative allogeneic transplantation achieves clinical and molecular remission in cutaneous T-cell lymphoma. Blood Adv 2020;4:4474-4482.

Wu PA, Kim YH, Lavori PW, et al. A meta-analysis of patients receiving allogeneic or autologous hematopoietic stem cell transplant in mycosis fungoides and Sezary syndrome. Biol Blood Marrow Transplant 2009;15:982-990.

Note: All recommendations are category 2A unless otherwise indicated.

Version 2.2026, 02/13/26 © 2026 National Comprehensive Cancer Network® (NCCN®), All rights reserved. NCCN Guidelines® and this illustration may not be reproduced in any form without the express written permission of NCCN.

PLEASE NOTE that use of this NCCN Content is governed by the End-User License Agreement, and you MAY NOT distribute this Content or use it with any artificial intelligence model or tool.
Printed by Galya Basol Kochav on 2/16/2026 9:44:21 AM. Copyright © 2026 National Comprehensive Cancer Network, Inc. All Rights Reserved.

SUPPORTIVE CARE FOR PATIENTS WITH MF/SS

Collaboration with dermatologist for supportive care is essential.

Pruritus

- Assessment
  - Pruritus should be assessed
  - Correlation between sites of disease and localization of pruritus may be useful in tailoring therapy
  - For severe or persistent pruritus despite therapeutic response other potential causes for pruritus should be investigated

- Treatment
  - Co-management with a dermatologist with expertise in skin care and CTCL
  - Optimized skin-directed and systemic therapy for MF/SS
  - Mild, unscented soaps for bathing are gentle and optimal to prevent skin dryness
  - Moisturizers/emollients
  - Topical steroid application (appropriate strength for body region) ± occlusion[1]
  - Topical over-the-counter preparations
  - Systemic agents
    - ◊ First-line
      - – H1 antihistamines; single agent or combination of antihistamines from different classes[2]
      - – Gabapentin[3,4]
      - – Pregabalin
    - ◊ Second-line
      - – Aprepitant[5-8]
      - – Mirtazapine[4]
      - – Selective serotonin reuptake inhibitors (SSRIs)[9]
    - ◊ Third-line
      - – Naltrexone[10]
      - – Systemic steroids

Infections

- Active or suspected infections
  - Cutaneous viral infections
    - ◊ High risk for skin dissemination of localized viral infections herpes simplex virus (HSV)/varicella zoster virus (VZV).
    - ◊ HSV prophylaxis with acyclovir or equivalent should be considered for patients with frequent recurrence of HSV infection.
  - Erythroderma:
    - ◊ Swab of skin, nares, or other areas for cultures of *Staphylococcus aureus* (*S. aureus*) infection or colonization
    - ◊ Intranasal mupirocin for *S. aureus* carriers
    - ◊ Oral dicloxacillin or cephalexin
    - ◊ Sulfamethoxazole/trimethoprim, doxycycline, minocycline, or clindamycin if suspected methicillin-resistant *S. aureus* (MRSA)
    - ◊ Vancomycin if no improvement or documented bacteremia
    - ◊ IV broad-spectrum antibiotics for *S. aureus* infection[11]
    - ◊ Bleach baths [1/2 cup of regular strength bleach (5%–6%) in full tub of water] or for limited areas, soaks (1 tsp of bleach in 1 gallon of water). Bleach baths should be taken for 5 to 10 minutes two to three times a week maximum followed by tap water to rinse off the bleach water. Moisturizer should be put on immediately following the bleach bath or soak.
  - Ulcerated and necrotic tumors:
    - ◊ Infection or colonization with Gram-negative rods should be considered in addition to the more common gram-positive organisms.
    - ◊ Ulcer will not heal unless disease is treated. Consider local RT if feasible.
- Prophylaxis
  - Optimize skin barrier protection with moisturizing of skin
  - Consider mupirocin to the nares for *S. aureus* carriers
  - Diluted bleach baths or soaks (if limited area) as noted above
  - Minimize use of central lines when possible
  - For patients receiving alemtuzumab, see PCLYM-C

References on MFSS-B 2 of 2

Note: All recommendations are category 2A unless otherwise indicated.

Version 2.2026, 02/13/26 © 2026 National Comprehensive Cancer Network® (NCCN®), All rights reserved. NCCN Guidelines® and this illustration may not be reproduced in any form without the express written permission of NCCN.

PLEASE NOTE that use of this NCCN Content is governed by the End-User License Agreement, and you MAY NOT distribute this Content or use it with any artificial intelligence model or tool.
Printed by Galya Basol Kochav on 2/16/2026 9:44:21 AM. Copyright © 2026 National Comprehensive Cancer Network, Inc. All Rights Reserved.

SUPPORTIVE CARE FOR PATIENTS WITH MF/SS
REFERENCES

[1] Yosipovitch G, Szolar C, Hui XY, Maibach H. High-potency topical corticosteroid rapidly decrease histamine-induced itch but not thermal sensation and pain in human beings. J Am Acad Dermatol 1996;35:118-120.
[2] Eschler D, Klein PA. An evidence-based review of the efficacy of topical antihistamines in the relief of pruritus. J Drugs Dermatol 2010;9:992-997.
[3] Matsuda KM, Sharma D, Schonfeld AR, Kwatra SG. Gabapentin and pregabalin for the treatment of chronic pruritus. J Am Acad Dermatol 2016;75:619-625.
[4] Demierre MF, Taverna J. Mirtazapine and gabapentin for reducing pruritus in cutaneous T-cell lymphoma. Am Acad Dermatol 2006;55:543-544.
[5] Jiménez Gallo D, Albarrán Planelles C, Linares Barrios M, et al. Treatment of pruritus in early-stage hypopigmented mycosis fungoides with aprepitant. Dermatol Ther 2014;27:178-182.
[6] Duval A, Dubertret L. Aprepitant as an antipruritic agent? N Engl J Med 2009;361:1415-1416.
[7] Booken N, Heck M, Nicolay JP, et al. Oral aprepitant in the therapy of refractory pruritus in erythrodermic cutaneous T-cell lymphoma. Br J Dermatol 2011;164:665-667.
[8] Ladizinski B, Bazakas A, Olsen EA. Aprepitant: A novel neurokinin-1 receptor/substance P antagonist as antipruritic therapy in cutaneous T-cell lymphoma. J Am Acad Dermatol 2012;67:e198-e199.
[9] Ständer S, Böckenholt B, Schürmeyer-Horst F, et al. Treatment of chronic pruritus with the selective serotonin re-uptake inhibitors paroxetine and fluvoxamine: results of an open-labelled, two-arm proof-of-concept study. Acta Derm Venereol 2009;89:45-51.
[10] Brune A, Metze D, Luger T, Ständer S. Antipruritic therapy with the oral opioid receptor antagonist naltrexone. Open, non-placebo controlled administration in 133 patients. Hautarzt 2004;55:1130-1136.
[11] Lindahl LM, Willerslev-Olsen A, Gjerdrum LMR, et al. Antibiotics inhibit tumor and disease activity in cutaneous T-cell lymphoma. Blood 2019;134:1072-1083.

Note: All recommendations are category 2A unless otherwise indicated.

Version 2.2026, 02/13/26 © 2026 National Comprehensive Cancer Network® (NCCN®), All rights reserved. NCCN Guidelines® and this illustration may not be reproduced in any form without the express written permission of NCCN.

PLEASE NOTE that use of this NCCN Content is governed by the End-User License Agreement, and you MAY NOT distribute this Content or use it with any artificial intelligence model or tool.
Printed by Galya Basol Kochav on 2/16/2026 9:44:21 AM. Copyright © 2026 National Comprehensive Cancer Network, Inc. All Rights Reserved.

PRINCIPLES OF PHOTOTHERAPY[1]

General Principles

- Phototherapy is used for several indications (including primary or adjuvant treatment for the lymphoma as well as to control pruritus) in cutaneous lymphomas, especially in MF, SS, and lymphomatoid papulosis (LyP).
- PUVA carries an increased risk of melanoma and a higher risk of nonmelanoma skin cancers (NMSCs) than NB-UVB. Therefore, the choice of whether to use PUVA is typically based on its deeper penetration in the skin, an important factor for patients with thick plaque disease or folliculotropism, particularly if phototherapy is used as sole therapy.
- NB-UVB is available in many more offices than PUVA and also as a home panel or unit.
- Hand/foot PUVA is an office-based procedure that can be used at the end of a treatment with whole body PUVA or NB-UVB. If using following NB-UVB, this involves a topical psoralen applied 20–30 minutes prior to UVA exposure.
- UVA1 (available in limited centers) may offer deeper skin penetration without the need for psoralen and thus would allow for its use during pregnancy.
- Relative exclusions for NB-UVB and PUVA include multiple NMSCs, photosensitivity (inherent, drug, or underlying condition), as well as physical and/or financial limitations.
- NB-UVB and PUVA have certain exclusions for treatment based on medical conditions:
  - Xeroderma pigmentosa and photosensitive collagen vascular diseases such as systemic lupus erythematosus (SLE) for both PUVA and NB-UVB
  - Melanoma and pregnancy for PUVA
  - Porphyria for NB-UVB
  - Patients with a previously treated isolated thin melanoma that can be excluded from the field of UV light might be considered in certain circumstances for NB-UVB.

Dosing Guidelines

- The Fitzpatrick skin phototype is typically used to determine the initial and incremental energy dose for an individual patient.
- When starting phototherapy, concomitant medications that are photosensitizers (such as the tetracyclines, amiodarone, and hydrochlorothiazide), a history of treatment that may have induced photosensitivity (such as mogamulizumab), recent TSEBT, or the presence of erythroderma should trigger consideration of decreasing the starting dose and reducing the rate of light escalation to prevent burning.
- If one of the retinoids (bexarotene, acitretin, or isotretinoin; all photosensitizing) or systemic methotrexate is being added to phototherapy to enhance efficacy, consider lowering the current dose of light when starting the medication and taking the oral medication after, not immediately before, phototherapy.
- If phototherapy is being added to a treatment regimen that already includes a retinoid, the initial and incremental energy dose may need to be reduced and adjusted.
- Patients who do not have involvement of their face may help to prevent skin cancers and accelerated aging by covering their face during phototherapy, recognizing that doing so, like covering genitals (recommended in males), creates a “privileged” site.
- Topical medications, such as topical mechlorethamine or topical bexarotene, can be used with phototherapy but should be applied after, not before, phototherapy.
- Patients on long-term phototherapy, alone or in combination with other systemic or topical agents, should be on the lowest dose/least frequent dosing to maintain response and carefully monitored for the development of actinic keratoses, NMSCs, and melanoma.

[1] Olsen, EA, Hodak E, Anderson T, et al. Guidelines for phototherapy of mycosis fungoides and Sézary syndrome: A consensus statement of the United States Cutaneous Lymphoma Consortium. J Am Acad Dermatol 2016;74:27-58. Please see handout information for patients with MF/SS who you plan to treat with either NB-UVB or PUVA.

Note: All recommendations are category 2A unless otherwise indicated.

Version 2.2026, 02/13/26 © 2026 National Comprehensive Cancer Network® (NCCN®), All rights reserved. NCCN Guidelines® and this illustration may not be reproduced in any form without the express written permission of NCCN.

PLEASE NOTE that use of this NCCN Content is governed by the End-User License Agreement, and you MAY NOT distribute this Content or use it with any artificial intelligence model or tool.
Printed by Galya Basol Kochav on 2/16/2026 9:44:21 AM. Copyright © 2026 National Comprehensive Cancer Network, Inc. All Rights Reserved.

PRINCIPLES OF PRIMARY CUTANEOUS CD30+ T-CELL LYMPHOPROLIFERATIVE DISORDERS (LPD)

Overview & Definition

- **Primary cutaneous CD30+ T-cell LPDs represent a spectrum that includes primary cutaneous anaplastic large cell lymphoma (PC-ALCL), LyP, and "borderline" cases with overlapping clinical and histopathologic features.[a,b,c]**
- **Clinical correlation with histopathologic features is essential for establishing the diagnosis of primary cutaneous CD30+ T-cell LPDs; diagnosis cannot be made based on pathology review alone.**

Differential Diagnosis

- **It is critical to distinguish CD30+ T-cell LPDs from other processes involving skin that may express CD30:**
  - **Systemic T-cell lymphomas (eg, ALCL, adult T-cell leukemia/lymphoma [ATLL], PTCL)**
  - **Other CD30+ cutaneous lymphomas such as MF, especially MF with LCT**
  - **Benign disorders such as lymphomatoid drug reactions, arthropod bites, viral infections, and others**
- **Lymphomatoid drug reactions have been linked with certain drugs (eg, amlodipine, carbamazepine, cefuroxime, valsartan) and may be associated with CD30+ atypical large cells in histology.**
- **MF and primary cutaneous CD30+ T-cell LPD can coexist in the same patient.**

- **Primary cutaneous ALCL (PC-ALCL)**
  - **Represents about 8% of cutaneous lymphoma cases.[a]**
  - **Unlike systemic ALCL, PC-ALCL typically follows an indolent course and although cutaneous relapses are common, an excellent prognosis is usually maintained.[d,e]**
  - **Histologically characterized by diffuse, cohesive sheets of large CD30-positive (in >75%) cells with anaplastic, pleomorphic, or immunoblastic appearance.[a]**
  - **Clinical features typically include solitary or localized nodules or tumors (often ulcerated); multifocal lesions occur in about 20% of cases. Extracutaneous disease occurs in about 10% of cases, usually involving regional LNs.[a] Patches and plaques may also be present and some degree of spontaneous remittance in lesions may also be seen.**

- **Lymphomatoid papulosis (LyP)**
  - **LyP is included under the classification system for lymphomas (WHO-EORTC) but may be best classified as an LPD as it is a frequently spontaneously regressing process.[a]**
  - **LyP has been reported to be associated with other lymphomas such as MF, PC-ALCL, systemic ALCL, or Hodgkin lymphoma.[f,g]**
  - **Lyp is histologically heterogeneous with large atypical anaplastic, immunoblastic, or Hodgkin-like cells in a marked inflammatory background[a]; several histologic subtypes can be defined based on evolution of skin lesions.[f]**
  - **Lyp clinical features are characterized by chronic, recurrent, spontaneously regressing papulonodular (grouped or generalized) skin lesions.[a,f]**

[a] WHO Classification of Tumours Editorial Board. Haematolymphoid tumours. (WHO classification of tumours series, 5th ed.; vol. 11). Lyon (France): International Agency for Research on Cancer; 2024; Arber DA, et al. The International Consensus Classification of Myeloid and Lymphoid Neoplasms. 1st ed. Philadelphia, PA: Lippincott Williams & Wilkins; 2025. See Classification (ST-1).
[b] Vergier B, et al. Am J Surg Pathol 1998;22:1192-1202.
[c] Liu HL, et al. J Am Acad Dermatol 2003;49:1049-1058.
[d] Benner MF, Willemze R. Arch Dermatol 2009;145:1399-1404.
[e] Woo DK, et al. Arch Dermatol 2009;145:667-674.
[f] Kempf W, et al. Blood 2011;118:4024-4035.
[g] Due to overlapping immunophenotype and morphology, need to use caution to *not* diagnose CD30+ T-cell in LNs as Hodgkin lymphoma (Eberle FC, et al. Am J Surg Pathol 2012;36:716-725).

Note: All recommendations are category 2A unless otherwise indicated.

Diagnosis on PCTLD-1

Version 2.2026, 02/13/26 © 2026 National Comprehensive Cancer Network® (NCCN®), All rights reserved. NCCN Guidelines® and this illustration may not be reproduced in any form without the express written permission of NCCN.

PLEASE NOTE that use of this NCCN Content is governed by the End-User License Agreement, and you MAY NOT distribute this Content or use it with any artificial intelligence model or tool.
Printed by Galya Basol Kochav on 2/16/2026 9:44:21 AM. Copyright © 2026 National Comprehensive Cancer Network, Inc. All Rights Reserved.

DIAGNOSIS[a]

ESSENTIAL:
- Clinical presentation: see Overview and Definition (PCTLD/INTRO-1)
- Clinical pathologic correlation is essential
- Complete skin examination for any sign of benign or malignant skin lesions
- Biopsy of suspicious skin sites
  - Multiple biopsies may be necessary to capture the pathologic variability of disease at diagnosis
  - Review of a sufficient number of slides with adequate material to perform a comprehensive workup as described below and/or at least one paraffin block representative of the tumor should be done by a pathologist with expertise in the diagnosis of CTCLs. Rebiopsy if pathologic findings are non-diagnostic and/or discordant with the clinical presentation
  - Adequate biopsy (by punch, incisional, or excisional) of all types of clinical lesions present will aid in final diagnosis
- Adequate immunophenotyping to establish diagnosis[b,c] on skin biopsy:
  - IHC panel may include: CD3, CD4, CD8, CD20, CD30, CD56, ALK[d]

USEFUL IN CERTAIN CIRCUMSTANCES:
- On skin biopsy, expanded IHC panel may include: CD2, CD5, CD7, CD25, TIA1, granzyme B, perforin, IRF4/MUM1, EMA, TCR beta, TCR delta
- EBER-ISH
- Molecular analysis to detect clonal *TRB* and *TRG* gene rearrangements or other assessment of clonality[a,e]
- FISH: *ALK* and *DUSP22* gene rearrangements[a]
- Excisional or incisional biopsy of suspicious LNs
- Assessment of HTLV-1/2 serology[f] is encouraged as results can impact therapy

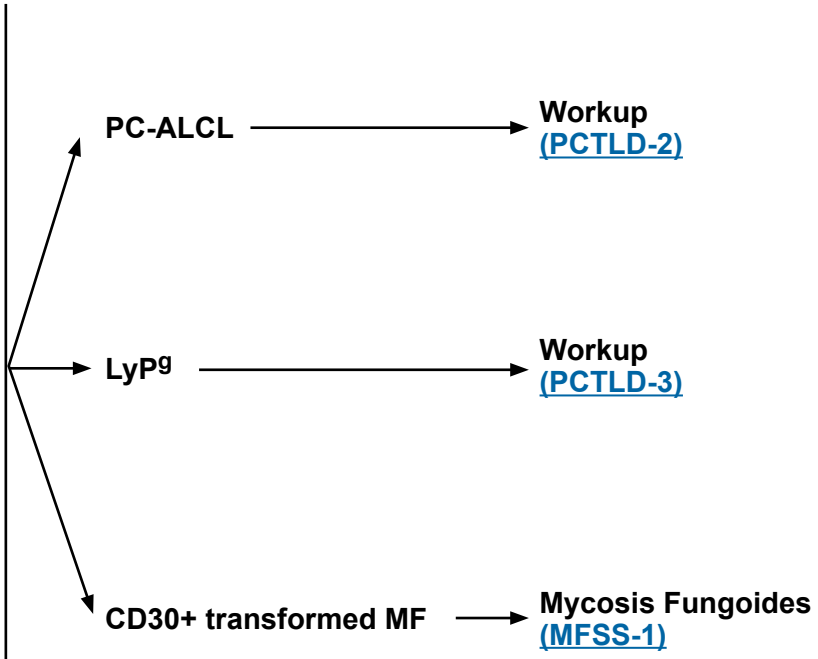

[a] Principles of Biomarker Testing in Cutaneous Lymphomas (PCLYM-B).
[b] Use of Immunophenotyping/Genetic Testing in Differential Diagnosis of NK/T-Cell Neoplasms (see NCCN Guidelines for T-Cell Lymphomas).
[c] Typical immunophenotype: CD30+ (>75% cells), CD4+ variable loss of CD2/CD5/CD3, CD8+ (<5%) cytotoxic granule proteins positive.
[d] ALK positivity and t(2;5) translocation is typically absent in PC-ALCL and LyP.
[e] Clonal *TRB* and *TRG* gene rearrangements alone are not sufficient for diagnosis, as these can also be seen in patients with non-malignant conditions. Results should be interpreted in the context of overall presentation. See Principles of Biomarker Testing in the NCCN Guidelines for T-Cell Lymphomas (TCLYM-A).
[f] See map for prevalence of HTLV-1/2 by geographic region. HTLV-1 has been described in patients in non-endemic areas.
[g] LyP is not considered a malignant disorder; however, there is an association with other lymphoid malignancy (MF or PC-ALCL). Staging studies are done in LyP only if there is suspicion of systemic involvement by an associated lymphoma.

Note: All recommendations are category 2A unless otherwise indicated.

Version 2.2026, 02/13/26 © 2026 National Comprehensive Cancer Network® (NCCN®), All rights reserved. NCCN Guidelines® and this illustration may not be reproduced in any form without the express written permission of NCCN.

PLEASE NOTE that use of this NCCN Content is governed by the End-User License Agreement, and you MAY NOT distribute this Content or use it with any artificial intelligence model or tool.
Printed by Galya Basol Kochav on 2/16/2026 9:44:21 AM. Copyright © 2026 National Comprehensive Cancer Network, Inc. All Rights Reserved.

WORKUP

PC-ALCL →

ESSENTIAL:
- History and complete physical examination including complete skin examination[h]; palpation of peripheral LN regions; liver or spleen enlargement
- CBC with differential
- Comprehensive metabolic panel
- LDH
- C/A/P CT with contrast or integrated whole body FDG-PET/CT (arms/legs included when disease assessment of entire body is needed)[i]
- Biopsy suspicious nodes[j,k,l]: Biopsy of enlarged LNs or suspected extracutaneous sites. Excisional or adequate core needle biopsy is preferred. An FNA biopsy alone is not sufficient for the initial diagnosis of lymphoma. Rebiopsy if consult material is nondiagnostic.
- Assess for distress[m]

USEFUL IN CERTAIN CIRCUMSTANCES
- Bone marrow aspiration and biopsy (optional for solitary cutaneous ALCL or cutaneous ALCL without extracutaneous involvement on imaging)
- Pregnancy testing in patients of childbearing potential if contemplating treatments that are contraindicated in pregnancy[n]
- Discuss fertility preservation[o]

→ **PC-ALCL** → PCTLD-4

→ **PC-ALCL with regional node** → PCTLD-4

→ **Systemic ALCL** → See NCCN Guidelines for T-Cell Lymphomas - Peripheral T-Cell Lymphomas (PTCL-1)

[h] Monitoring the size and number of lesions will assist with response assessment.
[i] Patients with T-cell lymphomas often have extranodal disease, which may be inadequately imaged by CT. FDG-PET scan may be preferred in these instances.
[j] Due to overlapping immunophenotype and morphology, need to use caution to avoid diagnosing CD30+ T-cell in LNs as Hodgkin lymphoma (Eberle FC, et al. Am J Surg Pathol 2012;36:716-725).
[k] Consider systemic ALCL, regional LN involvement with PC-ALCL, or LN involvement with transformed MF.
[l] Consider PC-ALCL if in draining LNs only.
[m] Refer to the NCCN Distress Thermometer and Problem List, which includes social determinants of health. See NCCN Guidelines for Distress Management (DIS-A).
[n] Many skin-directed and systemic therapies are contraindicated or are of unknown safety in pregnancy. Refer to individual drug information.
[o] Fertility preservation options include: sperm banking, IVF, or ovarian tissue or oocyte cryopreservation.

Note: All recommendations are category 2A unless otherwise indicated.

Version 2.2026, 02/13/26 © 2026 National Comprehensive Cancer Network® (NCCN®), All rights reserved. NCCN Guidelines® and this illustration may not be reproduced in any form without the express written permission of NCCN.

PLEASE NOTE that use of this NCCN Content is governed by the End-User License Agreement, and you MAY NOT distribute this Content or use it with any artificial intelligence model or tool.
Printed by Galya Basol Kochav on 2/16/2026 9:44:21 AM. Copyright © 2026 National Comprehensive Cancer Network, Inc. All Rights Reserved.

WORKUP

LyP[g] →

ESSENTIAL:
- **History and complete physical examination including complete skin examination[h]; palpation of peripheral LN regions; liver or spleen enlargement**
- **CBC with differential**
- **Comprehensive metabolic panel**
- **LDH**
- **Assess for distress[m]**

USEFUL IN CERTAIN CIRCUMSTANCES:
- **Pregnancy testing in patients of childbearing potential if contemplating treatments that are contraindicated in pregnancy[n]**
- **Discuss fertility preservation[o]**
- **C/A/P CT with contrast or integrated whole body FDG-PET/CT (arms/legs included when disease assessment of entire body is needed)[g,i,p] (not done for typical LyP)**
- **Neck CT with contrast if whole body FDG-PET/CT not done (not done for typical LyP)**
- **Bone marrow aspiration and biopsy (not done for typical LyP)[g,p]**

→ PCTLD-5

[g] LyP is not considered a malignant disorder; however, there is an association with other lymphoid malignancy (MF or PC-ALCL). Staging studies are done in LyP only if there is suspicion of systemic involvement by an associated lymphoma.
[h] Monitoring the size and number of lesions will assist with response assessment.
[i] Patients with T-cell lymphomas often have extranodal disease, which may be inadequately imaged by CT. FDG-PET scan may be preferred in these instances.
[m] Refer to the NCCN Distress Thermometer and Problem List, which includes social determinants of health. See NCCN Guidelines for Distress Management (DIS-A).
[n] Many skin-directed and systemic therapies are contraindicated or are of unknown safety in pregnancy. Refer to individual drug information.
[o] Fertility preservation options include: sperm banking, IVF, or ovarian tissue or oocyte cryopreservation.
[p] Only done to exclude an associated lymphoma.

Note: All recommendations are category 2A unless otherwise indicated.

Version 2.2026, 02/13/26 © 2026 National Comprehensive Cancer Network® (NCCN®), All rights reserved. NCCN Guidelines® and this illustration may not be reproduced in any form without the express written permission of NCCN.

PLEASE NOTE that use of this NCCN Content is governed by the End-User License Agreement, and you MAY NOT distribute this Content or use it with any artificial intelligence model or tool.
Printed by Galya Basol Kochav on 2/16/2026 9:44:21 AM. Copyright © 2026 National Comprehensive Cancer Network, Inc. All Rights Reserved.

NCCN Guidelines Version 2.2026
Primary Cutaneous CD30+ T-Cell Lymphoproliferative Disorders

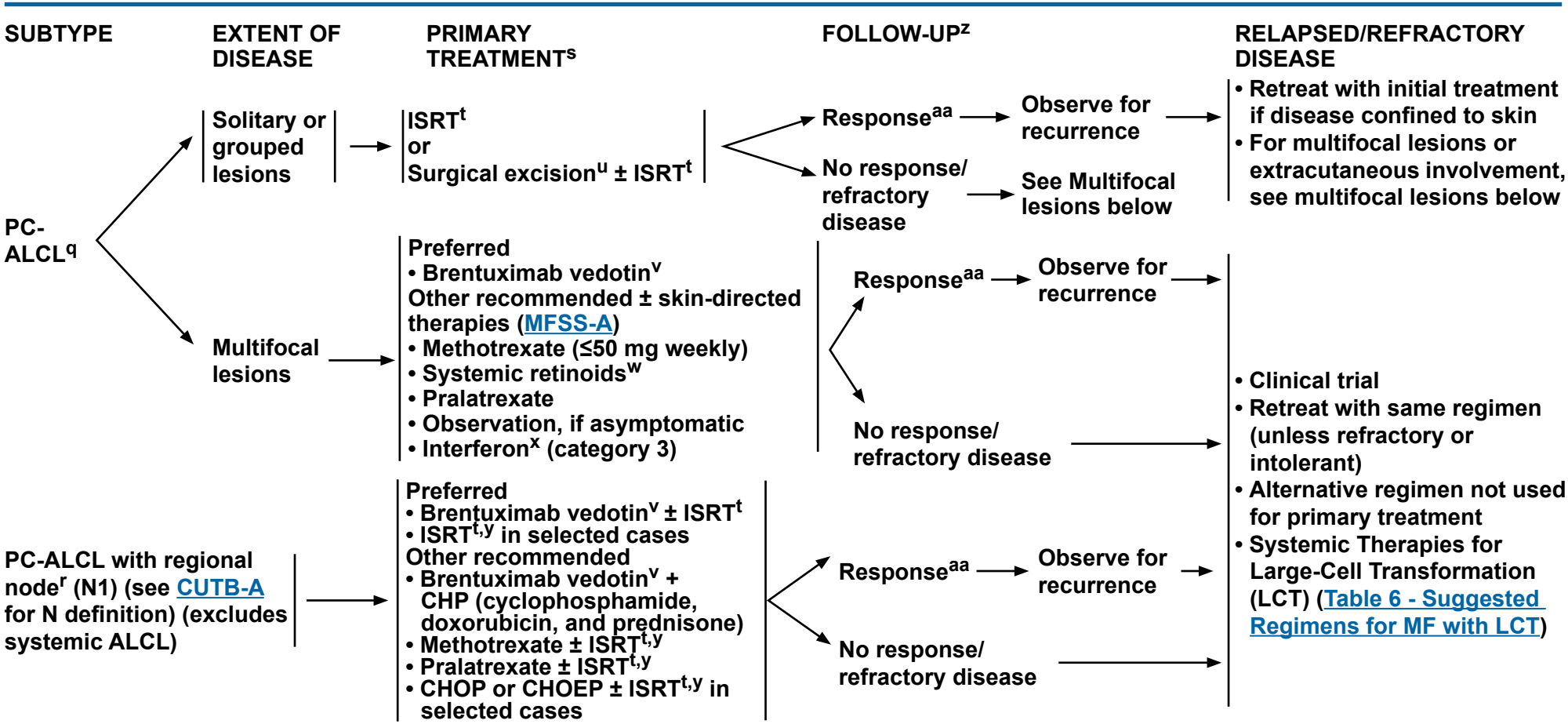

[q] Regression of lesions may occur in up to 44% of cases.
[r] Biopsy-proven lymphoma in LN.
[s] Therapy References (PCTLD-A).
[t] Principles of Radiation Therapy (PCLYM-A).
[u] Small lesions may be excised with minimal non-disfiguring surgery.
[v] Supportive Care (PCLYM-C).
[w] Limited data from case reports (eg, bexarotene).
[x] Peginterferon or ropeginterferon alfa-2b-njft (if peginterferon alfa-2a is unavailable) may be substituted for other interferon preparations (Schiller M, et al. J Eur Acad Dermatol Venerol 2017;31:1841-1847; Patsatsi A, et al. J Eur Acad Dermatol Venereol 2022;36:e291-e293; Osman S, et al. Dermatologic Therapy 2023;2023:7171937; Mesa R et al. Ann Hematol 2025;104:2571-2573).
[y] ISRT to include LN(s) ± primary skin lesions.
[z] MF can develop over time; continue to conduct thorough skin exam during follow-up.
[aa] Patients with a clinical benefit and/or those with disease responding to primary treatment should be considered for maintenance or tapering of regimens to optimize response duration. Relapsed disease often responds well to the same treatment. PR should be treated with other primary treatment options not received before to improve response before moving onto treatment for refractory disease. Patients with disease relapse or persistent disease after initial primary treatment may be candidates for clinical trials.

Note: All recommendations are category 2A unless otherwise indicated.

Version 2.2026, 02/13/26 © 2026 National Comprehensive Cancer Network® (NCCN®), All rights reserved. NCCN Guidelines® and this illustration may not be reproduced in any form without the express written permission of NCCN.

PLEASE NOTE that use of this NCCN Content is governed by the End-User License Agreement, and you MAY NOT distribute this Content or use it with any artificial intelligence model or tool.
Printed by Galya Basol Kochav on 2/16/2026 9:44:21 AM. Copyright © 2026 National Comprehensive Cancer Network, Inc. All Rights Reserved.

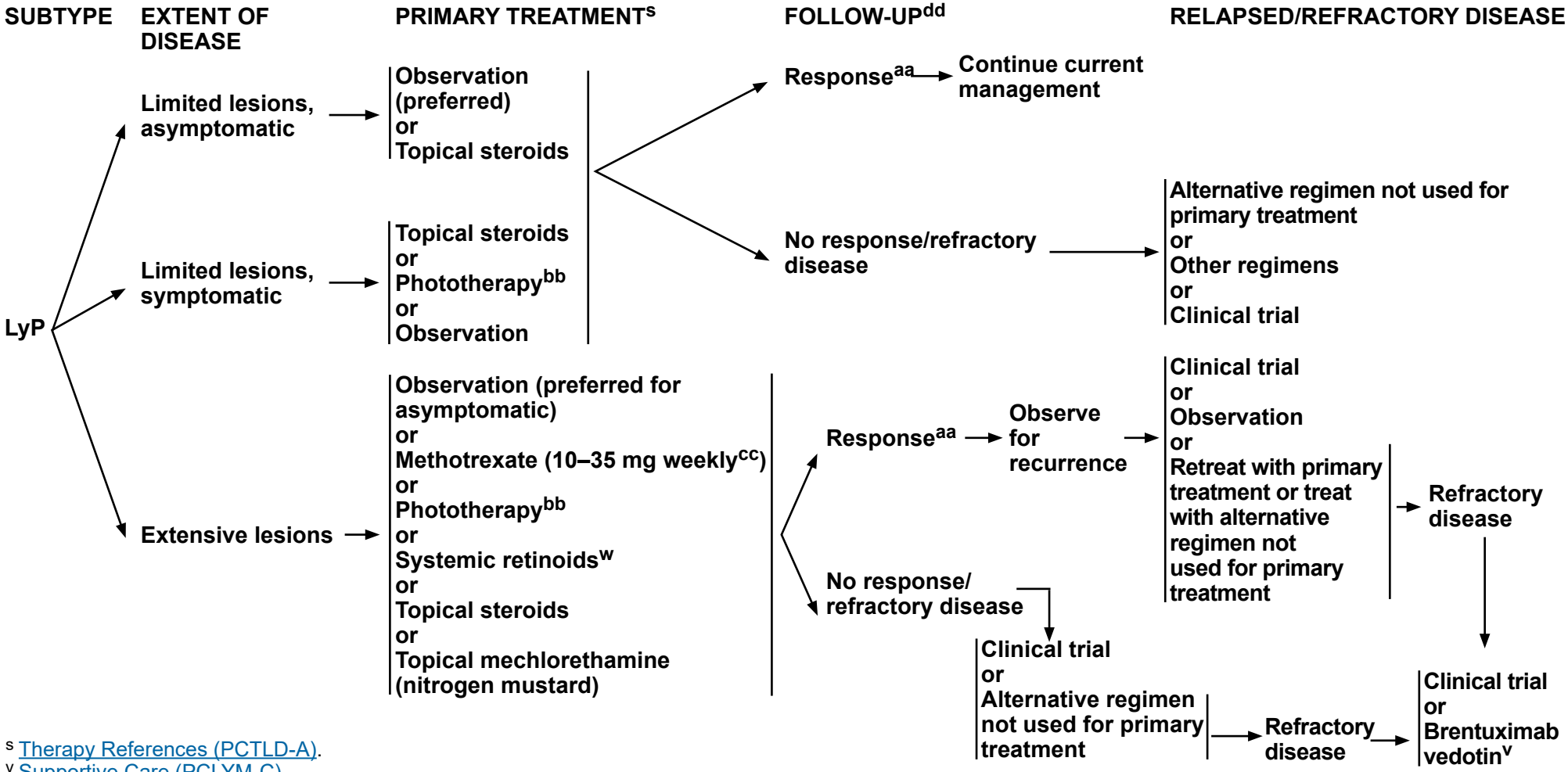

s Therapy References (PCTLD-A).
v Supportive Care (PCLYM-C).
w Limited data from case reports (eg, bexarotene).
aa Patients with a clinical benefit and/or those with disease responding to primary treatment should be considered for maintenance or tapering of regimens to optimize response duration. Relapsed disease often responds well to the same treatment. PR should be treated with other primary treatment options not received before to improve response before moving onto treatment for refractory disease. Patients with disease relapse or persistent disease after initial primary treatment may be candidates for clinical trials.
bb NB-UVB is generally preferred over PUVA.
cc Kempf W, et al. Blood 2011;118:4024-4035.
dd Life-long follow-up is warranted due to high risk for second lymphoid malignancies; continue to conduct thorough skin exam during follow-up.

Note: All recommendations are category 2A unless otherwise indicated.

Version 2.2026, 02/13/26 © 2026 National Comprehensive Cancer Network® (NCCN®), All rights reserved. NCCN Guidelines® and this illustration may not be reproduced in any form without the express written permission of NCCN.

PLEASE NOTE that use of this NCCN Content is governed by the End-User License Agreement, and you MAY NOT distribute this Content or use it with any artificial intelligence model or tool.
Printed by Galya Basol Kochav on 2/16/2026 9:44:21 AM. Copyright © 2026 National Comprehensive Cancer Network, Inc. All Rights Reserved.

THERAPY REFERENCES

Skin-Directed Therapies

Topical steroids

Paul MA, Krowchuk DP, Hitchcock MG, Jorizzo JL. Lymphomatoid papulosis: successful weekly pulse superpotent topical corticosteroid therapy in three pediatric patients. Pediatr Dermatol 1996;13:501-506.

Phototherapy

Wantzin GL, Thomsen K. PUVA-treatment in lymphomatoid papulosis. Br J Dermatol 1982;107:687-690.

Topical nitrogen mustard

Vonderheid EC, Tan ET, Kantor AF, et al. Long-term efficacy, curative potential, and carcinogenicity of topical mechlorethamine chemotherapy in cutaneous T cell lymphoma. J Am Acad Dermatol 1989;20:416-428.

Radiation therapy

Million L, Yi EJ, Wu F, et al. Radiation therapy for primary cutaneous anaplastic large cell lymphoma: An International Lymphoma Radiation Oncology Group Multi-institutional Experience. Int J Radiat Oncol Biol Phys 2016;95:1454-1459.

Specht L, Dabaja B, Illidge T, et al. Modern radiation therapy for primary cutaneous lymphomas: field and dose guidelines from the International Lymphoma Radiation Oncology Group. Int J Radiat Oncol Biol Phys 2015;92:32-39.

Smith GL, Duvic M, Yehia ZA, et al. Effectiveness of low-dose radiation for primary cutaneous anaplastic large cell lymphoma. Adv Radiat Oncol 2017;2:363-369.

Systemic Therapies

Brentuximab vedotin

Prince HM, Kim YH, Horwitz SM, et al. Brentuximab vedotin or physician's choice in CD30-positive cutaneous T-cell lymphoma (ALCANZA): an international, open-label, randomised, phase 3, multicentre trial. Lancet 2017;390:555-566.

Duvic M, Tetzlaff MT, Gangar P, et al. Results of a phase II trial of brentuximab vedotin for CD30+ cutaneous T-cell lymphoma and lymphomatoid papulosis. J Clin Oncol 2015;33:3759-3765.

Lewis DJ, Talpur R, Huen AO, et al. Brentuximab vedotin for patients with refractory lymphomatoid papulosis: An analysis of phase 2 results. JAMA Dermatol 2017;153:1302-1306.

Brentuximab vedotin + CHP (cyclophosphamide, doxorubicin, and prednisone)

Horwitz S, O'Connor OA, Pro B, et al. Brentuximab vedotin with chemotherapy for CD30-positive peripheral T-cell lymphoma (ECHELON-2): a global, double-blind, randomised, phase 3 trial. Lancet 2019;393:229-240.

Systemic Therapies (continued)

Interferons

Proctor SJ, Jackson GH, Lennard AL, Marks J. Lymphomatoid papulosis: response to treatment with recombinant interferon alfa-2b. J Clin Oncol 1992;10:170.

Schmuth M, Topar G, Illersperger B, et al. Therapeutic use of interferon-alpha for lymphomatoid papulosis. Cancer 2000;89:1603-1610.

Methotrexate

Everett MA. Treatment of lymphomatoid papulosis with methotrexate. Br J Dermatol 1984;111:631.

Vonderheid EC, Sajjadian A, Kaden ME. Methotrexate is effective for lymphomatoid papulosis and other primary cutaneous CD30+ lymphoproliferative disorders. J Am Acad Dermatol 1996;34:470-481.

Fujita H, Nagatani T, Miyazawa M, et al. Primary cutaneous anaplastic large cell lymphoma successfully treated with low-dose methotrexate. Eur J Dermatol 2008;18:360-361.

Pralatrexate

Horwitz SM, Kim YH, Foss F, et al. Identification of an active, well-tolerated dose of pralatrexate in patients with relapsed or refractory cutaneous T-cell lymphoma. Blood 2012;119:4115-4122.

Systemic retinoids

Nakamura S, Hashimoto Y, Nishi K, et al. Primary cutaneous CD30+ lymphoproliferative disorder successfully treated with etretinate. Eur J Dermatol 2012;22:709-710.

Krathen RA, Ward S, Duvic M. Bexarotene is a new treatment option for lymphomatoid papulosis. Dermatology 2003;206:142-147.

Wyss M, Dummer R, Dommann SN, et al. Lymphomatoid papulosis--treatment with recombinant interferon alfa-2a and etretinate. Dermatology 1995;190:288-291.

Sheehy JM, Catherwood M, Pettengell R, Morris TCC. Sustained response of primary cutaneous CD30+ anaplastic large cell lymphoma to bexarotene and photopheresis. Leuk Lymphoma 2009;50:1389-1391.

Note: All recommendations are category 2A unless otherwise indicated.

Version 2.2026, 02/13/26 © 2026 National Comprehensive Cancer Network® (NCCN®), All rights reserved. NCCN Guidelines® and this illustration may not be reproduced in any form without the express written permission of NCCN.

PLEASE NOTE that use of this NCCN Content is governed by the End-User License Agreement, and you MAY NOT distribute this Content or use it with any artificial intelligence model or tool.
Printed by Galya Basol Kochav on 2/16/2026 9:44:21 AM. Copyright © 2026 National Comprehensive Cancer Network, Inc. All Rights Reserved.

PRINCIPLES FOR SUBCUTANEOUS PANNICULITIS-LIKE T-CELL LYMPHOMA (SPTCL)

- **There is only modest evidence for the management of SPTCL. The following guidelines are based on expert consensus. Treatment options are based on the presence of HLH and tumor burden as outlined in SPTCL-2 and SPTCL-3.**
- **SPTCL is a very rare condition characterized by mature, medium-size, CD8+ activated T cells with tropism towards adipocytes in the subcutaneous tissue and in extraordinary cases involving adipocytes at other sites, like mesentery.**
- **Patients with SPTCL tend to be young, often with a personal or family history of SLE or other autoimmune disorders.**
- **The presentation includes non-ulcerated deep nodules typically involving legs and other sites. The process may resolve with areas of lipodystrophy and hyperpigmentation.**
- **Fever and malaise are commonly observed at presentation. Signs and symptoms of hemophagocytic lymphohistiocytosis (HLH) may occasionally lead to severe morbidity or mortality. Markers of HLH should be checked when SPTCL is suspected with ferritin levels as a reliable marker to assess disease evolution (see NCCN Guidelines for T-Cell Lymphomas (TCLYM-F).**
- **Rimming of bone marrow adipocytes by CD8+ T cells may be observed, but tumoral growth in nodal, bone marrow, or mesenchymal organs is not typically seen. This limited growth potential, along with the lack of common lymphoma driver mutations and the frequent detection of germline mutations in the *HAVCR2* gene, suggests an immune dysregulation characterized by unchecked activated T cells driving the process. *HAVCR2* encodes for T-cell immunoglobulin and mucin domain protein 3 (TIM-3), a membrane modulator of immune response resulting in hemophagocytosis and uncontrolled activation of the innate immune system. *HAVCR2* mutations appear to be more prevalent in patients of Asian ancestry.**

Note: All recommendations are category 2A unless otherwise indicated.

Version 2.2026, 02/13/26 © 2026 National Comprehensive Cancer Network® (NCCN®), All rights reserved. NCCN Guidelines® and this illustration may not be reproduced in any form without the express written permission of NCCN.

PLEASE NOTE that use of this NCCN Content is governed by the End-User License Agreement, and you MAY NOT distribute this Content or use it with any artificial intelligence model or tool.
Printed by Galya Basol Kochav on 2/16/2026 9:44:21 AM. Copyright © 2026 National Comprehensive Cancer Network, Inc. All Rights Reserved.

DIAGNOSIS[a]

ESSENTIAL:
- Deep subcutaneous skin biopsy with adequate amount of adipose tissue (wedge excision or deep telescope punch biopsy) of clinical lesions:
  - Multiple biopsies may be necessary to confirm diagnosis
  - Review of a sufficient number of slides with adequate material to perform a comprehensive workup as described below and/or at least one paraffin block representative of the tumor should be done by a pathologist with expertise in the diagnosis of CTCLs. Rebiopsy if pathologic findings are non-diagnostic and/or discordant with the clinical presentation
- Adequate immunophenotyping to establish diagnosis[b]
  - IHC panel may include: TCR beta, TCR delta, CD2, CD3, CD20, CD4, CD5, CD7, CD8, CD30, CD56
- EBER-ISH
- Molecular analysis to detect clonal *TRB* and *TRG* gene rearrangements or other assessment of clonality

USEFUL UNDER CERTAIN CIRCUMSTANCES:
- Additional IHC markers may include: Ki-67, CD123, TIA1, perforin, granzyme-B, CD1a, TdT, TCL1
- Consider peripheral blood flow cytometry to rule out other T-cell lymphoma subtypes
- Germline testing for *HAVCR2* mutation
- MGPT

→

WORKUP

ESSENTIAL:
- History and complete physical examination:
  - Complete skin examination
  - Palpation of peripheral LN regions
  - Palpation for organomegaly/masses
  - Potential triggers for recent infections
  - Personal or family history of autoimmunity, consanguinity, ancestry, etc.
- CBC with differential
- Comprehensive metabolic panel
- LDH, ferritin
- HLH workup if B symptoms or HLH is suspected (see NCCN Guidelines for T-Cell Lymphomas [TCLYM-F])
- Whole body FDG-PET/CT scan[c] to assess the extent of extracutaneous involvement
- Assess for distress[d]

USEFUL UNDER CERTAIN CIRCUMSTANCES:
- Pregnancy testing in patients of childbearing potential if contemplating treatments that are contraindicated in pregnancy
- Consider quantitative Epstein-Barr virus (EBV) polymerase chain reaction (PCR)
- Antinuclear antibody (ANA) with reflex, rheumatoid factor (RF), TSH, and primary immunodeficiency (PID) gene panel to rule out other autoimmune conditions that closely resemble SPTCL
- Consider bone marrow biopsy, if unexplained cytopenias or HLH
- Consider biopsy of enlarged LNs or other suspected FDG-PET–avid extracutaneous sites

→ SPTCL-2

[a] Borderline or low-grade presentations that may overlap with lupus panniculitis and evolve into SPTCL (eg, adipotropic LPD; necrotizing, infectious, or granulomatous panniculitis; other cutaneous lymphomas [primary cutaneous gamma-delta T-cell lymphoma, primary cutaneous natural killer T-cell lymphoma (NKTL), or PTCL]) should be included in the differential diagnosis.
[b] Typical immunophenotype: CD3+ CD8+ betaF1+ CD2+ CD5+ CD7+.
[c] Patients have extranodal disease, which may be inadequately imaged by CT. PET scan is preferred.
[d] Refer to the NCCN Distress Thermometer and Problem List, which includes social determinants of health. See NCCN Guidelines for Distress Management (DIS-A).

Note: All recommendations are category 2A unless otherwise indicated.

Version 2.2026, 02/13/26 © 2026 National Comprehensive Cancer Network® (NCCN®), All rights reserved. NCCN Guidelines® and this illustration may not be reproduced in any form without the express written permission of NCCN.

PLEASE NOTE that use of this NCCN Content is governed by the End-User License Agreement, and you MAY NOT distribute this Content or use it with any artificial intelligence model or tool.
Printed by Galya Basol Kochav on 2/16/2026 9:44:21 AM. Copyright © 2026 National Comprehensive Cancer Network, Inc. All Rights Reserved.

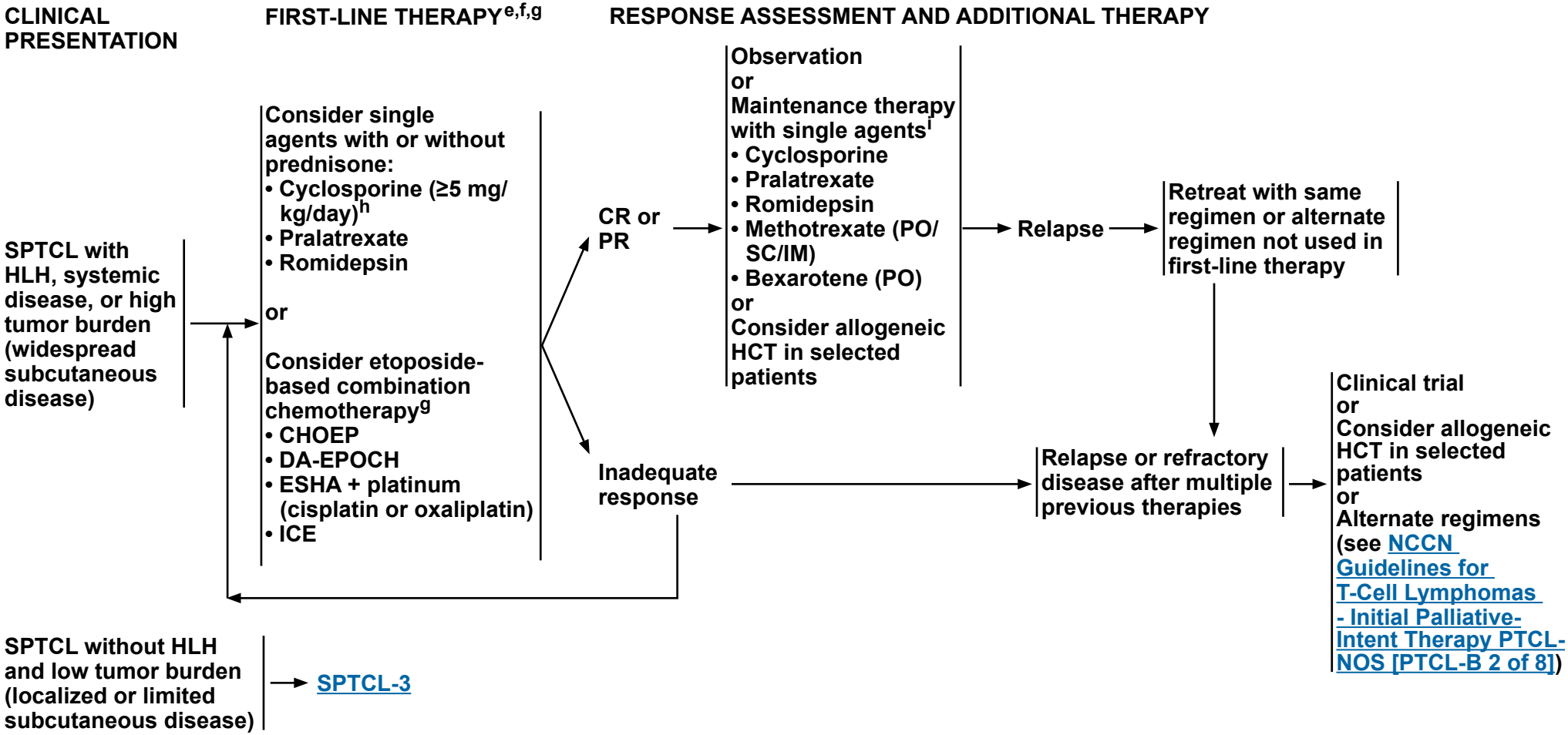

[e] Consider ISRT for single lesion or limited disease with or without symptoms or HLH.
[f] Start with etoposide-based regimens to control HLH first and then move to disease-specific therapies.
[g] Consider etoposide-based combination regimens for patients eligible for transplant.
[h] Oral cyclosporine is typically initiated at 3–5 mg/kg/day in divided doses. Higher dosage may be necessary to achieve disease control. Dose adjustment is based on response and tolerance. In patients with disease responding to first-line therapy, consider slow tapering as tolerated or cyclosporine maintenance.
[i] Patients with disease achieving a clinical benefit and/or those with disease responding to first-line therapy should be considered for maintenance or tapering of regimens to optimize response duration.

Note: All recommendations are category 2A unless otherwise indicated.

Version 2.2026, 02/13/26 © 2026 National Comprehensive Cancer Network® (NCCN®), All rights reserved. NCCN Guidelines® and this illustration may not be reproduced in any form without the express written permission of NCCN.

PLEASE NOTE that use of this NCCN Content is governed by the End-User License Agreement, and you MAY NOT distribute this Content or use it with any artificial intelligence model or tool.
Printed by Galya Basol Kochav on 2/16/2026 9:44:21 AM. Copyright © 2026 National Comprehensive Cancer Network, Inc. All Rights Reserved.

NCCN Guidelines Version 2.2026
Subcutaneous Panniculitis-Like T-Cell Lymphoma

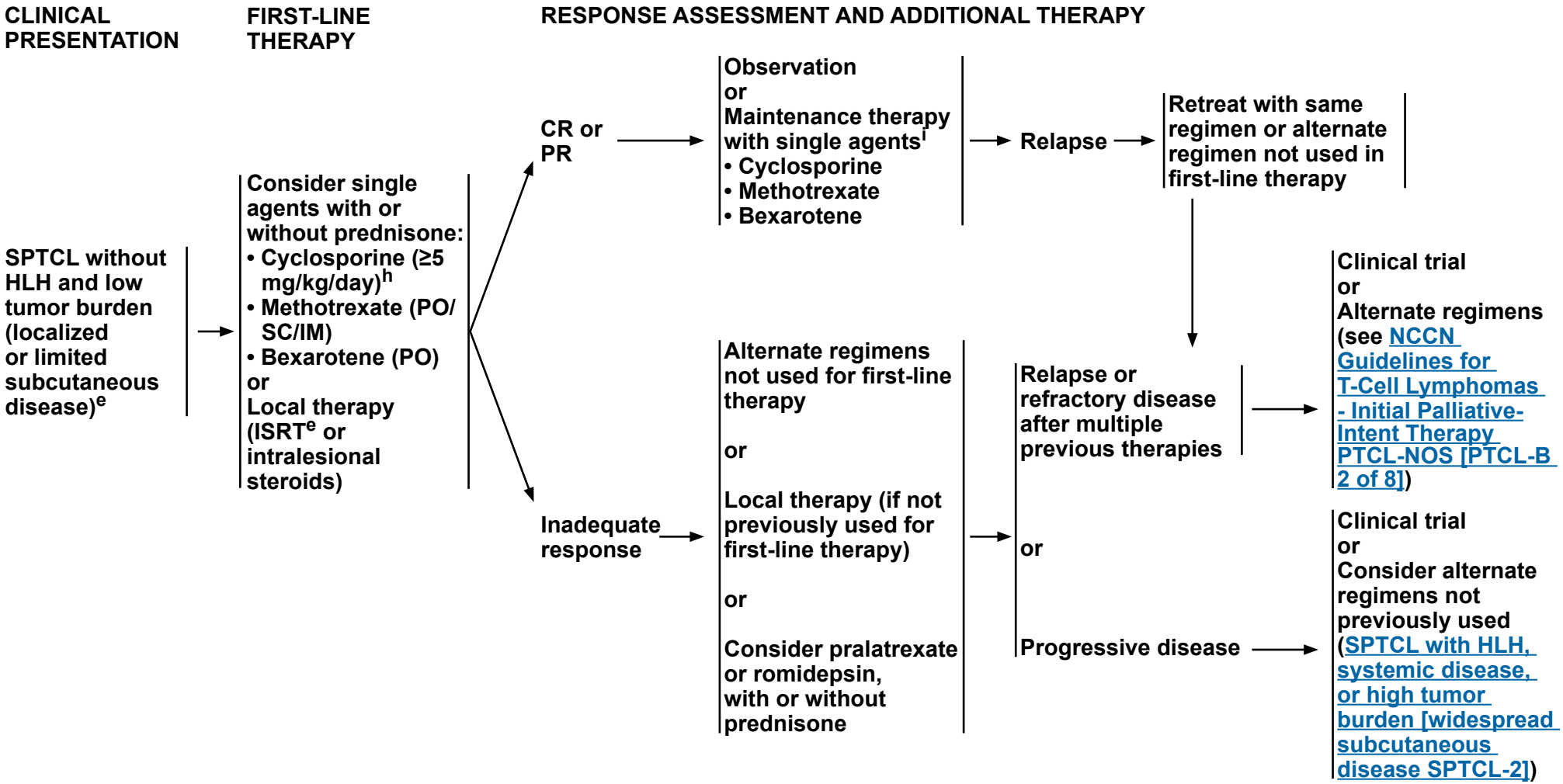

[e] Consider ISRT for single lesion or limited disease with or without symptoms or HLH.
[h] Oral cyclosporine is typically initiated at 3–5 mg/kg/day in divided doses. Higher dosage may be necessary to achieve disease control. Dose adjustment is based on response and tolerance. In patients with disease responding to first-line therapy, consider slow tapering as tolerated or cyclosporine maintenance.
[i] Patients with disease achieving a clinical benefit and/or those with disease responding to first-line therapy should be considered for maintenance or tapering of regimens to optimize response duration.

Note: All recommendations are category 2A unless otherwise indicated.

Version 2.2026, 02/13/26 © 2026 National Comprehensive Cancer Network® (NCCN®), All rights reserved. NCCN Guidelines® and this illustration may not be reproduced in any form without the express written permission of NCCN.

PLEASE NOTE that use of this NCCN Content is governed by the End-User License Agreement, and you MAY NOT distribute this Content or use it with any artificial intelligence model or tool.
Printed by Galya Basol Kochav on 2/16/2026 9:44:21 AM. Copyright © 2026 National Comprehensive Cancer Network, Inc. All Rights Reserved.

PRIMARY CUTANEOUS INDOLENT LYMPHOPROLIFERATIVE DISORDERS (LPD)

Definition and Clinical Presentation

- **Primary cutaneous indolent LPD were previously classified as primary cutaneous lymphomas, but due to their excellent prognosis, and the absence of extracutaneous progression, they have been re-classified as LPD by both 2022 WHO classification and ICC classifications.[1-4] They should be distinguished from malignant CTCL.**
- **The primary cutaneous indolent LPDs include primary cutaneous CD4+ small/medium T-cell LPD (PCSM-TLPD)[5] and primary cutaneous CD8+ acral T-cell LPD (PCA-TLPD).[6] See Table 1.**
  - **PCSM-TLPD and PCA-TLPD commonly have a clonal T-cell population by *TCR* gene rearrangement studies.**
  - **PCSM-TLPD typically show a CD4+ T-follicular helper (TFH) phenotype while PCA-TLPD expresses CD8 and a cytotoxic phenotype.**
  - **Both PCSM-TLPD and PCA-TLPD present with isolated nodules or plaques with frequent spontaneous regression after biopsy.**
  - **Differential diagnosis includes other reactive and neoplastic lymphoid proliferations but most importantly they need to be distinguished from solitary presentation of MF, a subset of primary cutaneous CD30+ T-cell LPDs, and primary or secondary involvement by PTCL-NOS.**
  - **In cases that are not behaving indolently (for example, with generalized skin lesions, rapidly growing tumors, or loss of pan T-cell markers), alternative diagnoses such as cutaneous manifestations of PTCL should be considered.**

Treatment Principles

- **Aggressive treatment is not needed for confirmed cases of primary cutaneous indolent LPD.**
- **Imaging can be considered as part of the diagnostic workup (to exclude systemic lymphoma) for cases in which cutaneous manifestation of a systemic lymphoma is considered clinically. Further surveillance imaging is not needed for confirmed cases of primary cutaneous indolent LPD.**
- **Clinical observation, topical or intralesional steroids, low-dose RT, or surgical excision can be considered for symptomatic patients.**
- **Systemic therapy is usually not needed and frequently can be avoided.**

References on INCTLD-2A

Note: All recommendations are category 2A unless otherwise indicated.

Version 2.2026, 02/13/26 © 2026 National Comprehensive Cancer Network® (NCCN®), All rights reserved. NCCN Guidelines® and this illustration may not be reproduced in any form without the express written permission of NCCN.

PLEASE NOTE that use of this NCCN Content is governed by the End-User License Agreement, and you MAY NOT distribute this Content or use it with any artificial intelligence model or tool.
Printed by Galya Basol Kochav on 2/16/2026 9:44:21 AM. Copyright © 2026 National Comprehensive Cancer Network, Inc. All Rights Reserved.

PRIMARY CUTANEOUS INDOLENT LYMPHOPROLIFERATIVE DISORDERS (LPD)

Table 1. Clinical/Histologic Features, Diagnosis, Prognosis, and Staging[5]

Disease	PCSM-TLPD (WHO/ICC)	PCA-TLPD (WHO/ICC)
Clinical Features	Solitary asymptomatic nodule or plaque; common locations are head and neck, trunk, or upper extremities No extracutaneous progression	Solitary asymptomatic papule, nodule, or plaque; common locations are ear, nose, or other acral sites No extracutaneous progression
Histologic Features	Superficial band-like or nodular/diffuse infiltrate of predominantly small/medium-sized CD4+ T cells Can have reactive infiltrate of many admixed CD8+ T cells, B cells, plasma cells, and histiocytes including multinucleated giant cells	Dermal, non-epidermotropic, diffuse or nodular infiltrate of atypical medium-sized CD8+ T cells
Immunophenotype	CD3+, CD4+, CD8-, CD10-, PD-1+, ICOS+, BCL6-/+, CXCL13-/+, TCR alpha/beta	CD3+, CD4-, CD8+, TIA+, Granzyme B+/-, dot like expression of CD68 in tumor cells, TCR alpha/beta, EBV negative
TCR Clonality	Clonal *TRB/TRG* gene rearrangements in most cases; sometimes concomitant clonal *Ig* gene rearrangements also present	Clonal *TRB/TRG* gene rearrangements in most cases
Prognosis	5-year OS rate of 100%; relapse is rare	5-year OS rate of 100%; relapse is uncommon
Spontaneous Remission	Common	Less common but can occur
Staging	Physical exam of skin and palpation of LNs; other staging recommendations may not be required with typical clinical and histologic presentation	Physical exam of skin and palpation of LNs; other staging recommendations may not be required with typical clinical and histologic presentation

References on INCTLD-2A

Note: All recommendations are category 2A unless otherwise indicated.

Version 2.2026, 02/13/26 © 2026 National Comprehensive Cancer Network® (NCCN®), All rights reserved. NCCN Guidelines® and this illustration may not be reproduced in any form without the express written permission of NCCN.

PLEASE NOTE that use of this NCCN Content is governed by the End-User License Agreement, and you MAY NOT distribute this Content or use it with any artificial intelligence model or tool.
Printed by Galya Basol Kochav on 2/16/2026 9:44:21 AM. Copyright © 2026 National Comprehensive Cancer Network, Inc. All Rights Reserved.

PRIMARY CUTANEOUS INDOLENT LYMPHOPROLIFERATIVE DISORDERS (LPD)

REFERENCES

[1] WHO Classification of Tumours Editorial Board. Haematolymphoid tumours. (WHO classification of tumours series, 5th ed.; vol. 11). Lyon (France): International Agency for Research on Cancer; 2024.
[2] Arber DA, Borowitz MJ, Cook JR, et al. The International Consensus Classification of Myeloid and Lymphoid Neoplasms. 1st ed. Philadelphia, PA: Lippincott Williams & Wilkins; 2025.
[3] Kempf W, Mitteldorf C, Cerroni L, et al. Classifications of cutaneous lymphomas and lymphoproliferative disorders: An update from the EORTC cutaneous lymphoma histopathology group. J Eur Acad Dermatol Venereol 2024;38:1491-1503.
[4] Willemze R, Assaf C, Bagot M, et al. EORTC/USCLC/ISCL consensus recommendations for management and treatment of cutaneous lymphoproliferative disorders. Br J Dermatol 2025:Online ahead of print.
[5] Surmanowicz P, Doherty S, Sivanand A, et al. The clinical spectrum of primary cutaneous CD4+ small/medium-sized pleomorphic T-cell lymphoproliferative disorder: An updated systematic literature review and case series. Dermatology 2021;237:618-628.
[6] Kempf W, Petrella T, Willemze R, et al. Clinical, histopathological and prognostic features of primary cutaneous acral CD8+ T-cell lymphoma and other dermal CD8+ cutaneous lymphoproliferations: results of an EORTC Cutaneous Lymphoma Group workshop. Br J Dermatol 2022;186:887-897.

Note: All recommendations are category 2A unless otherwise indicated.

Version 2.2026, 02/13/26 © 2026 National Comprehensive Cancer Network® (NCCN®), All rights reserved. NCCN Guidelines® and this illustration may not be reproduced in any form without the express written permission of NCCN.

PLEASE NOTE that use of this NCCN Content is governed by the End-User License Agreement, and you MAY NOT distribute this Content or use it with any artificial intelligence model or tool.
Printed by Galya Basol Kochav on 2/16/2026 9:44:21 AM. Copyright © 2026 National Comprehensive Cancer Network, Inc. All Rights Reserved.

PRINCIPLES OF RADIATION THERAPY[a]

General Principles

- The general intent of RT is to treat the evident skin disease with adequate margin both circumferentially and in depth.
- External beam RT (EBRT) with photons, electrons, or low-energy x-rays may all be appropriate, depending on clinical circumstances.

Target Volumes

- ISRT for cutaneous lesions:
  - ISRT is recommended as the appropriate field for treating primary cutaneous lymphomas.
  - Planning to define the clinical target volume (CTV) may often only require a careful physical exam. However, when the depth of disease is not evident or when disease extends around curved surfaces, treatment planning may be facilitated by ultrasound imaging or CT-based simulation and planning. Incorporating other modern imaging like PET and MRI may enhance treatment volume determination in some cases.
  - ISRT targets the site of skin involvement. The volume encompasses the clinically evident disease with adequate margins.
  - The visible or palpable disease defines the gross tumor volume (GTV) and provides the basis for determining the CTV. If using CT-based planning, delineating tumor boundary with wire for CT simulation will guide treatment volumes. Concerns for questionable subclinical disease and uncertainties in original imaging accuracy or localization will lead to expansion of the CTV and are determined individually using clinical judgment but generally include a margin of 1–2 cm both circumferentially and in depth. The CTV need not be expanded into intact bone.
  - The planning target volume (PTV) is an additional expansion of the CTV that accounts only for setup variations (see International Commission on Radiation Units and Measurements [ICRU] definitions).
  - The treatment plan is designed using conventional or three-dimensional (3D) conformal techniques using clinical treatment planning considerations of coverage and dose reductions for organ at risk (OAR).
- ISRT for nodal disease:
  - NCCN Guidelines for T-Cell Lymphomas – Principles of Radiation Therapy (Target Volumes: ISRT for nodal disease).
  - NCCN Guidelines for B-Cell Lymphomas – Principles of Radiation Therapy (Target Volumes: ISRT for nodal disease).

- Radiation Dose Constraints – Recommendations for normal tissue dose constraints can be found in the NCCN Guidelines for Hodgkin Lymphoma – Principles of Radiation Therapy

[a] References on PCLYM-A 3 of 3.

Note: All recommendations are category 2A unless otherwise indicated.

Version 2.2026, 02/13/26 © 2026 National Comprehensive Cancer Network® (NCCN®), All rights reserved. NCCN Guidelines® and this illustration may not be reproduced in any form without the express written permission of NCCN.

PLEASE NOTE that use of this NCCN Content is governed by the End-User License Agreement, and you MAY NOT distribute this Content or use it with any artificial intelligence model or tool.
Printed by Galya Basol Kochav on 2/16/2026 9:44:21 AM. Copyright © 2026 National Comprehensive Cancer Network, Inc. All Rights Reserved.

PRINCIPLES OF RADIATION THERAPY[a]

General Dose Guidelines: (RT in conventional fraction sizes)

- **PCMZL and PCFCL:**
  - **Optimal initial management for solitary/regional disease is with 24 Gy EBRT. Alternatively, lower doses (eg, 4 Gy) may be used initially, with supplemental RT (4–20 Gy) for inadequate response or subsequent local relapse though data with this approach are limited.**
    - **Surface margins beyond area of clinically evident disease will vary depending on lesion size and body site and must take into account dosimetry of the beam being used. Surface margins of 1.0–1.5 cm are generally adequate.**
    - **Margins in depth should include the volume at risk for involvement.**
    - **Generally, treatment with 6–9 MeV electrons (with surface bolus) provides an adequate depth of treatment. Alternatively, low-energy x-rays (~100 Kv) may be used.**
    - **Doses as low as 4 Gy are used occasionally, but data are limited regarding response and duration.**
  - **RT for relapsed disease: 4 Gy EBRT may be adequate.**

- **MF/SS**
  - **Treatment of individual patches, plaques, or tumors**
    - **Optimal management for individual plaque and tumor lesions is with EBRT. Low-dose local RT (8–12 Gy) is given with palliative intent (usually as combined modality therapy). Some Member Institutions are exploring the use of lower dose options (eg, 4 Gy). Up to 8 Gy can be given in a single fraction, although lower dose per fraction (3–5 Gy) may be preferred depending on skin condition, irradiation volume, and prior RT.**
    - **For unilesional MF at initial presentation, the definitive RT dose is 24–30 Gy.**
    - **Surface margins beyond area of clinically evident disease will vary depending on lesion size and body site and must take into account dosimetry of the beam being used. Surface margins of 1.0–1.5 cm are generally adequate.**
    - **Margins in depth should include the volume at risk for involvement.**
    - **Generally, treatment with 6–9 MeV electrons (with surface bolus) provides an adequate depth of treatment. Alternatively, low-energy x-rays (~100 Kv) may be used.**
    - **For certain body surfaces, higher energy photon fields and opposed-field treatment (with bolus) may be required.**
  - **TSEBT**
    - **A variety of techniques may be utilized to cover the entire cutaneous surface. Patients are generally treated in the standing position on a rotating platform or with multiple body positions to ensure total skin coverage.**
    - **The common dose is ~12 Gy, generally 4–6 Gy per week. Higher doses (24–36 Gy) have been used for more extensive or refractory disease. The advantages of a lower dose include fewer short-term complications and better ability to retreat for relapsed disease.**
    - **“Shadowed” areas may need to be supplemented with individual electron fields.**
    - **Individual tumors may be boosted with doses of 4–12 Gy.**
    - **For patients with recalcitrant sites after generalized skin treatment, additional local treatment may be needed.**

[a] References on PCLYM-A 3 of 3.

Note: All recommendations are category 2A unless otherwise indicated.

Version 2.2026, 02/13/26 © 2026 National Comprehensive Cancer Network® (NCCN®), All rights reserved. NCCN Guidelines® and this illustration may not be reproduced in any form without the express written permission of NCCN.

PLEASE NOTE that use of this NCCN Content is governed by the End-User License Agreement, and you MAY NOT distribute this Content or use it with any artificial intelligence model or tool.
Printed by Galya Basol Kochav on 2/16/2026 9:44:21 AM. Copyright © 2026 National Comprehensive Cancer Network, Inc. All Rights Reserved.

PRINCIPLES OF RADIATION THERAPY

General Dose Guidelines: (RT in conventional fraction sizes) (continued)

- **PC-ALCL:**
  - **RT for curative treatment: 24 Gy**
  - **Doses as low as 6 Gy are used at some Member Institutions, but data are limited regarding response and duration.**
  - **Palliative RT: 2 Gy x 2 or 4 Gy x 1**

- **SPTCL**
  - **RT for curative treatment: Adequate dose is uncertain; consensus organizations recommend up to 40 Gy**

REFERENCES

Akhtari M, Reddy JP, Pinnix CC, et al. Primary cutaneous B-cell lymphoma (non-leg type) has excellent outcomes even after very low dose radiation as single-modality therapy. Leuk Lymphoma 2016;57:34-38.

Goyal A, Carter JB, Pashtan I, et al. Very low-dose versus standard dose radiation therapy for indolent primary cutaneous B-cell lymphomas: A retrospective study. J Am Acad Dermatol 2018;78:408-410.

Hoppe RT, Harrison C, Tavallaee M, et al. Low-dose total skin electron beam therapy as an effective modality to reduce disease burden in patients with mycosis fungoides: results of a pooled analysis from 3 phase-II clinical trials. J Am Acad Dermatol 2015;72:286-292.

Million L, Yi EJ, Wu F, et al. Radiation therapy for primary cutaneous anaplastic large cell lymphoma: An International Lymphoma Radiation Oncology Group Multi-institutional Experience. Int J Radiat Oncol Biol Phys 2016;95:1454-1459.

Neelis KJ, Schimmel EC, Vermeer MH, et al. Low-dose palliative radiotherapy for cutaneous B- and T-cell lymphomas. Int J Radiat Oncol Biol Phys 2009;74:154-158.

Patel AM, West L, Atluri PS, et al. Optimizing palliative focal radiation therapy dose in cutaneous T-cell lymphoma: How low can you Go? Pract Radiat Oncol 2023;13:e192-e199.

Smith GL, Duvic M, Yehia ZA, et al. Effectiveness of low-dose radiation for primary cutaneous anaplastic large cell lymphoma. Adv Radiat Oncol 2017;2:363-369.

Specht L, Dabaja B, Illidge T, et al. Modern radiation therapy for primary cutaneous lymphomas: field and dose guidelines from the International Lymphoma Radiation Oncology Group. Int J Radiat Oncol Biol Phys 2015;92:32-39.

Thomas TO, Agrawal P, Guitart J, et al. Outcome of patients treated with a single-fraction dose of palliative radiation for cutaneous T-cell lymphoma. Int J Radiat Oncol Biol Phys 2013;85:747-753.

Note: All recommendations are category 2A unless otherwise indicated.

Version 2.2026, 02/13/26 © 2026 National Comprehensive Cancer Network® (NCCN®), All rights reserved. NCCN Guidelines® and this illustration may not be reproduced in any form without the express written permission of NCCN.

PLEASE NOTE that use of this NCCN Content is governed by the End-User License Agreement, and you MAY NOT distribute this Content or use it with any artificial intelligence model or tool.
Printed by Galya Basol Kochav on 2/16/2026 9:44:21 AM. Copyright © 2026 National Comprehensive Cancer Network, Inc. All Rights Reserved.

PRINCIPLES OF BIOMARKER TESTING IN CUTANEOUS LYMPHOMAS[a]

- **Biomarker testing, including high-throughput sequencing (HTS), MGPT, conventional chromosome analysis or FISH to detect somatic mutations or genetic abnormalities are often informative and in some cases essential for an accurate and precise diagnostic and prognostic assessment of cutaneous lymphomas.**

<u>*TRB* and *TRG* Gene Rearrangements</u>

- ***TRB* and *TRG* gene rearrangement testing is recommended to support a diagnosis of cutaneous lymphoma.**
- **Diseases:**
  - **MF/SS; primary cutaneous CD30+ T-cell LPDs**
- **Description:**
  - ***TRB* and *TRG* gene rearrangement is indicative of T-cell clonal expansion. The test targets the *TRB* and/or *TRG* genes using PCR with capillary or gel electrophoresis detection methods. Alternatively, HTS/MGPT are increasingly utilized. HTS/MGPT are more sensitive, precise, and capable of providing a unique sequence of the T-cell clone, which allows for comparison and confirmation of disease evolution and monitoring during remission. Clonal T-cell expansions can also be detected using V beta families in blood or tissue with flow cytometry.**
- **Diagnostic value:**
  - **Clonal *TRB* and *TRG* gene rearrangements without cytologic histopathologic and immunophenotypic evidence of abnormal T-cell population does not constitute a diagnosis of cutaneous lymphoma since it can be identified in patients with non-malignant conditions. Conversely, a negative result does not exclude the diagnosis of cutaneous lymphoma, which occasionally may not have *TRB* and *TRG* amplification. Nonetheless, it often provides essential information and increased precision for many of these complex diagnoses.**
- **Prognostic value:**
  - **Identification of clonal *TRB* and *TRG* gene rearrangement has no definitive established prognostic value; however, it could be helpful when used to determine clinical staging or assess relapsed or residual disease.**

<u>*DUSP22-IRF4* Gene Fusion</u>

- **Testing for *DUSP22* (dual-specificity phosphatase 22) rearrangement is considered useful under certain circumstances for the diagnosis of primary cutaneous CD30+ T-cell LPDs.**
- **Diseases:**
  - **Primary cutaneous CD30+ T-cell LPDs**
- **Description:**
  - ***DUSP22* is a tyrosine/threonine/serine phosphatase that may function as a tumor suppressor gene. *DUSP22* inactivation contributes to the development of PTCLs.**
- **Detection:**
  - **FISH using probes to *DUPS22-IRF4* gene region at 6p25.3**
- **Diagnostic value:**
  - ***DUSP22* rearrangement has been described in patients with PC-ALCL and LyP but is not associated with prognostic significance.**

[a] References on PCLYM-B 2 of 2.

Note: All recommendations are category 2A unless otherwise indicated.

Version 2.2026, 02/13/26 © 2026 National Comprehensive Cancer Network® (NCCN®), All rights reserved. NCCN Guidelines® and this illustration may not be reproduced in any form without the express written permission of NCCN.

PLEASE NOTE that use of this NCCN Content is governed by the End-User License Agreement, and you MAY NOT distribute this Content or use it with any artificial intelligence model or tool.
Printed by Galya Basol Kochav on 2/16/2026 9:44:21 AM. Copyright © 2026 National Comprehensive Cancer Network, Inc. All Rights Reserved.

PRINCIPLES OF BIOMARKER TESTING IN CUTANEOUS LYMPHOMAS

<u>*JAK2* Gene Rearrangements</u>

- **A subset of CTCL carry activating rearrangements of oncogenic tyrosine kinases such as *JAK2***
- **Detection:**
  - **MGPT or FISH using probes targeting *JAK2* rearrangements**
- **Diagnostic value:**
  - **Recognized as disease defining genetic abnormality in the context of clinical, histologic, and immunophenotypic features of CTCL**
- **Prognostic value:**
  - **Not known**
- **Therapeutic value:**
  - **The presence of *JAK2* rearrangement can inform therapeutic decisions in T-cell lymphomas**

REFERENCES

Chiarle R, Voena C, Ambrogio C, et al. The anaplastic lymphoma kinase in the pathogenesis of cancer. Nat Rev Cancer 2008;8:11-23.

De Schouwer PJ, Dyer MJ, Brito-Babapulle VB, et al. T-cell prolymphocytic leukaemia: antigen receptor gene rearrangement and a novel mode of MTCP1-B1 activation. Br J Haematol 2000;110:831-838.

Hu Z, Medeiros LJ, Fang L, et al. Prognostic significance of cytogenetic abnormalities in T-cell prolymphocytic leukemia. Am J Hematol 2017;92:441-447.

Karai LJ, Kadin ME, Hsi ED, et al. Chromosomal rearrangements of 6p25.3 define a new subtype of lymphomatoid papulosis. Am J Surg Pathol 2013;37:1173-1181.

Morris SW, Kirstein MN, Valentine MB, et al. Fusion of a kinase gene, ALK, to a nucleolar protein gene, NPM, in non-Hodgkin's Lymphoma. Science 1994;263:1281-1284.

Odejide O, Weigert O, Lane AA, et al. A targeted mutational landscape of angioimmunoblastic T-cell lymphoma. Blood 2014;123:1293-1296.

Onaindia A, Montes-Moreno S, Rodriguez-Pinilla SM, et al. Primary cutaneous anaplastic large cell lymphomas with 6p25.3 rearrangement exhibit particular histological features. Histopathology 2015;66:846-855.

Pedersen MB, Hamilton-Dutoit SJ, Bendix K, et al. *DUSP22* and *TP63* rearrangements predict outcome of ALK-negative anaplastic large cell lymphoma: a Danish cohort study. Blood 2017;130:554-557.

Wada DA, Law ME, Hsi ED, et al. Specificity of IRF4 translocations for primary cutaneous anaplastic large cell lymphoma: a multicenter study of 204 skin biopsies. Mod Pathol 2011;24:596-605.

Gallardo F, Pujol RM. Genetics abnormalities with clinical impact in primary cutaneous lymphomas. Cancers (Basel) 2022;14:4972.

Note: All recommendations are category 2A unless otherwise indicated.

Version 2.2026, 02/13/26 © 2026 National Comprehensive Cancer Network® (NCCN®), All rights reserved. NCCN Guidelines® and this illustration may not be reproduced in any form without the express written permission of NCCN.

PLEASE NOTE that use of this NCCN Content is governed by the End-User License Agreement, and you MAY NOT distribute this Content or use it with any artificial intelligence model or tool.
Printed by Galya Basol Kochav on 2/16/2026 9:44:21 AM. Copyright © 2026 National Comprehensive Cancer Network, Inc. All Rights Reserved.

SUPPORTIVE CARE

Viral Reactivation

- **Cytomegalovirus (CMV) Reactivation:**
  - **Clinicians must be aware of the high risk of CMV reactivation in patients receiving alemtuzumab (anti-CD52 antibody).**
  - **The current recommendations for appropriate screening and management are controversial; some NCCN Member Institutions use ganciclovir (PO or IV) preemptively if viremia is present, others only if viral load is rising.**
  - **CMV viremia should be measured by quantitative PCR at least every 2–3 weeks.**
  - **Consultation with an infectious disease expert may be necessary.**
  - **Consider evaluating CD52 expressions before initiating treatment with alemtuzumab-based regimens.**

- **John Cunningham (JC) Virus Reactivation**
  - **Brentuximab vedotin (anti-CD30 antibody-drug conjugate) can cause JC virus reactivation and progressive multifocal leukoencephalopathy (PML).**
  - **PML is usually fatal. Clinical indications may include changes in behavior such as confusion, dizziness or loss of balance, difficulty talking or walking, and vision problems.**
  - **Diagnosis is made by PCR of cerebrospinal fluid (CSF) and in some cases brain biopsy.**
  - **There is no known effective treatment.**

Anti-infective Prophylaxis

- **Recommended during treatment and thereafter (if tolerated) for patients receiving alemtuzumab (anti-CD52 antibody)**
  - **Herpes simplex virus (HSV) prophylaxis with acyclovir or equivalent.**
  - **Pneumocystis jirovecii pneumonia (PJP) prophylaxis with sulfamethoxazole/trimethoprim or equivalent.**
  - **Consider screening and treatment (if needed) for strongyloidiasis in patients with ATLL.**
  - **Consider antifungal prophylaxis.**
    - ◊ **Consultation with an infectious disease expert may be necessary. See NCCN Guidelines for Prevention and Treatment of Cancer-Related Infections.**

Note: All recommendations are category 2A unless otherwise indicated.

Version 2.2026, 02/13/26 © 2026 National Comprehensive Cancer Network® (NCCN®), All rights reserved. NCCN Guidelines® and this illustration may not be reproduced in any form without the express written permission of NCCN.

PLEASE NOTE that use of this NCCN Content is governed by the End-User License Agreement, and you MAY NOT distribute this Content or use it with any artificial intelligence model or tool.
Printed by Galya Basol Kochav on 2/16/2026 9:44:21 AM. Copyright © 2026 National Comprehensive Cancer Network, Inc. All Rights Reserved.

Classification

Table 1: Classification of Cutaneous B-Cell Lymphomas

WHO-EORTC Classification for Primary Cutaneous Lymphomas (2018)	The International Consensus Classification (ICC) of Mature Lymphoid Neoplasms (2022)	WHO Classification of Hematolymphoid Tumors: Lymphoid Neoplasms (5th edition, 2024)
Cutaneous B-Cell Lymphomas	**Mature B-Cell Neoplasms**	**Mature B-Cell Neoplasms**
Primary cutaneous marginal zone lymphoma	Primary cutaneous marginal zone lymphoproliferative disorder	Marginal zone lymphoma • Primary cutaneous marginal zone lymphoma
Primary cutaneous follicle center lymphoma	Primary cutaneous follicle center lymphoma	Cutaneous follicle center lymphoma • Primary cutaneous follicle center lymphoma
Primary cutaneous DLBCL, leg type	Primary cutaneous DLBCL, leg type	Large B-cell lymphomas • Primary cutaneous DLBCL, leg type • Intravascular large B-cell lymphoma
Intravascular large B-cell lymphoma	Intravascular large B-cell lymphoma	
EBV+ mucocutaneous ulcer (provisional)	EBV-positive mucocutaneous ulcer	Lymphoid proliferations and lymphomas associated with immune deficiency and dysregulation • EBV-positive mucocutaneous ulcer

Table 2: Classification of Cutaneous T-Cell Lymphomas (ST-2)

Willemze R, Cerroni L, Kempf W, et al. The 2018 update of the WHO-EORTC classification for primary cutaneous lymphomas. Blood 2019;133:1703-1714.

Arber DA, Borowitz MJ, Cook JR, et al. The International Consensus Classification of Myeloid and Lymphoid Neoplasms. 1st ed. Philadelphia, PA: Lippincott Williams & Wilkins; 2025.

With permission, WHO Classification of Tumours Editorial Board. Haematolymphoid tumours. (WHO classification of tumours series, 5th ed.; vol. 11). Lyon (France): International Agency for Research on Cancer; 2024.

Version 2.2026, 02/13/26 © 2026 National Comprehensive Cancer Network® (NCCN®), All rights reserved. NCCN Guidelines® and this illustration may not be reproduced in any form without the express written permission of NCCN.

PLEASE NOTE that use of this NCCN Content is governed by the End-User License Agreement, and you MAY NOT distribute this Content or use it with any artificial intelligence model or tool.
Printed by Galya Basol Kochav on 2/16/2026 9:44:21 AM. Copyright © 2026 National Comprehensive Cancer Network, Inc. All Rights Reserved.

Classification

Table 2: Classification of Cutaneous T-Cell Lymphomas

WHO-EORTC Classification for Primary Cutaneous Lymphomas (2018)	The International Consensus Classification (ICC) of Mature Lymphoid Neoplasms (2022)	WHO Classification of Hematolymphoid Tumors: Lymphoid Neoplasms (5th edition, 2024)
Cutaneous T-Cell Lymphomas	**Mature T-Cell and NK-Cell Neoplasms**	**Mature T-Cell and NK-Cell Neoplasms**
Sézary syndrome	Sézary syndrome	Sézary syndrome
		Primary cutaneous T-cell lymphoid proliferations and lymphomas
Mycosis fungoides (MF)	Mycosis fungoides	Mycosis fungoides
MF Variants • Folliculotropic MF • Pagetoid reticulosis • Granulomatous slack skin	Not included	Not included
Primary cutaneous CD30-positive T-cell lymphoproliferative disorders • Lymphomatoid papulosis • Cutaneous anaplastic large cell lymphoma	Primary cutaneous CD30-positive T-cell lymphoproliferative disorders • Lymphomatoid papulosis • Primary cutaneous anaplastic large cell lymphoma	Primary cutaneous CD30-positive T-cell lymphoproliferative disorders: • Lymphomatoid papulosis • Primary cutaneous anaplastic large cell lymphoma
Subcutaneous panniculitis-like T-cell lymphoma	Subcutaneous panniculitis-like T-cell lymphoma	Subcutaneous panniculitis-like T-cell lymphoma
Primary cutaneous peripheral T-cell lymphoma, rare subtypes		
• Primary cutaneous CD4+ small/medium T-cell lymphoproliferative disorder (provisional)	Primary cutaneous CD4-positive small or medium T-cell lymphoproliferative disorder	Primary cutaneous CD4-positive small or medium T-cell lymphoproliferative disorder
• Primary cutaneous gamma-delta T-cell lymphoma	Primary cutaneous gamma-delta T-cell lymphoma	Primary cutaneous gamma/delta T-cell lymphoma
• Primary cutaneous acral CD8-positive T-cell lymphoma (provisional)	Primary cutaneous acral CD8-positive lymphoproliferative disorder	Primary cutaneous acral CD8-positive lymphoproliferative disorder
• Primary cutaneous aggressive epidermotropic CD8+ cytotoxic T-cell lymphoma (provisional)	Primary cutaneous CD8-positive aggressive epidermotropic cytotoxic T-cell lymphoma	Primary cutaneous CD8-positive aggressive epidermotropic cytotoxic T-cell lymphoma
• Primary cutaneous peripheral T-cell lymphoma, NOS	Not included	Primary cutaneous peripheral T-cell lymphoma, NOS

Willemze R, Cerroni L, Kempf W, et al. The 2018 update of the WHO-EORTC classification for primary cutaneous lymphomas. Blood 2019;133:1703-1714.
Arber DA, Borowitz MJ, Cook JR, et al. The International Consensus Classification of Myeloid and Lymphoid Neoplasms. 1st ed. Philadelphia, PA: Lippincott Williams & Wilkins; 2025.
With permission, WHO Classification of Tumours Editorial Board. Haematolymphoid tumours. (WHO classification of tumours series, 5th ed.; vol. 11). Lyon (France): International Agency for Research on Cancer; 2024.

Version 2.2026, 02/13/26 © 2026 National Comprehensive Cancer Network® (NCCN®), All rights reserved. NCCN Guidelines® and this illustration may not be reproduced in any form without the express written permission of NCCN.

PLEASE NOTE that use of this NCCN Content is governed by the End-User License Agreement, and you MAY NOT distribute this Content or use it with any artificial intelligence model or tool.
Printed by Galya Basol Kochav on 2/16/2026 9:44:21 AM. Copyright © 2026 National Comprehensive Cancer Network, Inc. All Rights Reserved.

ABBREVIATIONS

3D	three-dimensional
ABC	activated B-cell
ALCL	anaplastic large cell lymphoma
ANA	antinuclear antibody
ASC	absolute Sézary cell
ATLL	adult T-cell leukemia/lymphoma
BSA	body surface area
C/A/P	chest/abdomen/pelvis
CBC	complete blood count
CMV	cytomegalovirus
CNS	central nervous system
CR	complete response
CSF	cerebrospinal fluid
CTCL	cutaneous T-cell lymphoma
CTV	clinical target volume
DLBCL	diffuse large B-cell lymphoma
EBER-ISH	Epstein-Barr virus-encoded RNA in situ hybridization
EBRT	external beam radiation therapy
EBV	Epstein-Barr virus
ECP	extracorporeal photopheresis
FDG	fluorodeoxyglucose
FISH	fluorescence in situ hybridization
FL	follicular lymphoma
FMF	folliculotropic mycosis fungoides
FNA	fine-needle aspiration
GCB	germinal center B-cell
GTV	gross tumor volume
HCT	hematopoietic cell transplant
HDAC	histone deacetylase
HLH	hemophagocytic lymphohistiocytosis
HSV	herpes simplex virus
HTLV	human T-cell lymphotropic virus
HTS	high-throughput sequencing
ICC	International Consensus Classification
ICOS	inducible T-cell co-stimulator
ICRU	International Commission on Radiation Units and Measurements
IHC	immunohistochemistry
ISH	in situ hybridization
ISRT	involved-site radiation therapy
IVF	in vitro fertilization
JC	John Cunningham
LCT	large-cell transformation
LDH	lactate dehydrogenase
LDi	longest diameter
LN	lymph node
LPD	lymphoproliferative disorder
LyP	lymphomatoid papulosis
MF	mycosis fungoides
MGPT	multigene panel testing
MRSA	methicillin-resistant *Staphylococcus aureus*
NB-UVB	narrowband ultraviolet B
NKTL	natural killer T-cell lymphoma
NMSC	non-melanoma skin cancer
NOS	not otherwise specified
OAR	organ at risk
OS	overall survival

Continued

Version 2.2026, 02/13/26 © 2026 National Comprehensive Cancer Network® (NCCN®), All rights reserved. NCCN Guidelines® and this illustration may not be reproduced in any form without the express written permission of NCCN.

PLEASE NOTE that use of this NCCN Content is governed by the End-User License Agreement, and you MAY NOT distribute this Content or use it with any artificial intelligence model or tool.
Printed by Galya Basol Kochav on 2/16/2026 9:44:21 AM. Copyright © 2026 National Comprehensive Cancer Network, Inc. All Rights Reserved.

ABBREVIATIONS

PC-ALCL	primary cutaneous anaplastic large cell lymphoma
PCA-TLPD	primary cutaneous acral T-cell lymphoproliferative disorder
PC-BCL	primary cutaneous B-cell lymphoma
PC-DLBCL	primary cutaneous diffuse large B-cell lymphoma
PCFCL	primary cutaneous follicle center lymphoma
PCMZL	primary cutaneous marginal zone lymphoma
PCR	polymerase chain reaction
PCSM-TLPD	primary cutaneous small/medium T-cell lymphoproliferative disorder
PD-1	programmed cell death protein 1
PID	primary immunodeficiency
PJP	*pneumocystis jirovecii* pneumonia
PML	progressive multifocal leukoencephalopathy
PR	partial response
PTCL	peripheral T-cell lymphoma
PTCL-NOS	peripheral T-cell lymphoma not otherwise specified
PTV	planning target volume
PUVA	psoralen plus ultraviolet A
RF	rheumatoid factor
S. aureus	*Staphylococcus aureus*
SLE	systemic lupus erythematosus
SPEP	serum protein electrophoresis
SPTCL	subcutaneous panniculitis-like T-cell lymphoma
SS	Sézary syndrome
SSRI	selective serotonin reuptake inhibitor
TCR	T-cell receptor
TSEBT	total skin electron beam therapy
TFH	T-follicular helper
TNMB	tumor node metastatis biopsy
UV	ultraviolet
UVA	ultraviolet A
UVB	ultraviolet B
VZV	varicella zoster virus

Version 2.2026, 02/13/26 © 2026 National Comprehensive Cancer Network® (NCCN®), All rights reserved. NCCN Guidelines® and this illustration may not be reproduced in any form without the express written permission of NCCN.

PLEASE NOTE that use of this NCCN Content is governed by the End-User License Agreement, and you MAY NOT distribute this Content or use it with any artificial intelligence model or tool.
Printed by Galya Basol Kochav on 2/16/2026 9:44:21 AM. Copyright © 2026 National Comprehensive Cancer Network, Inc. All Rights Reserved.

NCCN Categories of Evidence and Consensus	
Category 1	Based upon high-level evidence (≥1 randomized phase 3 trials or high-quality, robust meta-analyses), there is uniform NCCN consensus (≥85% support of the Panel) that the intervention is appropriate.
Category 2A	Based upon lower-level evidence, there is uniform NCCN consensus (≥85% support of the Panel) that the intervention is appropriate.
Category 2B	Based upon lower-level evidence, there is NCCN consensus (≥50%, but <85% support of the Panel) that the intervention is appropriate.
Category 3	Based upon any level of evidence, there is major NCCN disagreement that the intervention is appropriate.

All recommendations are category 2A unless otherwise indicated.

NCCN Categories of Preference	
Preferred	Interventions that are based on superior efficacy, safety, and evidence; and, when appropriate, affordability.
Other recommended	Other interventions that may be somewhat less efficacious, more toxic, or based on less mature data; or significantly less affordable for similar outcomes.
Useful in certain circumstances	Other interventions that may be used for selected patient populations (defined with recommendation).

All recommendations are considered appropriate.

PLEASE NOTE that use of this NCCN Content is governed by the End-User License Agreement, and you MAY NOT distribute this Content or use it with any artificial intelligence model or tool.
Printed by Galya Basol Kochav on 2/16/2026 9:44:21 AM. Copyright © 2026 National Comprehensive Cancer Network, Inc. All Rights Reserved.

This discussion corresponds to the NCCN Guidelines for Cutaneous Lymphomas. The discussion sections for MFSS and PCTLD were last updated on February 13, 2026. The rest of the discussion sections were last updated December 9, 2025.

Discussion

Overview MS-2
Guidelines Update Methodology MS-2
Sensitive/Inclusive Language Usage MS-2
Primary Cutaneous B-Cell Lymphomas MS-2
Mycosis Fungoides and Sézary Syndrome MS-16
Primary Cutaneous CD30+ T-Cell Lymphoproliferative Disorders MS-37
Primary Cutaneous Indolent Lymphoproliferative Disorders MS-42
Subcutaneous Panniculitis-Like T-Cell Lymphoma MS-66

Version 2.2026 © 2026 National Comprehensive Cancer Network© (NCCN©), All rights reserved. NCCN Guidelines® and this illustration may not be reproduced in any form without the express written permission of NCCN.

PLEASE NOTE that use of this NCCN Content is governed by the End-User License Agreement, and you MAY NOT distribute this Content or use it with any artificial intelligence model or tool.
Printed by Galya Basol Kochav on 2/16/2026 9:44:21 AM. Copyright © 2026 National Comprehensive Cancer Network, Inc. All Rights Reserved.

This discussion corresponds to the NCCN Guidelines for Cutaneous Lymphomas.
Last updated: December 9, 2025.

Overview

Cutaneous lymphomas are a heterogenous group of extranodal B-cell and T-cell non-Hodgkin lymphomas (NHL) originating in and usually confined to the skin. In the Surveillance, Epidemiology, and End Results (SEER) database population-based analysis of 3884 cases of primary cutaneous lymphomas (PCL) diagnosed in the United States from 2001 to 2005, the incidence of cutaneous B-cell lymphomas (CBCL) and cutaneous T-cell lymphomas (CTCL) accounted for 29% and 71%, respectively.[1] An updated SEER database analysis of data from 18-population-based registries reported an overall increase in the incidence of CTCL between 2000 and 2018 in the United States (14,942 people were diagnosed with CTCL during that period), with mycosis fungoides (MF) being the most common diagnosis, followed by primary cutaneous anaplastic large cell lymphoma (PCALCL).[2]

The World Health Organization-European Organization for Research and Treatment of Cancer (WHO-EORTC) classification for cutaneous lymphomas was first published in 2005 and was subsequently updated in 2018.[3,4] The subtypes of cutaneous lymphomas that are covered in the NCCN Clinical Practice Guidelines in Oncology (NCCN Guidelines®) are listed below:

- Cutaneous B-Cell Lymphomas
  - Primary cutaneous marginal zone lymphoma (PCMZL)
  - Primary cutaneous follicle center lymphoma (PCFCL)
  - Primary cutaneous diffuse large B-cell lymphoma, leg type (PCDLBCL, leg type)
- Cutaneous T-Cell Lymphomas
  - Mycosis fungoides (MF) and Sézary syndrome (SS)
  - Primary cutaneous CD30+ T-cell lymphoproliferative disorders (PCTLD)
  - Primary cutaneous indolent lymphoproliferative disorders (LPD)
  - Subcutaneous Panniculitis-Like T-Cell Lymphoma

Guidelines Update Methodology

The complete details of the Development and Update of the NCCN Guidelines® are available at www.NCCN.org.

Sensitive/Inclusive Language Usage

NCCN Guidelines strive to use language that advances the goals of equity, inclusion, and representation. NCCN Guidelines endeavor to use language that is person-first; not stigmatizing; anti-racist, anti-classist, anti-misogynist, anti-ageist, anti-ableist, and anti-weight-biased; and inclusive of individuals of all sexual orientations and gender identities. NCCN Guidelines incorporate non-gendered language, instead focusing on organ-specific recommendations. This language is both more accurate and more inclusive and can help fully address the needs of individuals of all sexual orientations and gender identities. NCCN Guidelines will continue to use the terms men, women, female, and male when citing statistics, recommendations, or data from organizations or sources that do not use inclusive terms. Most studies do not report how sex and gender data are collected and use these terms interchangeably or inconsistently. If sources do not differentiate gender from sex assigned at birth or organs present, the information is presumed to predominantly represent cisgender individuals. NCCN encourages researchers to collect more specific data in future studies and organizations to use more inclusive and accurate language in their future analyses.

Primary Cutaneous B-Cell Lymphomas

Primary cutaneous B-cell lymphomas (PCBCL) account for mainly three subtypes: PCMZL, PCFCL, and PCDLBCL, leg type.[3,4] PCFCL is the most

Version 2.2026 © 2026 National Comprehensive Cancer Network© (NCCN©), All rights reserved. NCCN Guidelines® and this illustration may not be reproduced in any form without the express written permission of NCCN.

PLEASE NOTE that use of this NCCN Content is governed by the End-User License Agreement, and you MAY NOT distribute this Content or use it with any artificial intelligence model or tool.
Printed by Galya Basol Kochav on 2/16/2026 9:44:21 AM. Copyright © 2026 National Comprehensive Cancer Network, Inc. All Rights Reserved.

common subtype of CBCL, diagnosed in 57% of patients followed by PCMZL (24%–31%) and PCDLBCL, leg type (11%–19%).[5,6]

In addition to these three subtypes, PCDLBCL, not otherwise specified (PCDLBCL-NOS) with clinicopathologic features intermediate between PCFCL and PCDLBCL, leg type has also been described.[7,8] In the revised 2018 WHO-EORTC classification, rare cases that cannot be classified as either PCDLBCL, leg type or PCFCL are classified as PCDLBCL-NOS.[4]

PCFCL is more prevalent in the scalp, face, and forehead, whereas the trunk and extremities are the most common sites for PCMZL.[5,6] PCMZL and PCFCL are generally indolent or slow growing and both are associated with excellent prognosis. PCMZL is now recognized as a distinct entity from other mucosa-associated lymphoid tissue (MALT) lymphomas in both the International Consensus Classification (ICC) and updated WHO classification (WHO5).[9-11] In the ICC, PCMZL are defined as primary cutaneous marginal zone lymphoproliferative disorders because of their indolent disease course.[10]

PCDLBCL, leg type is found most commonly on the leg, although it can arise at other sites.[5,6] PCDLBCL, leg type is usually aggressive and associated with a generally poorer prognosis (mainly due to the higher frequency of extracutaneous relapses).[5,6] In a large Italian series of 467 patients with PCBCL, extracutaneous involvement was reported in 17% of patients with PCDLBCL, leg type compared to 6% of patients with PCMZL and 11% with PCFCL.[5] The 5-year overall survival (OS) rate was significantly higher for patients with PCMZL and PCFCL than for patients with PCDLBCL, leg type (97%, 96%, and 73%, respectively; $P < .0001$).[5] In patients with PCMZL and PCFCL, the disease-free survival (DFS) and OS rates were significantly higher for patients with single lesions compared with those with regional or disseminated lesions (5-year DFS, 62% vs. 44%; 5-year OS, 97% vs. 85%), whereas the difference in outcomes between single and regional or disseminated lesions was not significant in patients with PCDLBCL, leg type (5-year DFS rate 55% vs. 44%; 5-year OS rate 79% vs. 67% for single and regional or disseminated lesions, respectively).[5] In the report from the Dutch Cutaneous Lymphoma Registry that included 300 patients with PCBCL, the incidence of extracutaneous relapse was 47% among patients with PCDLBCL, leg type compared to 11% and 9%, respectively, for patients with PCFCL and PCMZL.[6] The 5-year disease-specific survival rates in this series were 95%, 98%, and 50% for PCFCL, PCMZL, and PCDLBCL, leg type, respectively.

While the diagnosis of PCMZL is generally straightforward and reproducible among pathologists, it is more difficult to distinguish between PCFCL and PCDLBCL, leg type, partly because the cell size (large vs. small) is not a defining feature as it is in nodal B-cell lymphomas. Disease-specific characteristics identified by molecular and gene expression profiling (GEP) studies (as described below) may be helpful to distinguish the subtypes of CBCL.[12]

PCMZL can be divided into two subgroups with different prognosis based on the immunoglobulin (Ig) heavy chain usage, with the vast majority being Ig class-switched subtype (IgG/IgG4, IgA, and IgE), CXCR3 and IgM negative and a small subset being CXCR3 positive and IgM positive.[11,13-17] Emerging data suggest that Ig class-switched subtype (IgM-negative) may be categorized as a clonal chronic lymphoproliferative disorder due to its indolent disease course.[16,18]

GEP studies have shown that PCFCL is characterized by a germinal center B-cell (GCB) phenotype and PCDLBCL, leg type is most commonly characterized by activated B-cell (ABC) phenotype.[12,19] Thus, a germinal (or follicle) center phenotype and large cells in a skin lesion is consistent with PCFCL.[19] In nodal DLBCL, the GCB phenotype is associated with a better prognosis than the ABC phenotype. Immunohistochemical (IHC) and GEP-based algorithms used to classify nodal DLBCL into GCB or

Version 2.2026 © 2026 National Comprehensive Cancer Network© (NCCN©), All rights reserved. NCCN Guidelines® and this illustration may not be reproduced in any form without the express written permission of NCCN.

PLEASE NOTE that use of this NCCN Content is governed by the End-User License Agreement, and you MAY NOT distribute this Content or use it with any artificial intelligence model or tool.
Printed by Galya Basol Kochav on 2/16/2026 9:44:21 AM. Copyright © 2026 National Comprehensive Cancer Network, Inc. All Rights Reserved.

non-GCB subtypes based on cell of origin (COO) have also shown to be useful to distinguish PCFCL from PCDLBCL, leg type.[20-22] However, these algorithms may be of limited utility in the differentiation of PC-DLBCL, leg type and PCFCL-LC.[22] While all cases of PCFCL-LC were uniformly classified as GCB phenotype by both IHC and GEP-based algorithms, the classification based on COO was heterogenous in patients with PC-DLBCL, leg type.[22]

A high prevalence of gain-of-function mutations in *MYD88* (*MYD88* L265P) and *CD79B* genes have been reported in patients with PCDLBCL, leg type and are associated with inferior clinical outcomes.[12,20,23] GEP studies have also identified that PCDLBCL belongs to MCD subtype (co-occurrence of *MYD88* and *CD79B* gain-of function mutations), which is associated with ABC phenotype.[12] In the aforementioned report that evaluated the clinicopathologic and molecular characteristics of patients with PCFCL (25 patients) and PCDLBCL, leg type (32 patients), *MYD88* L265P mutation was detected only in patients with PCDLBCL, leg type (n = 22; 69%).[20] In a retrospective analysis of 61 patients (58 patients with interpretable results) diagnosed with PCDLBCL, leg type, *MYD88* L265P mutation was detected in 59% of patients.[23] It was also associated with shorter disease-specific survival and was an independent adverse prognostic factor for OS. The 3-year and 5-year disease-specific survival rates for those with *MYD88* L265P mutation were 66% and 60%, respectively, compared to 85% and 72%, respectively, for patients with the wild-type allele.

These findings suggest next-generation sequencing (NGS) for *MYD88* and *CD79B* mutations could be helpful to further distinguish PCDLBCL, leg type from PCFCL. IgM expression should be checked if *MYD88* mutations are identified since IgM-positivity is likely associated with systemic involvement.

Literature Search Criteria

Prior to the update of this version of the NCCN Guidelines for Primary Cutaneous Lymphomas, a literature search was performed to obtain key literature on PCBCL published since the previous Guidelines update, using the following search terms: cutaneous diffuse large B-cell lymphoma, cutaneous follicle center lymphoma, and cutaneous marginal zone lymphoma. The PubMed database was chosen as it remains the most widely used resource for medical literature and indexes peer-reviewed biomedical literature.[24]

The search results were narrowed by selecting studies in humans published in English. The data from key PubMed articles deemed as relevant to these guidelines have been included in this version of the Discussion section. Recommendations for which high-level evidence is lacking are based on the Panel's review of lower-level evidence and expert opinion.

The complete details of the Development and Update of the NCCN Guidelines are available at www.NCCN.org.

Diagnosis

PCMZL are negative for BCL6 and CD10, but are often positive for CD20 and BCL2.[25] PCFCL is consistently BCL6-positive, whereas CD10 and BCL2 are expressed in only a few cases with a follicular growth pattern and the detection of *BCL2* rearrangement is generally associated with extracutaneous spread.[26-29]

PCDLBCL, leg type tumors express CD20, IRF4/MUM1, FOXP1, and BCL2; many cases express BCL6 and lack expression of CD10.[6,19,20,30-32] PCDLBCL, leg type also has a high incidence of *MYC* rearrangements and *MYC* rearrangements are not detected in PCFCL.[33] In addition, PCFCL is usually IRF4/MUM1-negative while PCDLBCL, leg type is usually IRF4/MUM1-positive and shows strong expression of FOXP1.[31,32]

Version 2.2026 © 2026 National Comprehensive Cancer Network© (NCCN©), All rights reserved. NCCN Guidelines® and this illustration may not be reproduced in any form without the express written permission of NCCN.

PLEASE NOTE that use of this NCCN Content is governed by the End-User License Agreement, and you MAY NOT distribute this Content or use it with any artificial intelligence model or tool.
Printed by Galya Basol Kochav on 2/16/2026 9:44:21 AM. Copyright © 2026 National Comprehensive Cancer Network, Inc. All Rights Reserved.

Assessment of FOXP1 expression is helpful to distinguish PCDLBCL, leg type from PCFCL since all cases of PCFCL are FOXP1-negative.[32] GEP-based algorithms and modified Hans IHC algorithm including CD10 and MUM1 have been shown to be useful to distinguish PCFCL from PCDLBCL, leg type with optimal diagnostic value without the need for BCL-6.[20,21]

The diagnosis of PCBCL is established by adequate biopsy of skin lesions. Multiple biopsies may be necessary to capture the pathologic variability of disease at diagnosis. Incisional, excisional, or punch biopsy is preferred to shave biopsy, as PCBCL have primarily dermal infiltrates, often deep, which are less well-sampled and can be missed by a shave biopsy. Review of the slides by a pathologist with expertise in the diagnosis of PCBCL is recommended. Adequate immunophenotyping of the biopsy sample is essential for the diagnosis of the exact subtype of PCBCL. In addition, immunophenotyping is also useful to rule out cutaneous lymphoid hyperplasia (also known as pseudolymphoma or lymphocytoma cutis)[34-36] and in the differential diagnosis of intravascular large B-cell lymphoma, which often manifests in skin and is associated with a poor prognosis.[37]

The initial IHC panel should include CD20, CD3, CD5, CD10, BCL2, BCL6, and IRF4/MUM1. Under certain circumstances, evaluation of additional IHC markers such as Ki-67, CD43, CD21, CD23, cyclin D1, and kappa/lambda as well as MYC (IHC or in situ hybridization [ISH]) may be useful to further establish the lymphoma subtype. Additionally, assessment of surface IgM and FOXP1 expression may also be helpful in distinguishing PCDLBCL, leg type from PCFCL.[31,32,38] Epstein-Barr virus (EBV)-positive mucocutaneous ulcer is also included as a new provisional entity in the updated WHO-EORTC classification and Epstein-Barr virus-encoded RNA in situ hybridization (EBER-ISH) may be useful under selected circumstances.[4]

The t(14;18) translocation on fluorescence in situ hybridization (FISH) has been observed only in a small number of cases with PCFCL, and the detection of a t(14;18) translocation suggests the presence of systemic follicular lymphoma (FL).[28,39] Cytogenetics or FISH to detect t(14;18) and FISH to detect *BCL2* and *BCL6* rearrangements if MYC is positive may be useful if systemic FL is suspected. The feasibility of flow cytometric immunophenotyping of skin biopsies for the assessment of B-cell clonality has been reported, although it has not been widely used.[36] If adequate biopsy material is available, molecular analysis to detect Ig heavy chain gene rearrangement or flow cytometry could be useful to determine B-cell clonality.

Mantle cell lymphoma (MCL) is not a cutaneous lymphoma and finding it in the skin requires a careful search for extracutaneous disease. Clinical presentation on the leg and blastoid cytology along with high proliferative index and expression of BCL2, IRF4/MUM1, and IgM would often represent MCL with skin involvement.[40] The use of cyclin D1 may be useful to differentiate PCMZL (negative for CD5 and cyclin D1) from MCL (positive for CD5 and cyclin D1).

Workup

The absence of extracutaneous disease at diagnosis is part of the definition of PCBCL. The initial workup is geared toward evaluating extent of disease on the skin and seeking extracutaneous disease.[41]

The initial workup should include a complete physical examination, a comprehensive skin examination, complete blood count (CBC) with differential, comprehensive metabolic panel, and CT and/or PET/CT of the chest, abdomen, and pelvis. Peripheral blood flow cytometry will be useful in selected cases, if CBC demonstrates lymphocytosis. Imaging is effective in identifying systemic involvement in patients with indolent CBCL.[42] However, it can be omitted if clinically indicated in patients with

Version 2.2026 © 2026 National Comprehensive Cancer Network© (NCCN©), All rights reserved. NCCN Guidelines® and this illustration may not be reproduced in any form without the express written permission of NCCN.

PLEASE NOTE that use of this NCCN Content is governed by the End-User License Agreement, and you MAY NOT distribute this Content or use it with any artificial intelligence model or tool.
Printed by Galya Basol Kochav on 2/16/2026 9:44:21 AM. Copyright © 2026 National Comprehensive Cancer Network, Inc. All Rights Reserved.

low-grade indolent PCBCL.[43] PET/CT may have higher sensitivity in the detection of both local and distant metastases than CT.[44] However, this is not validated and the higher rates of false-positive findings can create confusion.

Bone marrow biopsy is essential for PCDLBCL, leg type, since this is an aggressive lymphoma that will probably require systemic treatment; however, it appears to have a more limited value in PCFCL and PCMZL, and may be considered only in selected patients (eg, for patients with unexplained cytopenias or if there is clinical suspicion of more aggressive subtypes).[11,41,43,45] Senff et al evaluated 275 patients with histologic features consistent with marginal zone lymphoma (MZL; n = 82) or follicle center lymphoma (FCL; n = 193) first presenting in the skin.[45] Bone marrow involvement was seen in approximately 11% of patients in the FCL group compared with 2% in the MZL group. Among patients with FCL, a positive bone marrow was associated with significantly worse prognosis compared with those with skin lesions only; the 5-year OS rate was 44% and 84%, respectively.[45]

The International Society of Cutaneous Lymphomas (ISCL) and the EORTC Task Force recommend that bone marrow biopsy be obtained for cutaneous lymphomas with intermediate to aggressive behaviors and should be considered for cutaneous lymphomas with indolent behavior and when there is any evidence of extracutaneous disease, as indicated by other staging assessments (eg, radiographic evidence or serologic clues such as elevated monoclonal or polyclonal Ig).[41]

The NCCN Guidelines recommend considering bone marrow biopsy for patients with unexplained cytopenias or if there is clinical suspicion of PCDLBCL, leg type.

Treatment Options

Involved-site radiation therapy (ISRT) is very effective when used as initial therapy as well as for cutaneous relapses in most patients with indolent PCBCL.[46-50]

In a retrospective study of 34 patients with PCBCL treated with RT, 5-year relapse-free survival (RFS) rates ranged from 62% to 73% for PCFCL and PCMZL but were only 33% for patients with PCDLBCL, leg type.[47] The 5-year OS rate was 100% for PCFCL and PCMZL but was 67% for PCDLBCL, leg type. Senff et al evaluated the outcome of 153 patients with PCBCL (25 with PCMZL; 101 with PCFCL; and 27 with PCDLBCL) who were initially treated with RT with a curative intent.[48] Overall, 45% of patients had single lesions while localized or disseminated lesions were seen in 43% and 12% of patients, respectively. Complete response (CR) was obtained in 151 of 153 patients (99%). Relapse rates for PCMZL, PCFCL, and PCDLBCL, leg type were 60%, 29%, and 64%, and the 5-year disease-specific survival rates were 95%, 97%, and 59%, respectively. The PCFCLs presenting on the legs also had a higher relapse rate (63%) and a lower 5-year disease-specific survival (44%) compared with PCFCLs occurring at other sites (25% and 99%, respectively).[48]

In another retrospective study of 42 patients with biopsy-proven PCFCL and PCMZL, RT resulted in CR in all patients.[50] The 10-year RFS and OS rates were 71% and 87%, respectively, for the entire cohort, after a median follow-up of 9.5 years. The 5-year RFS rate was higher for patients with trunk lesions and single lesions (89% and 84%, respectively) compared to those with extra-trunk lesions and multiple lesions (67% and 57%, respectively).

Version 2.2026 © 2026 National Comprehensive Cancer Network© (NCCN©), All rights reserved. NCCN Guidelines® and this illustration may not be reproduced in any form without the express written permission of NCCN.

PLEASE NOTE that use of this NCCN Content is governed by the End-User License Agreement, and you MAY NOT distribute this Content or use it with any artificial intelligence model or tool.
Printed by Galya Basol Kochav on 2/16/2026 9:44:21 AM. Copyright © 2026 National Comprehensive Cancer Network, Inc. All Rights Reserved.

Low-dose ISRT (4 Gy in 2 fractions) is an effective treatment option for palliation of symptoms in patients with persistent (initial) lesions or recurrent symptomatic disease.[51,52]

The results of a more recent retrospective study also showed that RT ≤12 Gy (4 Gy for relapsed disease) was equally effective as RT ≥12 Gy in patients with indolent PCBCL (42 patients; 16 patients had PCFCL).[53]

ISRT and excision result in higher response rates compared to chemotherapy in patients with indolent histologies, but were generally used for those with more limited disease; therefore, a direct comparison cannot be made.[5,54-57] In a large retrospective analysis by the Italian Study Group for Cutaneous Lymphomas involving 467 patients with PCBCL, the CR rate and the 5- and 10-year OS rates for all patients with PCFCL and PCMZL who received first-line treatment (RT in 53%, with total dose of 35–45 Gy; chemotherapy in 25%, mainly with CHOP; surgery in 23%) were 92% to 95%, 96% to 97%, and 89% to 91%, respectively.[5] The relapse rate was 44% to 47% and extracutaneous spread was observed in 6% to 11% of patients. Relapse rate did not vary by the type of initial therapy. In patients with PCDLBCL, leg type, the CR rate and 5- and 10-year OS rates were 82%, 73%, and 47%, respectively. PCDLBCL, leg type was associated with higher relapse rates (55%) and higher incidences of extracutaneous spread (17%)—a higher relapse rate was confirmed both for patients with single or regional lesions treated with RT and for patients with disseminated cutaneous involvement treated with chemotherapy.[5] In a retrospective analysis of 137 patients with PCMZL, initial treatment with surgical excision, RT, or a combination of both resulted in a CR rate of 88% (93% for patients with solitary or localized disease and 71% for those with multifocal lesions).[56] Although there were no significant differences in the rate of recurrences between the treatment modalities, surgery alone was associated with more recurrences at the initial site.

Rituximab monotherapy (intravenous[58-63] and intralesional[64-66]) has been shown to be effective for PCMZL and PCFCL. Intravenous rituximab may be more effective for patients with multiple lesions that cannot be managed effectively with local therapy.[58-62] In a retrospective analysis of 15 patients with indolent PCBCL, rituximab resulted in an overall response rate (ORR) of 87% (60% CR). The ORR was 100% for patients with PCFCL and 60% for patients with PCMZL. With a median follow-up of 36 months, the median duration of response was 24 months.[61] In another series of 16 patients with PCBCL, 14 patients (88%) achieved a CR with rituximab monotherapy; 35% of these patients with CR eventually relapsed between 6 and 37 months.[62] In an observational multicenter study conducted by the Spanish Working Group on Cutaneous Lymphoma (17 patients with PCMZL and 18 patients with PCFCL), intralesional rituximab induced CR and partial response (PR) in 71% and 23% of patients, respectively, with a median DFS of 114 weeks.[64] The response rates were similar among patients with PCMZL and PCFCL. In a small series that evaluated the efficacy of intravenous and intralesional rituximab in treatment of patients with PCMZL and PCFCL, although intralesional rituximab resulted in response rates similar to that of intravenous rituximab, within a 12-month follow-up period, relapses were more frequent among patients treated with intralesional rituximab.[67]

In a real-world multicenter, retrospective study of 235 patients with CBCL (PCMZL, n = 123; PCFCL, n = 96; PCDLBCL, leg type, n = 16), the 5-year PFS rates were 67% and 59% for patients with PCMZL and PCFCL, respectively.[63] Surgical excision (36%) and RT (27%) were the most common initial treatment options. Systemic rituximab, chemoimmunotherapy, and topical or intralesional steroids were administered in 13%, 8%, and 7%, of patients, respectively. Surgical excision and RT were more effective than systemic rituximab (CR rates were 89% for both surgical excision and RT compared to 59% for systemic rituximab). Treatment with RT and topical or intralesional steroids was

Version 2.2026 © 2026 National Comprehensive Cancer Network© (NCCN©), All rights reserved. NCCN Guidelines® and this illustration may not be reproduced in any form without the express written permission of NCCN.

PLEASE NOTE that use of this NCCN Content is governed by the End-User License Agreement, and you MAY NOT distribute this Content or use it with any artificial intelligence model or tool.
Printed by Galya Basol Kochav on 2/16/2026 9:44:21 AM. Copyright © 2026 National Comprehensive Cancer Network, Inc. All Rights Reserved.

associated with longer median time to next treatment (445 days and 359 days, respectively) compared to surgical excision (154 days).

Several case reports have shown the effectiveness of skin-directed therapy (steroids, imiquimod, and nitrogen mustard or bexarotene gel) for patients with multifocal lesions.[68-72] Interlesional steroids have also been used in the management of PCFCL or PCMZL, although only limited data are available.[54,63,73,74] Systemic therapy (rituximab monotherapy or combination chemoimmunotherapy) is often more appropriate for those with generalized disease (skin only; T3) in patients with PCFCL or PCMZL.[58-62,68,75-77]

Because there are no data from randomized clinical trials, the treatment recommendations included in the NCCN Guidelines are derived from the management practices of patients with PCBCL at NCCN Member Institutions based on the limited data from retrospective analyses and studies involving a small cohort of patients.

Primary Cutaneous Marginal Zone Lymphoma and Primary Cutaneous Follicle Center Cell Lymphoma

While PCMZL and PCFCL respond to initial therapy, disease relapse is common in the majority of patients with regional or generalized disease, regardless of type of initial treatment. However, relapses are generally confined to the skin in which case survival does not appear to be affected. In a retrospective analysis that assessed the efficacy of various treatment modalities (55 patients; majority of patients had indolent PCBCL; 25 patients with PCMZL and 24 patients with PCFCL), the type of treatment modality (skin-directed vs. definitive RT with or without systemic therapy) did not affect the time to first recurrence among patients with T1 and T2/T3 lesions.[78] The rates of recurrence were higher for T2/T3 lesions compared to T1 lesions (58% and 31%, respectively). The time to first recurrence for T1 lesions was 33% and 29%, respectively, for patients with PCMZL and PCFCL; however, the difference was not significant. Among patients with T2/T3 lesions, there was a non-significant trend toward higher rate of recurrence for PCMZL than PCFCL (73% and 38%, respectively).

Additional imaging studies during the course of treatment are not needed after negative initial staging for systemic involvement, and clinical follow-up without routine imaging may be appropriate for patients with PCMZL.[42] PET/CT (preferred) or CT with contrast may be repeated at the end of treatment for assessment of response and can be repeated if there is clinical suspicion of progressive disease.

Solitary or Regional Lesions (T1–T2)

Local ISRT (24–30 Gy) is a preferred initial treatment option. Excision or skin-directed therapy or intralesional steroids may be used for selected patients. Observation is an option when RT or excision is neither desired nor feasible (eg, lesions on the scalp where hair loss is a major concern).

Observation is also recommended for patients with disease responding to initial therapy, and those with refractory disease should be treated as described for generalized disease below.

Low-dose RT (4 Gy) may be adequate for relapsed or refractory disease.[51-53] Patients with regional relapse should be treated with an alternate initial treatment option and those with generalized disease relapse confined to the skin should receive treatment options recommended for generalized disease at presentation.

Patients with extracutaneous relapse or those with cutaneous relapse that is not responding to any of the initial treatment options should be treated according to the FL or nodal MZL as outlined in the NCCN Guidelines for B-Cell Lymphomas.

Version 2.2026 © 2026 National Comprehensive Cancer Network© (NCCN©), All rights reserved. NCCN Guidelines® and this illustration may not be reproduced in any form without the express written permission of NCCN.

PLEASE NOTE that use of this NCCN Content is governed by the End-User License Agreement, and you MAY NOT distribute this Content or use it with any artificial intelligence model or tool.
Printed by Galya Basol Kochav on 2/16/2026 9:44:21 AM. Copyright © 2026 National Comprehensive Cancer Network, Inc. All Rights Reserved.

Generalized Disease (skin only; T3)

Skin-directed therapy, local ISRT (24–30 Gy) for palliation of symptoms, intralesional steroids, or rituximab are included as options for initial treatment. Observation is appropriate in asymptomatic patients. In patients with very extensive or symptomatic disease, other combination chemotherapy regimens recommended for FL or nodal MZL may be used.[75-77]

Observation is recommended for patients with disease responding to initial therapy, and those with refractory disease should be treated with an alternate initial treatment option.

Patients with relapse localized to skin should be treated with an alternate initial treatment option. Patients with extracutaneous relapse or those with cutaneous relapse that is not responding to any of the initial treatment options should be treated as described for extracutaneous disease.

Extracutaneous Disease

Extracutaneous disease should be managed according to FL or nodal MZL as outlined in the NCCN Guidelines for B-Cell Lymphomas.[75-77]

Primary Cutaneous Diffuse Large B-Cell Lymphoma, Leg Type

RT alone is less effective in patients with PCDLBCL, leg type. While these lesions do respond to RT, remissions are often short-lived and higher rates of dissemination to extracutaneous sites may occur.

The potential utility of chemoimmunotherapy for the treatment of PCDLBCL, leg type has been described only in retrospective analyses and case reports.[79-84] In a retrospective multicenter study from the French Study Group on 60 patients with PCDLBCL, leg type, patients treated with anthracycline-based chemoimmunotherapy had a more favorable short-term outcome, although no particular therapy (RT or multiagent chemotherapy with or without rituximab) was significantly associated with improved survival outcomes.[79] Among 12 patients treated with anthracycline-based chemoimmunotherapy, the CR rate was 92% compared to 62% for patients who received other therapies. The 2-year OS rate for these two groups was 81% and 59%, respectively.

Multiagent chemoimmunotherapy regimens have been associated with excellent outcomes.[82-84] In a report from the French Study Group (115 patients), the 3- and 5-year survival rates were 80% and 74%, respectively, for patients who received multiagent chemoimmunotherapy compared to 48% and 38%, respectively, for patients who received less-intensive therapies.[82] In a more recent retrospective analysis involving 28 patients with PCDLBCL, leg type treated in a single center, R-CHOP (rituximab, cyclophosphamide, doxorubicin, vincristine and prednisone) with ISRT resulted in significantly longer median PFS compared to R-CHOP without ISRT as front-line therapy (58 vs. 14 months; $P = .04$).[84]

PCDLBCL, leg type has a poorer prognosis than other types of PCBCL and is generally treated with more aggressive chemoimmunotherapy regimens used for systemic DLBCL as outlined in the NCCN Guidelines for B-Cell Lymphomas.

Version 2.2026 © 2026 National Comprehensive Cancer Network© (NCCN©), All rights reserved. NCCN Guidelines® and this illustration may not be reproduced in any form without the express written permission of NCCN.

PLEASE NOTE that use of this NCCN Content is governed by the End-User License Agreement, and you MAY NOT distribute this Content or use it with any artificial intelligence model or tool.
Printed by Galya Basol Kochav on 2/16/2026 9:44:21 AM. Copyright © 2026 National Comprehensive Cancer Network, Inc. All Rights Reserved.

References

1. Bradford PT, Devesa SS, Anderson WF, Toro JR. Cutaneous lymphoma incidence patterns in the United States: a population-based study of 3884 cases. Blood 2009;113:5064–5073. Available at: https://www.ncbi.nlm.nih.gov/pubmed/19279331.

2. Cai ZR, Chen ML, Weinstock MA, et al. Incidence trends of primary cutaneous T-cell lymphoma in the US from 2000 to 2018: A SEER population data analysis. JAMA Oncol 2022;8:1690–1692. Available at: https://www.ncbi.nlm.nih.gov/pubmed/36048455.

3. Willemze R, Jaffe ES, Burg G, et al. WHO-EORTC classification for cutaneous lymphomas. Blood 2005;105:3768–3785. Available at: https://www.ncbi.nlm.nih.gov/pubmed/15692063.

4. Willemze R, Cerroni L, Kempf W, et al. The 2018 update of the WHO-EORTC classification for primary cutaneous lymphomas. Blood 2019;133:1703–1714. Available at: https://www.ncbi.nlm.nih.gov/pubmed/30635287.

5. Zinzani PL, Quaglino P, Pimpinelli N, et al. Prognostic factors in primary cutaneous B-cell lymphoma: the Italian Study Group for Cutaneous Lymphomas. J Clin Oncol 2006;24:1376–1382. Available at: https://www.ncbi.nlm.nih.gov/pubmed/16492713.

6. Senff NJ, Hoefnagel JJ, Jansen PM, et al. Reclassification of 300 primary cutaneous B-Cell lymphomas according to the new WHO-EORTC classification for cutaneous lymphomas: comparison with previous classifications and identification of prognostic markers. J Clin Oncol 2007;25:1581–1587. Available at: https://www.ncbi.nlm.nih.gov/pubmed/17353548.

7. Lucioni M, Berti E, Arcaini L, et al. Primary cutaneous B-cell lymphoma other than marginal zone: clinicopathologic analysis of 161 cases: Comparison with current classification and definition of prognostic markers. Cancer Med 2016;5:2740–2755. Available at: https://www.ncbi.nlm.nih.gov/pubmed/27665744.

8. Felcht M, Klemke CD, Nicolay JP, et al. Primary cutaneous diffuse large B-cell lymphoma, NOS and leg type: Clinical, morphologic and prognostic differences. J Dtsch Dermatol Ges 2019;17:275–285. Available at: https://www.ncbi.nlm.nih.gov/pubmed/30851152.

9. WHO Classification of Tumours Editorial Board. Haematolymphoid tumours. (WHO classification of tumours series, 5th ed.; vol. 11). Lyon (France): International Agency for Research on Cancer; 2024.

10. Arber DA, Borowitz MJ, Cook JR, et al. The International Consensus Classification of myeloid and lymphoid neoplasms (ed Edition 1); 2025.

11. Willemze R, Assaf C, Bagot M, et al. European Organisation for Research and Treatment of Cancer, United States Cutaneous Lymphoma Consortium and International Society for Cutaneous Lymphomas consensus recommendations for management and treatment of cutaneous lymphoproliferative disorders. Br J Dermatol 2025;193:1090–1100. Available at: https://www.ncbi.nlm.nih.gov/pubmed/40795052.

12. Zhang Y, LeWitt TM, Louissaint A, Jr., et al. Disease-defining molecular features of primary cutaneous B-cell lymphomas: implications for classification and treatment. J Invest Dermatol 2023;143:189–196. Available at: https://www.ncbi.nlm.nih.gov/pubmed/36163302.

13. van Maldegem F, van Dijk R, Wormhoudt TA, et al. The majority of cutaneous marginal zone B-cell lymphomas expresses class-switched immunoglobulins and develops in a T-helper type 2 inflammatory environment. Blood 2008;112:3355–3361. Available at: https://www.ncbi.nlm.nih.gov/pubmed/18687986.

14. Edinger JT, Kant JA, Swerdlow SH. Cutaneous marginal zone lymphomas have distinctive features and include 2 subsets. Am J Surg Pathol 2010;34:1830–1841. Available at: https://www.ncbi.nlm.nih.gov/pubmed/21107089.

15. Kogame T, Takegami T, Sakai TR, et al. Immunohistochemical analysis of class-switched subtype of primary cutaneous marginal zone lymphoma in terms of inducible skin-associated lymphoid tissue. J Eur

Version 2.2026 © 2026 National Comprehensive Cancer Network© (NCCN©), All rights reserved. NCCN Guidelines® and this illustration may not be reproduced in any form without the express written permission of NCCN.

PLEASE NOTE that use of this NCCN Content is governed by the End-User License Agreement, and you MAY NOT distribute this Content or use it with any artificial intelligence model or tool.
Printed by Galya Basol Kochav on 2/16/2026 9:44:21 AM. Copyright © 2026 National Comprehensive Cancer Network, Inc. All Rights Reserved.

Acad Dermatol Venereol 2019;33:e401–e403. Available at: https://www.ncbi.nlm.nih.gov/pubmed/31124191.

16. Carlsen ED, Swerdlow SH, Cook JR, Gibson SE. Class-switched primary cutaneous marginal zone lymphomas are frequently IgG4-positive and have features distinct from IgM-positive cases. Am J Surg Pathol 2019;43:1403–1412. Available at: https://www.ncbi.nlm.nih.gov/pubmed/31464711.

17. Beltzung F, Beylot-Barry M, Battistella M, et al. Recurrent primary cutaneous marginal zone lymphoma: a comparative study of initial tumours, recurrences, and outcomes in 61 patients. Histopathology 2025;86:704–714. Available at: https://www.ncbi.nlm.nih.gov/pubmed/39628350.

18. Gibson SE, Swerdlow SH. How I diagnose primary cutaneous marginal zone lymphoma. Am J Clin Pathol 2020;154:428–449. Available at: https://www.ncbi.nlm.nih.gov/pubmed/32808967.

19. Hoefnagel JJ, Dijkman R, Basso K, et al. Distinct types of primary cutaneous large B-cell lymphoma identified by gene expression profiling. Blood 2005;105:3671–3678. Available at: https://www.ncbi.nlm.nih.gov/pubmed/15308563.

20. Menguy S, Beylot-Barry M, Parrens M, et al. Primary cutaneous large B-cell lymphomas: relevance of the 2017 World Health Organization classification: clinicopathological and molecular analyses of 64 cases. Histopathology 2019;74:1067–1080. Available at: https://www.ncbi.nlm.nih.gov/pubmed/30715765.

21. Cretella P, Peluso AL, Picariello C, et al. Immunohistochemical algorithms and gene expression profiling in primary cutaneous B-cell lymphoma. Pathol Res Pract 2022;231:153804. Available at: https://www.ncbi.nlm.nih.gov/pubmed/35183824.

22. Schrader AMR, de Groen RAL, Willemze R, et al. Cell-of-origin classification using the Hans and Lymph2Cx algorithms in primary cutaneous large B-cell lymphomas. Virchows Arch 2022;480:667–675. Available at: https://www.ncbi.nlm.nih.gov/pubmed/35028710.

23. Pham-Ledard A, Beylot-Barry M, Barbe C, et al. High frequency and clinical prognostic value of MYD88 L265P mutation in primary cutaneous diffuse large B-cell lymphoma, leg-type. JAMA Dermatol 2014;150:1173–1179. Available at: https://www.ncbi.nlm.nih.gov/pubmed/25055137.

24. PubMed Overview. Available at: https://pubmed.ncbi.nlm.nih.gov/about/. Accessed February 12, 2025.

25. Hoefnagel JJ, Vermeer MH, Jansen PM, et al. Bcl-2, Bcl-6 and CD10 expression in cutaneous B-cell lymphoma: further support for a follicle centre cell origin and differential diagnostic significance. Br J Dermatol 2003;149:1183–1191. Available at: http://www.ncbi.nlm.nih.gov/pubmed/14674895.

26. de Leval L, Harris NL, Longtine J, et al. Cutaneous B-cell lymphomas of follicular and marginal zone types: use of Bcl-6, CD10, Bcl-2, and CD21 in differential diagnosis and classification. Am J Surg Pathol 2001;25:732–741. Available at: https://www.ncbi.nlm.nih.gov/pubmed/11395550.

27. Pham-Ledard A, Cowppli-Bony A, Doussau A, et al. Diagnostic and prognostic value of BCL2 rearrangement in 53 patients with follicular lymphoma presenting as primary skin lesions. Am J Clin Pathol 2015;143:362–373. Available at: https://www.ncbi.nlm.nih.gov/pubmed/25696794.

28. Servitje O, Climent F, Colomo L, et al. Primary cutaneous vs secondary cutaneous follicular lymphomas: A comparative study focused on BCL2, CD10, and t(14;18) expression. J Cutan Pathol 2019;46:182–189. Available at: https://www.ncbi.nlm.nih.gov/pubmed/30511443.

29. Pileri A, Grandi V, Agostinelli C, et al. BCL-2 expression in primary cutaneous follicle center lymphoma is associated with a higher risk of cutaneous relapses: A study of 126 cases. J Eur Acad Dermatol Venereol 2022;36:e811–e813. Available at: https://www.ncbi.nlm.nih.gov/pubmed/35648475.

30. Kodama K, Massone C, Chott A, et al. Primary cutaneous large B-cell lymphomas: clinicopathologic features, classification, and prognostic

Version 2.2026 © 2026 National Comprehensive Cancer Network© (NCCN©), All rights reserved. NCCN Guidelines® and this illustration may not be reproduced in any form without the express written permission of NCCN.

PLEASE NOTE that use of this NCCN Content is governed by the End-User License Agreement, and you MAY NOT distribute this Content or use it with any artificial intelligence model or tool.
Printed by Galya Basol Kochav on 2/16/2026 9:44:21 AM. Copyright © 2026 National Comprehensive Cancer Network, Inc. All Rights Reserved.

factors in a large series of patients. Blood 2005;106:2491–2497. Available at: https://www.ncbi.nlm.nih.gov/pubmed/15947086.

31. Hoefnagel JJ, Mulder MM, Dreef E, et al. Expression of B-cell transcription factors in primary cutaneous B-cell lymphoma. Mod Pathol 2006;19:1270–1276. Available at: https://www.ncbi.nlm.nih.gov/pubmed/16778825.

32. Espinet B, Garcia-Herrera A, Gallardo F, et al. FOXP1 molecular cytogenetics and protein expression analyses in primary cutaneous large B cell lymphoma, leg-type. Histol Histopathol 2011;26:213–221. Available at: https://www.ncbi.nlm.nih.gov/pubmed/21154235.

33. Schrader AMR, Jansen PM, Vermeer MH, et al. High incidence and clinical significance of *MYC* rearrangements in primary cutaneous diffuse large B-cell lymphoma, leg type. Am J Surg Pathol 2018;42:1488–1494. Available at: https://www.ncbi.nlm.nih.gov/pubmed/30113335.

34. Baldassano MF, Bailey EM, Ferry JA, et al. Cutaneous lymphoid hyperplasia and cutaneous marginal zone lymphoma: comparison of morphologic and immunophenotypic features. Am J Surg Pathol 1999;23:88–96. Available at: https://www.ncbi.nlm.nih.gov/pubmed/9888708.

35. Leinweber B, Colli C, Chott A, et al. Differential diagnosis of cutaneous infiltrates of B lymphocytes with follicular growth pattern. Am J Dermatopathol 2004;26:4–13. Available at: https://www.ncbi.nlm.nih.gov/pubmed/14726817.

36. Schafernak KT, Variakojis D, Goolsby CL, et al. Clonality assessment of cutaneous B-cell lymphoid proliferations: a comparison of flow cytometry immunophenotyping, molecular studies, and immunohistochemistry/in situ hybridization and review of the literature. Am J Dermatopathol 2014;36:781–795. Available at: https://www.ncbi.nlm.nih.gov/pubmed/24335516.

37. Murase T, Yamaguchi M, Suzuki R, et al. Intravascular large B-cell lymphoma (IVLBCL): a clinicopathologic study of 96 cases with special reference to the immunophenotypic heterogeneity of CD5. Blood 2007;109:478–485. Available at: https://www.ncbi.nlm.nih.gov/pubmed/16985183.

38. Koens L, Vermeer MH, Willemze R, Jansen PM. IgM expression on paraffin sections distinguishes primary cutaneous large B-cell lymphoma, leg type from primary cutaneous follicle center lymphoma. Am J Surg Pathol 2010;34:1043–1048. Available at: https://www.ncbi.nlm.nih.gov/pubmed/20551823.

39. Child FJ, Russell-Jones R, Woolford AJ, et al. Absence of the t(14;18) chromosomal translocation in primary cutaneous B-cell lymphoma. Br J Dermatol 2001;144:735–744. Available at: https://www.ncbi.nlm.nih.gov/pubmed/11298531.

40. Wehkamp U, Pott C, Unterhalt M, et al. Skin involvement of mantle cell lymphoma may mimic primary cutaneous diffuse large B-cell lymphoma, leg type. Am J Surg Pathol 2015;39:1093–1101. Available at: https://www.ncbi.nlm.nih.gov/pubmed/26034867.

41. Olsen EA, Whittaker S, Willemze R, et al. Primary cutaneous lymphoma: recommendations for clinical trial design and staging update from the ISCL, USCLC, and EORTC. Blood 2022;140:419–437. Available at: https://www.ncbi.nlm.nih.gov/pubmed/34758074.

42. Kheterpal MK, Dai J, Geller S, et al. Role of imaging in low-grade cutaneous B-cell lymphoma presenting in the skin. J Am Acad Dermatol 2019;81:970–976. Available at: https://www.ncbi.nlm.nih.gov/pubmed/30703460.

43. Vachhani P, Neppalli VT, Cancino CJ, et al. Radiological imaging and bone marrow biopsy in staging of cutaneous B-cell lymphoma. Br J Haematol 2019;184:674–676. Available at: https://www.ncbi.nlm.nih.gov/pubmed/29468663.

44. Kumar R, Xiu Y, Zhuang HM, Alavi A. 18F-fluorodeoxyglucose-positron emission tomography in evaluation of primary cutaneous lymphoma. Br J Dermatol 2006;155:357–363. Available at: https://www.ncbi.nlm.nih.gov/pubmed/16882175.

Version 2.2026 © 2026 National Comprehensive Cancer Network© (NCCN©), All rights reserved. NCCN Guidelines® and this illustration may not be reproduced in any form without the express written permission of NCCN.

PLEASE NOTE that use of this NCCN Content is governed by the End-User License Agreement, and you MAY NOT distribute this Content or use it with any artificial intelligence model or tool.
Printed by Galya Basol Kochav on 2/16/2026 9:44:21 AM. Copyright © 2026 National Comprehensive Cancer Network, Inc. All Rights Reserved.

45. Senff NJ, Kluin-Nelemans HC, Willemze R. Results of bone marrow examination in 275 patients with histological features that suggest an indolent type of cutaneous B-cell lymphoma. Br J Haematol 2008;142:52–56. Available at: https://www.ncbi.nlm.nih.gov/pubmed/18422781.

46. Eich HT, Eich D, Micke O, et al. Long-term efficacy, curative potential, and prognostic factors of radiotherapy in primary cutaneous B-cell lymphoma. Int J Radiat Oncol Biol Phys 2003;55:899–906. Available at: https://www.ncbi.nlm.nih.gov/pubmed/12605967.

47. Smith BD, Glusac EJ, McNiff JM, et al. Primary cutaneous B-cell lymphoma treated with radiotherapy: a comparison of the European Organization for Research and Treatment of Cancer and the WHO classification systems. J Clin Oncol 2004;22:634–639. Available at: https://www.ncbi.nlm.nih.gov/pubmed/14966086.

48. Senff NJ, Hoefnagel JJ, Neelis KJ, et al. Results of radiotherapy in 153 primary cutaneous B-Cell lymphomas classified according to the WHO-EORTC classification. Arch Dermatol 2007;143:1520–1526. Available at: https://www.ncbi.nlm.nih.gov/pubmed/18087001.

49. Pedretti S, Urpis M, Leali C, et al. Primary cutaneous non-Hodgkin lymphoma: results of a retrospective analysis in the light of the recent ILROG guidelines. Tumori 2018;104:394–400. Available at: https://www.ncbi.nlm.nih.gov/pubmed/28218382.

50. De Felice F, Grapulin L, Pieroni A, et al. Radiation therapy in indolent primary cutaneous B cell lymphoma: a single institute experience. Ann Hematol 2018;97:2411–2416. Available at: https://www.ncbi.nlm.nih.gov/pubmed/30094511.

51. Neelis KJ, Schimmel EC, Vermeer MH, et al. Low-dose palliative radiotherapy for cutaneous B- and T-cell lymphomas. Int J Radiat Oncol Biol Phys 2009;74:154–158. Available at: https://www.ncbi.nlm.nih.gov/pubmed/18834672.

52. Elsayad K, Guenova E, Assaf C, et al. Radiotherapy in cutaneous lymphomas: Recommendations from the EORTC cutaneous lymphoma tumour group. Eur J Cancer 2024;212:115064. Available at: https://www.ncbi.nlm.nih.gov/pubmed/39418694.

53. Akhtari M, Reddy JP, Pinnix CC, et al. Primary cutaneous B-cell lymphoma (non-leg type) has excellent outcomes even after very low dose radiation as single-modality therapy. Leuk Lymphoma 2016;57:34–38. Available at: https://www.ncbi.nlm.nih.gov/pubmed/25860237.

54. Senff NJ, Noordijk EM, Kim YH, et al. European Organization for Research and Treatment of Cancer and International Society for Cutaneous Lymphoma consensus recommendations for the management of cutaneous B-cell lymphomas. Blood 2008;112:1600–1609. Available at: https://www.ncbi.nlm.nih.gov/pubmed/18567836.

55. Pashtan I, Mauch PM, Chen YH, et al. Radiotherapy in the management of localized primary cutaneous B-cell lymphoma. Leuk Lymphoma 2013;54:726–730. Available at: https://www.ncbi.nlm.nih.gov/pubmed/22916994.

56. Servitje O, Muniesa C, Benavente Y, et al. Primary cutaneous marginal zone B-cell lymphoma: response to treatment and disease-free survival in a series of 137 patients. J Am Acad Dermatol 2013;69:357–365. Available at: https://www.ncbi.nlm.nih.gov/pubmed/23796549.

57. Olszewska-Szopa M, Sobas M, Laribi K, et al. Primary cutaneous indolent B-cell lymphomas - a retrospective multicenter analysis and a review of literature. Acta Oncol 2021;60:1361–1368. Available at: https://www.ncbi.nlm.nih.gov/pubmed/34346830.

58. Heinzerling LM, Urbanek M, Funk JO, et al. Reduction of tumor burden and stabilization of disease by systemic therapy with anti-CD20 antibody (rituximab) in patients with primary cutaneous B-cell lymphoma. Cancer 2000;89:1835–1844. Available at: https://www.ncbi.nlm.nih.gov/pubmed/11042581.

59. Heinzerling L, Dummer R, Kempf W, et al. Intralesional therapy with anti-CD20 monoclonal antibody rituximab in primary cutaneous B-cell lymphoma. Arch Dermatol 2000;136:374–378. Available at: https://www.ncbi.nlm.nih.gov/pubmed/10724200.

Version 2.2026 © 2026 National Comprehensive Cancer Network© (NCCN©), All rights reserved. NCCN Guidelines® and this illustration may not be reproduced in any form without the express written permission of NCCN.

PLEASE NOTE that use of this NCCN Content is governed by the End-User License Agreement, and you MAY NOT distribute this Content or use it with any artificial intelligence model or tool.
Printed by Galya Basol Kochav on 2/16/2026 9:44:21 AM. Copyright © 2026 National Comprehensive Cancer Network, Inc. All Rights Reserved.

60. Gellrich S, Muche JM, Wilks A, et al. Systemic eight-cycle anti-CD20 monoclonal antibody (rituximab) therapy in primary cutaneous B-cell lymphomas--an applicational observation. Br J Dermatol 2005;153:167–173. Available at: http://www.ncbi.nlm.nih.gov/pubmed/16029344.

61. Morales AV, Advani R, Horwitz SM, et al. Indolent primary cutaneous B-cell lymphoma: experience using systemic rituximab. J Am Acad Dermatol 2008;59:953–957. Available at: http://www.ncbi.nlm.nih.gov/pubmed/18817999.

62. Valencak J, Weihsengruber F, Rappersberger K, et al. Rituximab monotherapy for primary cutaneous B-cell lymphoma: response and follow-up in 16 patients. Ann Oncol 2009;20:326–330. Available at: https://www.ncbi.nlm.nih.gov/pubmed/18836086.

63. Nikolaou V, Koumprentziotis IA, Papadavid E, et al. Clinical features, treatment options and outcomes in primary cutaneous B-cell lymphomas: a real-world, multicenter, retrospective study. Int J Dermatol 2024. Available at: https://www.ncbi.nlm.nih.gov/pubmed/39526550.

64. Penate Y, Hernandez-Machin B, Perez-Mendez LI, et al. Intralesional rituximab in the treatment of indolent primary cutaneous B-cell lymphomas: an epidemiological observational multicentre study. The Spanish Working Group on Cutaneous Lymphoma. Br J Dermatol 2012;167:174–179. Available at: https://www.ncbi.nlm.nih.gov/pubmed/22356294.

65. Vakeva L, Ranki A, Malkonen T. Intralesional rituximab treatment for primary cutaneous B-cell lymphoma: Nine finnish cases. Acta Derm Venereol 2016;96:396–397. Available at: https://www.ncbi.nlm.nih.gov/pubmed/26525093.

66. Eberle FC, Holstein J, Scheu A, et al. Intralesional anti-CD20 antibody for low-grade primary cutaneous B-cell lymphoma: Adverse reactions correlate with favorable clinical outcome. J Dtsch Dermatol Ges 2017;15:319–323. Available at: https://www.ncbi.nlm.nih.gov/pubmed/28177583.

67. Kerl K, Prins C, Saurat JH, French LE. Intralesional and intravenous treatment of cutaneous B-cell lymphomas with the monoclonal anti-CD20 antibody rituximab: report and follow-up of eight cases. Br J Dermatol 2006;155:1197–1200. Available at: https://www.ncbi.nlm.nih.gov/pubmed/17107389.

68. Bekkenk MW, Vermeer MH, Geerts ML, et al. Treatment of multifocal primary cutaneous B-cell lymphoma: a clinical follow-up study of 29 patients. J Clin Oncol 1999;17:2471–2478. Available at: https://www.ncbi.nlm.nih.gov/pubmed/10561311.

69. Trent JT, Romanelli P, Kerdel FA. Topical targretin and intralesional interferon alfa for cutaneous lymphoma of the scalp. Arch Dermatol 2002;138:1421–1423. Available at: https://www.ncbi.nlm.nih.gov/pubmed/12437444.

70. Bachmeyer C, Orlandini V, Aractingi S. Topical mechlorethamine and clobetasol in multifocal primary cutaneous marginal zone-B cell lymphoma. Br J Dermatol 2006;154:1207–1209. Available at: https://www.ncbi.nlm.nih.gov/pubmed/16704661.

71. Coors EA, Schuler G, Von Den Driesch P. Topical imiquimod as treatment for different kinds of cutaneous lymphoma. Eur J Dermatol 2006;16:391–393. Available at: https://www.ncbi.nlm.nih.gov/pubmed/16935796.

72. Stavrakoglou A, Brown VL, Coutts I. Successful treatment of primary cutaneous follicle centre lymphoma with topical 5% imiquimod. Br J Dermatol 2007;157:620–622. Available at: https://www.ncbi.nlm.nih.gov/pubmed/17553050.

73. Perry A, Vincent BJ, Parker SR. Intralesional corticosteroid therapy for primary cutaneous B-cell lymphoma. Br J Dermatol 2010;163:223–225. Available at: https://www.ncbi.nlm.nih.gov/pubmed/20394622.

74. Kollipara R, Hans A, Hall J, Lisle A. A case report of primary cutaneous marginal zone lymphoma treated with intralesional steroids. Dermatol Online J 2015;21:13030/qt13039s15929m. Available at: https://www.ncbi.nlm.nih.gov/pubmed/26437162.

Version 2.2026 © 2026 National Comprehensive Cancer Network© (NCCN©), All rights reserved. NCCN Guidelines® and this illustration may not be reproduced in any form without the express written permission of NCCN.

PLEASE NOTE that use of this NCCN Content is governed by the End-User License Agreement, and you MAY NOT distribute this Content or use it with any artificial intelligence model or tool.
Printed by Galya Basol Kochav on 2/16/2026 9:44:21 AM. Copyright © 2026 National Comprehensive Cancer Network, Inc. All Rights Reserved.

75. Rijlaarsdam JU, Toonstra J, Meijer OW, et al. Treatment of primary cutaneous B-cell lymphomas of follicle center cell origin: a clinical follow-up study of 55 patients treated with radiotherapy or polychemotherapy. J Clin Oncol 1996;14:549–555. Available at: https://www.ncbi.nlm.nih.gov/pubmed/8636770.

76. Brice P, Cazals D, Mounier N, et al. Primary cutaneous large-cell lymphoma: analysis of 49 patients included in the LNH87 prospective trial of polychemotherapy for high-grade lymphomas. Groupe d'Etude des Lymphomes de l'Adulte. Leukemia 1998;12:213–219. Available at: https://www.ncbi.nlm.nih.gov/pubmed/9519784.

77. Wang S, Perlmutter JW, Johnston J, et al. Rituximab treatment of primary cutaneous follicle center lymphoma: A retrospective review. J Cutan Med Surg 2022;26:604–612. Available at: https://www.ncbi.nlm.nih.gov/pubmed/36134749.

78. Haverkos B, Tyler K, Gru AA, et al. Primary cutaneous B-cell lymphoma: management and patterns of recurrence at the multimodality cutaneous lymphoma clinic of the Ohio State University. Oncologist 2015;20:1161–1166. Available at: https://www.ncbi.nlm.nih.gov/pubmed/26306900.

79. Grange F, Beylot-Barry M, Courville P, et al. Primary cutaneous diffuse large B-cell lymphoma, leg type: clinicopathologic features and prognostic analysis in 60 cases. Arch Dermatol 2007;143:1144–1150. Available at: https://www.ncbi.nlm.nih.gov/pubmed/17875875.

80. Posada Garcia C, Florez A, Pardavila R, et al. Primary cutaneous large B-cell lymphoma, leg type, successfully treated with rituximab plus chemotherapy. Eur J Dermatol 2009;19:394–395. Available at: https://www.ncbi.nlm.nih.gov/pubmed/19467966.

81. Grange F, Maubec E, Bagot M, et al. Treatment of cutaneous B-cell lymphoma, leg type, with age-adapted combinations of chemotherapies and rituximab. Arch Dermatol 2009;145:329–330. Available at: https://www.ncbi.nlm.nih.gov/pubmed/19289772.

82. Grange F, Joly P, Barbe C, et al. Improvement of survival in patients with primary cutaneous diffuse large B-cell lymphoma, leg type, in France. JAMA Dermatol 2014;150:535–541. Available at: https://www.ncbi.nlm.nih.gov/pubmed/24647650.

83. Kim MJ, Hong ME, Maeng CH, et al. Clinical features and treatment outcomes of primary cutaneous B-cell lymphoma: a single-center analysis in South Korea. Int J Hematol 2015;101:273–278. Available at: https://www.ncbi.nlm.nih.gov/pubmed/25552248.

84. Kraft RM, Ansell SM, Villasboas JC, et al. Outcomes in primary cutaneous diffuse large B-cell lymphoma, leg type. Hematol Oncol 2021;39:658–663. Available at: https://www.ncbi.nlm.nih.gov/pubmed/34453851.

Version 2.2026 © 2026 National Comprehensive Cancer Network© (NCCN©), All rights reserved. NCCN Guidelines® and this illustration may not be reproduced in any form without the express written permission of NCCN.

PLEASE NOTE that use of this NCCN Content is governed by the End-User License Agreement, and you MAY NOT distribute this Content or use it with any artificial intelligence model or tool.
Printed by Galya Basol Kochav on 2/16/2026 9:44:21 AM. Copyright © 2026 National Comprehensive Cancer Network, Inc. All Rights Reserved.

This discussion corresponds to the NCCN Guidelines for Cutaneous Lymphomas. Last updated: February 13, 2026.

Mycosis Fungoides and Sézary Syndrome

Overview

Cutaneous T-cell lymphomas (CTCL) are a group of non-Hodgkin lymphomas (NHL) that primarily present in the skin, and at times progress to involve lymph nodes, blood, and visceral organs.[1-3] Mycosis fungoides (MF) is the most common subtype and is usually associated with an indolent clinical course with intermittent, stable, or slow progression of the lesions.[4,5]

Extracutaneous involvement (lymph nodes, blood, or less commonly other organs) or large cell transformation (LCT) may be seen in advanced-stage disease. Sézary syndrome (SS) is a rare erythrodermic, leukemic variant characterized by significant blood involvement, erythroderma, and often lymphadenopathy.[4,6,7] MF is caused by the malignant transformation of skin-resident effector memory T cells while SS is thought to arise from thymic memory T cells, supporting the contention that SS is a process distinct from MF.[6] Cases presenting as an overlap of these two conditions also exist.

Folliculotropic MF (FMF), hypopigmented MF, granulomatous slack skin, and pagetoid reticulosis are recognized as distinct clinicopathologic variants of MF in the World Health Organization-European Organization for Research and Treatment of Cancer (WHO-EORTC) classification.[2] FMF and LCT are histologic features that can occur irrespective of stage, but the incidence of LCT is higher in patients with advanced-stage disease.[8-10] Expert dermatopathology and/or hematopathology review is needed to confirm the diagnosis. This is especially true for the less common variants of the disease, which can be difficult to distinguish from other lymphoproliferative disorders. Genomic studies have demonstrated further biologic diversity within MF.[4,11]

Due to the rarity and diversity of the condition and the need for an individualized approach, the NCCN Guidelines Panel recommends that patients diagnosed with MF and SS be treated at specialized centers with expertise in the management of this disease.[12]

Literature Search Criteria

Prior to the update of this version of the NCCN Clinical Practice Guidelines in Oncology (NCCN Guidelines®) for Primary Cutaneous Lymphomas, an electronic search of the PubMed database was performed to obtain key literature on MF and SS published since the previous Guidelines update using the following search terms: cutaneous T-cell lymphomas, mycosis fungoides, and Sézary syndrome. The PubMed database was chosen as it remains the most widely used resource for medical literature and indexes peer-reviewed biomedical literature.[13]

The search results were narrowed by selecting studies in humans published in English. Results were confined to the following article types: Clinical Trial, Randomized Controlled Trial; Phase II; Clinical Trial, Phase III; Guideline; Meta Analysis; Systematic Reviews; and Validation Studies. The data from key PubMed articles deemed as relevant to these guidelines have been included in this version of the Discussion section. Recommendations for which high-level evidence is lacking are based on the Panel's review of lower-level evidence and expert opinion.

The complete details of the Development and Update of the NCCN Guidelines are available at www.NCCN.org.

Staging

The T (skin), N (node), M (visceral), and B (blood involvement) classification and clinical staging developed by the International Society

Version 2.2026 © 2026 National Comprehensive Cancer Network© (NCCN©), All rights reserved. NCCN Guidelines® and this illustration may not be reproduced in any form without the express written permission of NCCN.

PLEASE NOTE that use of this NCCN Content is governed by the End-User License Agreement, and you MAY NOT distribute this Content or use it with any artificial intelligence model or tool.
Printed by Galya Basol Kochav on 2/16/2026 9:44:21 AM. Copyright © 2026 National Comprehensive Cancer Network, Inc. All Rights Reserved.

for Cutaneous Lymphomas (ISCL) and EORTC are outlined on MFSS-3 and MFSS-4.[14]

The extent of skin involvement is based on the percentage of body surface area (BSA) where the patient's palm (without digits) is equivalent to 0.5% BSA and the palm with all five digits is approximately 1% BSA. In the revised staging system, T1 disease (limited skin involvement) is defined as patches, papules, and/or plaques covering <10% BSA. T2 (skin-only disease) is defined as patches, papules, and/or plaques covering ≥10% BSA. Patch diagnosis is noted as T1a or T2a and plaque diagnosis is noted as T1b or T2b. T3 (tumor-stage disease) is defined by the presence of one or more tumors (≥1 cm in diameter with nodular quality). T4 (erythrodermic disease) is defined as confluence of erythema covering ≥80% BSA. However, this criterion of 80% is subjective and the BSA can fluctuate in patients with erythrodermic MF or SS. Thus, other features including keratoderma, ectropion, or leg edema should also be evaluated in patients with erythrodermic MF or SS.

Lymph node biopsy for staging is recommended only for clinically abnormal nodes (>1.5 cm in longest diameter). Lymphadenopathy can be clinically reactive or dermatopathic; thus, not all enlarged lymph nodes are sampled. The designation "Nx" may be used for abnormal lymph nodes without histologic evaluation. The designation "Mx" can be used for presence of abnormal visceral sites without histologic evaluation. Visceral disease with the involvement of an organ (eg, spleen, liver) other than the skin, nodes, or blood should be documented using imaging studies.

Blood involvement is classified into three groups: B0, B1, and B2 based on the number of immunophenotypically abnormal T cells in the blood (MFSS-3). Patients with lymphopenia (defined as <1000 absolute lymphocytes) may potentially have an underestimation of aberrant lymphocyte burden if assessed only by the absolute number and not also by the percentage of immunophenotypically abnormal lymphocytes.[14] B1 or B2 is best characterized by both flow cytometry and the presence of clonally related neoplastic T cells as in the skin by *TCR* gene rearrangement analysis. A diagnosis of SS requires B2 level of blood involvement.

Prognosis

Age at presentation, overall stage, extent and type of skin involvement (T classification), presence of extracutaneous disease, extent of peripheral blood involvement (as defined by flow cytometric measurements of Sézary cell counts), elevated lactate dehydrogenase (LDH), and presence of LCT have been identified as the most significant factors for disease progression and/or survival in patients with MF.[15-21] In a retrospective cohort study of 525 patients with MF or SS, patient age, T classification, and presence of extracutaneous disease retained independent prognostic value in a multivariate analysis.[16] The risk of disease progression, development of extracutaneous disease, or death due to MF correlated with initial T classification. Limited patch or plaque disease has an excellent prognosis compared to patients with widespread plaque-type or tumor-type skin disease or erythrodermic skin involvement, and extracutaneous disease is associated with a poor prognosis.[18,19]

LCT is also an independent prognostic factor of shorter overall survival (OS) in patients with SS. In an analysis of 117 patients with SS, LCT was present in 6% of patients at the time of diagnosis and the median OS was 35 months for those with LCT compared to 80 months for those without LCT.[22] The presence of ulceration, decreased levels of CD8+ cells in peripheral blood, maximum total BSA, and peak LDH were predictors for LCT in patients with SS.[23]

In the Cutaneous Lymphoma International Consortium (CLIC) study that evaluated the relevance of prognostic markers on OS in 1275 patients with advanced-stage MF and SS, stage IV disease, aged 60 years, LCT and

Version 2.2026 © 2026 National Comprehensive Cancer Network© (NCCN©), All rights reserved. NCCN Guidelines® and this illustration may not be reproduced in any form without the express written permission of NCCN.

PLEASE NOTE that use of this NCCN Content is governed by the End-User License Agreement, and you MAY NOT distribute this Content or use it with any artificial intelligence model or tool.
Printed by Galya Basol Kochav on 2/16/2026 9:44:21 AM. Copyright © 2026 National Comprehensive Cancer Network, Inc. All Rights Reserved.

LDH levels were identified as independent prognostic markers that could be used together in a prognostic model to identify three risk groups with significantly different survival outcomes.[21] The 5-year survival rates were 68%, 44%, and 28%, respectively, for low-risk, intermediate-risk, and high-risk groups. A prospective international study by CLIC (Prospective Cutaneous Lymphoma International Prognostic Index [PROCLIPI] international study) is underway to identify any new prognostic markers and validate the refined prognostic index model to optimize the risk-stratified approach for the treatment of patients with MF or SS.[24-26]

Diagnosis

Biopsy of suspicious skin sites along with immunohistochemistry (IHC) of biopsy specimen are essential to confirm the diagnosis. Biopsy of enlarged lymph nodes (ie, palpable nodes >1.5 cm in diameter and/or firm, irregular, clustered, or fixed nodes) or extracutaneous sites is recommended. Excisional or incisional biopsy is preferred over core needle biopsy. Fine-needle aspiration (FNA) alone is not sufficient for the initial diagnosis. Bone marrow biopsy is not required for disease staging but may be helpful in those with an unexplained hematologic abnormality.

MF and SS cells are typically characterized by the following immunophenotype: CD2+, CD3+, CD5+, CD4+, CD8-, CCR4+, TCR-beta+, and CD45RO+ and they lack certain T-cell markers, CD7 and CD26.[27] However, there are variants of MF that are CD8+ (especially the hypopigmented variant) or CD4/CD8 dual negative (in those with LCT and hypopigmented variant), although rare.[28-30] The IHC panel of skin biopsy should include CD2, CD3, CD4, CD5, CD7, CD8, CD20, and CD30.

Additional immunohistochemical markers such as CD25, CD56, TIA1, granzyme B, TCR beta, and TCR delta may be useful in selected circumstances. The loss of CCR4 expression and emergence of CCR4 genomic alterations might be associated with resistance to mogamulizumab.[31] IHC for CCR4 may be useful to confirm resistance to mogamulizumab in patients with progressive or refractory disease while on treatment with mogamulizumab.

Molecular analysis to detect clonal *TCR* gene rearrangements is useful to support the diagnosis of MF and SS as well as to distinguish MF from inflammatory dermatoses, especially if identical clones are demonstrated in more than one skin site.[32,33] However, results showing clonal *TCR* gene rearrangements should not be interpreted as the sole and defining test for malignancy since clonal *TCR* rearrangements can at times be seen in non-malignant conditions or may not be demonstrated in all cases of MF and SS. *TCR* rearrangement analysis by high throughput sequencing (or next-generation sequencing) is a more sensitive and specific test of clonality that can identify the clones by the genetic sequence of the *TCR*.[34,35] Demonstration of identical clones in the skin, blood, and/or lymph nodes may be helpful both for diagnosis and differentiating MF and SS from benign inflammatory skin diseases.

Assessment of peripheral blood involvement optimally by flow cytometry is important for staging and is also useful to differentiate CTCL with peripheral blood involvement from other forms of leukemic T-cell lymphomas (eg, T-cell prolymphocytic leukemia, lymphocytic variant of hypereosinophilic syndrome, adult T-cell leukemia/lymphoma [ATLL]). Flow cytometry allows for the assessment and quantitation of an expanded population of CD4+ cells with abnormal immunophenotype (CD4+/CD26- or CD4+/CD7- or other aberrantly expressed phenotype).[36] Assessment of TRBC1 expression by flow cytometry is also useful for the detection of clonality, especially in cases where CD7 or CD26 are not lost.[37-39] Human T-cell lymphotrophic virus (HTLV)-1 status, assessed either by HTLV-1 serology or other methods, may be useful in populations at risk to exclude the diagnosis of ATLL (which is usually HTLV-1–positive).

Version 2.2026 © 2026 National Comprehensive Cancer Network© (NCCN©), All rights reserved. NCCN Guidelines® and this illustration may not be reproduced in any form without the express written permission of NCCN.

PLEASE NOTE that use of this NCCN Content is governed by the End-User License Agreement, and you MAY NOT distribute this Content or use it with any artificial intelligence model or tool.
Printed by Galya Basol Kochav on 2/16/2026 9:44:21 AM. Copyright © 2026 National Comprehensive Cancer Network, Inc. All Rights Reserved.

When appropriate, IHC with expanded immunohistochemical markers and multigene panel testing may be helpful under certain circumstances to confirm the diagnosis of subtypes of CTCL.[40-45]

Workup

The initial workup of patients diagnosed with MF or SS involves a history and complete skin examination (assessment of the extent of disease [ie, percent of BSA] and type of skin lesion [eg, patch/plaque, tumor, erythroderma]), palpation of peripheral lymph nodes, and palpation for organomegaly.[14]

Laboratory studies should include a complete blood count (CBC), Sézary flow cytometric study (optional for T1 disease), comprehensive metabolic panel, and assessment of LDH levels. Analysis of clonal *TCR* gene arrangement of peripheral blood lymphocytes is recommended if blood involvement is suspected.

CT with contrast of the chest, abdomen, and pelvis or integrated whole-body PET/CT scan is recommended for patients with T3 or T4 disease and should be considered for patients with T2a (patch disease with ≥10% BSA), T2b (widespread plaque-type skin disease), FMF or LCT, palpable adenopathy, or abnormal laboratory studies. In an analysis of 375 patients with stage T1/T2 MF enrolled in the PROCLIPI international study, the presence of plaques was associated with a significant increase in the identification of radiologically enlarged or involved lymph nodes in patients with early-stage MF.[25]

A CT scan of the neck may be useful in some circumstances. Integrated PET/CT was found to be more sensitive for the detection of lymph node involvement than CT alone and can help direct biopsies.[46] PET scan may also be preferred in patients with extranodal disease that may be inadequately imaged by CT. Many skin-directed and systemic therapies are contraindicated or are of unknown safety in pregnancy. Therefore, pregnancy testing is recommended for individuals of childbearing age.

Treatment Considerations

While MF and SS are treatable, they are not curable with conventional systemic therapy, and the symptoms of the disease have significant impact on the quality of life. Patients with MF, particularly those with early-stage disease, can have very good prognosis and may live with the disease for decades.[18,19]

The optimal treatment for any patient at any given time should be individualized based on overall goals of therapy (improve the disease burden and quality of life, attain adequate response to reduce/control symptoms, and minimize the risk of progression), route of administration, and toxicity profile. Discussions regarding cumulative toxicity of therapy, impact of therapy on quality of life, and supportive care for symptom control are a key part of the treatment of patients with MF and SS. Most of the treatment options do not result in durable remissions and are often given in an ongoing or maintenance fashion to achieve disease control with as little impact on quality of life as possible.

Patients with a clinical benefit and/or those with disease responding to primary treatment can be considered for maintenance or tapering of regimens to optimize response duration. Patients with disease that does not have adequate response to a systemic therapy regimen are generally treated with an alternative regimen recommended for primary treatment before moving on to treatment for refractory disease. This supports the therapeutic principle of initial treatment with less toxic regimens before moving on to treatment options that carry a higher risk of cumulative toxicity and/or immunosuppression. Disease relapse (with the same stage) after discontinuation of therapy often responds well to retreatment with previous therapy.

Version 2.2026 © 2026 National Comprehensive Cancer Network© (NCCN©), All rights reserved. NCCN Guidelines® and this illustration may not be reproduced in any form without the express written permission of NCCN.

PLEASE NOTE that use of this NCCN Content is governed by the End-User License Agreement, and you MAY NOT distribute this Content or use it with any artificial intelligence model or tool.
Printed by Galya Basol Kochav on 2/16/2026 9:44:21 AM. Copyright © 2026 National Comprehensive Cancer Network, Inc. All Rights Reserved.

Selection of Therapy Based on Clinical and Pathologic Features

Skin-directed therapies (topical therapy, phototherapy, radiation therapy [RT], or total skin electronic beam therapy [TSEBT]) that can provide disease control without major cumulative toxicities are recommended for patients with early-stage disease and limited skin involvement (stage IA or stage IB–IIA). Stage IA MF most often can be treated with skin-directed therapies (alone or in combination with other skin-directed therapies). While stage IB–IIA patch/plaque disease can be effectively treated predominantly with skin-directed therapies, systemic therapy can be considered for stage IB–IIA with higher skin disease burden, concerning pathologic features (eg, LCT or FMF), predominantly plaque disease, and/or inadequate response to skin-directed therapy.

Systemic therapy is recommended for advanced-stage disease (≥ stage IIB). However, patients with stage IIB disease with single or few T3 lesions can be treated with external beam RT (EBRT) with further delay of systemic therapy and TSEBT may be used for patients with stage IB–IIB disease, with excellent response expected. In the PROCLIPI study, the use of systemic therapy was significantly associated with higher clinical stage, presence of plaques, and FMF.[26] In a multivariate analysis, the presence of plaques and FMF were significantly associated with the use of systemic therapy, and skin-directed therapy was superior to systemic therapy even in patients with these disease characteristics. The overall response rate (ORR) to first-line skin-directed therapy was 73% compared to 57% for systemic therapy.

Systemic therapy can be and often is combined with skin-directed therapy to maximize clinical responses in the skin compartment and also to provide additive efficacy without cumulative toxicities. For those who require systemic therapy, due to either advanced-stage disease or inadequate disease control on skin-directed therapy, there are many options; however, given the rare nature of this disease, only a few have been evaluated in randomized studies, as discussed in the section *Systemic Therapies*. Therefore, a clinical trial should be considered when appropriate and available.

Data from clinical trials that have evaluated various treatment strategies (skin-directed therapy, systemic therapy, and combination therapies) are discussed below.

Skin-Directed Therapies

Topical therapy with corticosteroids, mechlorethamine (nitrogen mustard), topical retinoids or topical imiquimod, or RT are indicated for patients with localized disease. Phototherapy and TSEBT are indicated for patients with widespread skin involvement. Topical retinoids are not recommended for generalized skin involvement because these treatments can cause substantial irritation.

Topical Corticosteroids

Topical corticosteroids are effective for early-stage MF (especially for the treatment of patch-stage MF), resulting in measurable improvement in BSA involvement and high ORR of 94% (63% complete response [CR]; 13% partial response [PR]) and 82% (25% CR; 57% PR) in patients with stage T1 and T2 disease, respectively.[47-49]

Optimal use of topical steroids is often dependent on lesion type and disease site. This is best done in consultation with a dermatologist or physician with experience in the use of topical steroids. In general, high-potency steroids may be less well-tolerated in intertriginous body areas or other areas such as the face. Long-term use of a topical steroid may lead to skin atrophy or striae formation, and the risk becomes greater with increased potency of the steroid. Moreover, high-potency steroids used on large skin surfaces may lead to systemic absorption.

Version 2.2026 © 2026 National Comprehensive Cancer Network© (NCCN©), All rights reserved. NCCN Guidelines® and this illustration may not be reproduced in any form without the express written permission of NCCN.

PLEASE NOTE that use of this NCCN Content is governed by the End-User License Agreement, and you MAY NOT distribute this Content or use it with any artificial intelligence model or tool.
Printed by Galya Basol Kochav on 2/16/2026 9:44:21 AM. Copyright © 2026 National Comprehensive Cancer Network, Inc. All Rights Reserved.

Topical Mechlorethamine (nitrogen mustard)

Topical mechlorethamine has been used for the management of MF for many decades resulting in an ORR of 83% (50% CR). Patients with T1 disease had a higher ORR (93% vs. 72%), CR rate (65% vs. 34%), longer median OS (21 vs. 15 months), and higher 5-year OS rate (97% vs. 72%) than those with T2 disease.[50] The efficacy was similar for aqueous and ointment preparations, although the ointment was associated with reduced hypersensitivity reactions.

A topical gel formulation of mechlorethamine was approved by the U.S. Food and Drug Administration (FDA) in 2013 based on the results of a multicenter, randomized, phase II trial that demonstrated the noninferiority of topical gel formulation compared to the compounded ointment formulation for the treatment of stage IA or IIA MF in patients (n = 260) who had not been treated with topical mechlorethamine within 2 years of study enrollment and had not received prior therapy with topical mechlorethamine.[51] Response rate based on Composite Assessment of Index Lesion Severity was 59% for the topical gel formulation compared to 48% for the ointment formulation. No study treatment-related serious adverse events were reported, and no systemic absorption was detected.

Topical mechlorethamine has no significant systemic absorption, and can be used alone or in combination with other skin directed therapies, in particular topical steroids. The use of topical gel formulation of mechlorethamine can be complicated by dermatitis and can result in skin irritation when used on the face and intertriginous body areas. Initiation at less than daily use can be useful to determine tolerability. Topical steroids can be considered as needed to alleviate skin reactions from topical gel formulation. If used in combination with phototherapy, topical mechlorethamine gel should be applied after exposure to ultraviolet light. Topical mechlorethamine is prohibited in the genital skin.

Topical Retinoids

Bexarotene gel is the only FDA-approved synthetic topical retinoid for the treatment of MF and SS. In the phase I–II trial of 67 patients with early-stage MF, the ORR was 63% (21% CR) and the estimated median response duration was 99 weeks.[52] Response rates were higher among the patients who had had no prior therapy compared with those who had received prior topical therapies (75% vs. 67%). In the phase III multicenter study of 50 patients with early-stage refractory MF, the ORR was 44% (8% CR).[53]

Tazarotene 0.1% topical gel/cream was reported to be a well-tolerated and active adjuvant therapy by clinical and histologic assessments in a small series of patients with early patch or plaque MF lesions (stable or refractory to therapy).[54,55]

Topical Imiquimod

Imiquimod has also demonstrated activity in a small number of patients with early-stage MF refractory to other therapies.[56-59] Topical imiquimod can be considered (often in consultation with a dermatologist or physician with experience in its safety and use) for areas with few patches/plaques/small tumors that are recalcitrant to treatment or on sun-damaged skin such as forearms, scalp, and face.

Topical Carmustine

Topical carmustine is an effective treatment for patch/plaque early-stage MF resulting in high response rates of 92% and 64% in patients with T1 and T2 disease, respectively, at 36 months.[60,61] Topical carmustine is included with a category 2B recommendation.

Topical Calcineurin Inhibitors

In a phase II multicenter study of 39 patients with stage IA–IIA MF, topical pimecrolimus (1% cream) resulted in an ORR of 56% and was well

Version 2.2026 © 2026 National Comprehensive Cancer Network© (NCCN©), All rights reserved. NCCN Guidelines® and this illustration may not be reproduced in any form without the express written permission of NCCN.

PLEASE NOTE that use of this NCCN Content is governed by the End-User License Agreement, and you MAY NOT distribute this Content or use it with any artificial intelligence model or tool.
Printed by Galya Basol Kochav on 2/16/2026 9:44:21 AM. Copyright © 2026 National Comprehensive Cancer Network, Inc. All Rights Reserved.

tolerated (grade 1 transient mild burning or pruritus was the most common adverse event reported in 21% of patients).[62]

The safety and efficacy of tacrolimus (0.1% ointment) in patients with stage IA and IB MF has been evaluated in a small retrospective study (n = 13).[63] Topical tacrolimus was administered to patients with early stage MF over 20 years with no worsening or recurrence. Disease progression was reported in a minority (8%) of patients with no apparent negative impact on 12-month PFS and OS.

Topical calcineurin inhibitors can be considered for patients with early-stage MF as a steroid-sparing treatment and should be considered particularly for facial and genital skin and skin folds.

Radiation Therapy

MF is extremely radiosensitive and unilesional or stage IA MF may be treated effectively with local RT alone (without adjuvant therapy), resulting in an ORR of 97% to 100%.[64,65] Recent studies have shown that low-dose involved-field RT (IFRT) also results in high response rates without any toxicity in patients with MF.[65-67] In a study that included 31 patients with MF, low-dose RT (4 Gy in 2 fractions) resulted in a CR rate of only 30%, whereas increasing the dose to 8 Gy in two fractions yielded a CR rate of 92%.[66] Patients with disease not responding to low-dose RT were re-treated with 20 Gy in eight fractions. In a large series of 58 patients treated with 8 Gy in a single fraction, the CR rate was 94% for individual lesions after a median follow-up of 41 months.[67]

Optimal management of individual plaque and tumor lesions is with EBRT (8–12 Gy, 8 Gy may be given in a single-fraction; 24–30 Gy is recommended for more durable duration of response or for unilesional presentation).[65,67,68]

Total Skin Electron Beam Therapy

TSEBT (conventional dose [30–36 Gy] or low dose [<30 Gy]) either alone or in combination with adjuvant therapy has been shown to be effective for the treatment of early-stage MF.[69-72] TSEBT at a conventional dose of ≥30 Gy was associated with a non-significant trend towards better clinical benefit and was also associated with better outcomes in patients with T2 disease compared to those with T3 disease.[71,72] In a retrospective study that evaluated low-dose TSEBT in 102 patients with T2 to T4 disease (excluding those with extracutaneous disease), TSEBT doses of 10 to <20 Gy and 20 to <30 Gy resulted in ORRs of 98% and 97%, respectively, which were comparable to the ORRs achieved with standard-dose TSEBT (≥30 Gy).[70] The OS and progression-free survival (PFS) rates were not significantly different by dose groups and were comparable to that of standard-dose TSEBT (≥30 Gy).

Lower-dose TSEBT (10–12 Gy over a period of 2–3 weeks) is shown to be sufficiently active and may also be associated with fewer short-term complications and better ability to re-treat progressive disease (PD) or cutaneous relapses.[73-78] A pooled analysis of three phase II clinical trials that evaluated low-dose TSEBT (12 Gy; 1 Gy per fraction over 3 weeks) in 33 patients with MF reported an ORR of 88% (including 9 patients with a CR).[74] The median time to response and median duration of clinical benefit were 8 weeks and 71 weeks. In a cohort of 103 patients with MF treated with low-dose TSEBT (12 Gy in 8 fractions for 2 weeks; the majority of patients had stage IB or IIB disease), after a median follow-up of 21 months, the ORR was 87% (18% CR and 69% PR) and the median PFS was 13 months.[77] The median PFS was significantly longer for patients with stage IB disease (27 months) compared to 11 months and 10 months, respectively, for those with stage IIB or stage III disease. Low-dose TSEBT (12 Gy in 6–7 fractions) was also associated with favorable outcomes and significantly fewer grade 2 acute toxicities compared with conventional-dose TSEBT (30 Gy).[76,79,80] Further studies

Version 2.2026 © 2026 National Comprehensive Cancer Network© (NCCN©), All rights reserved. NCCN Guidelines® and this illustration may not be reproduced in any form without the express written permission of NCCN.

PLEASE NOTE that use of this NCCN Content is governed by the End-User License Agreement, and you MAY NOT distribute this Content or use it with any artificial intelligence model or tool.
Printed by Galya Basol Kochav on 2/16/2026 9:44:21 AM. Copyright © 2026 National Comprehensive Cancer Network, Inc. All Rights Reserved.

are warranted to confirm these findings and the use of low-dose TSEBT in combined modality regimens.

The recommended dose range for TSEBT is 12 to 36 Gy (generally 4–6 Gy per week). Lower total dose is associated with fewer short-term complications and better ability for the retreatment of relapsed disease. It is common practice to follow TSEBT with systemic therapies such as interferon (IFN) or bexarotene to maintain response, for patients with stage IB–IIA disease with higher skin disease burden. Adjuvant systemic therapy can be considered to improve response rate and PFS in patients with stage IIB (tumor stage) disease receiving TSEBT.[81,82]

TSEBT may not be well tolerated in patients with erythrodermic disease and should be used with caution. In these patients, TSEBT may be used with lower doses and slower fractionation. Antibiotic therapy should be considered since patients with erythrodermic disease are at increased risk of developing secondary infections.

Phototherapy

Ultraviolet B (UVB including narrowband-UVB)[83-87] and psoralen plus ultraviolet A1 (PUVA/UVA-1)[88-91] are effective treatment options for patients with early-stage MF. Narrowband UVB is the most common phototherapy approach and is less skin damaging than PUVA/UVA-1. While some retrospective studies have reported that PUVA results in better responses and improved disease-free survival (DFS),[92-94] others have reported that UVB is as effective as PUVA for the treatment of early-stage MF.[95,96] However, these modalities have not been compared in randomized clinical trials.

PUVA may be associated with a small increase in the risk of developing basal cell carcinoma (BCC), while there was no significant association between the use of narrowband UVB and the risk of developing BCC, squamous cell carcinoma (SCC), or melanoma.[97] More recent reports also confirmed that the use of UV radiation (including UVA and narrowband UVB) was not associated with an increased risk of developing BCC, SCC, or melanoma except in patients receiving immunosuppressive therapy.[98,99] It may be more beneficial to start with narrowband UVB than PUVA in patients with early patch-stage or thin-plaque disease, since narrowband UVB has less skin toxicity than broadband UVB and PUVA.[97,100,101]

Phototherapy should be used with caution in patients with a history of immunosuppressive medication due to the increased risk of UV radiation-associated skin malignancies in this patient population. The risk and benefits of phototherapy should be considered in patients with a history of BCC, SCC, or melanoma. There are limited safety data for the use of phototherapy in combination with vorinostat or romidepsin. Patients on long-term phototherapy should be carefully monitored for the development of actinic keratoses, BCC, SCC, or melanoma. The general principles and dosing guidelines for phototherapy are outlined in the *Principles of Phototherapy* section in the algorithm.

Systemic Therapies

The selection of systemic therapy regimens is dependent on clinical (eg, extent of patch/plaques; disease burden profile in the skin, lymph nodes, and blood; prior therapies; and comorbidities) and pathologic features (eg, LCT or FMF) and IHC data (eg, CD30 positivity).[102] In general, systemic therapy regimens that can be tolerated for longer durations of therapy with lower rates of cumulative toxicity, less immunosuppression, and/or higher efficacy are used in earlier lines of therapy. Regimens with lower side-effect profiles and an absence of cumulative toxicity are often given in an ongoing or maintenance fashion to improve and maintain disease control and quality of life. In patients requiring chemotherapy, single agents are preferred over combination chemotherapy, due to the higher

Version 2.2026 © 2026 National Comprehensive Cancer Network© (NCCN©), All rights reserved. NCCN Guidelines® and this illustration may not be reproduced in any form without the express written permission of NCCN.

PLEASE NOTE that use of this NCCN Content is governed by the End-User License Agreement, and you MAY NOT distribute this Content or use it with any artificial intelligence model or tool.
Printed by Galya Basol Kochav on 2/16/2026 9:44:21 AM. Copyright © 2026 National Comprehensive Cancer Network, Inc. All Rights Reserved.

toxicity profiles associated with multiagent regimens and the short-lived responses seen with time-limited combination chemotherapy.

Brentuximab vedotin, bexarotene, histone deacetylase (HDAC) inhibitors (vorinostat and romidepsin), methotrexate, pralatrexate, mogamulizumab, alemtuzumab, and pembrolizumab are effective systemic therapy options for patients with advanced MF and SS. Bexarotene, brentuximab vedotin, mogamulizumab, vorinostat, romidepsin, and denileukin diftitox are approved by the FDA for the treatment of MF and SS. The efficacy of brentuximab vedotin and mogamulizumab compared to standard therapy has been demonstrated in phase III randomized trials (ALCANZA and MAVORIC, respectively).[103-105] The safety and efficacy of reformulated version of denileukin diftitox was demonstrated in study 302.[106] Bexarotene,[107,108] vorinostat,[109-111] romidepsin,[112-114] and other systemic therapies such as pralatrexate,[115-117] alemtuzumab,[118-123] and pembrolizumab[124] have been evaluated only in phase II studies.

IFNs (alfa and gamma) and methotrexate also offer clinical benefit but have not been evaluated in phase II studies in the era of modern staging of MF and SS.[125-128] IFN alfa is no longer commercially available. Peginterferon alfa-2a or ropeginterferon alfa-2b (if peginterferon alfa-2a is unavailable) may be substituted for other IFN preparations.[129-135]

Extracorporeal photopheresis (ECP) is an immunomodulatory therapy in which patient's leukocytes are removed by leukapheresis, treated extracorporeally with 8-methoxypsoralen and UVA, and then returned to the patient.[136-138] ECP may be a more appropriate systemic therapy for patients with some level of blood involvement (B1 or B2).

Gemcitabine[139-146] and pegylated liposomal doxorubicin[146-151] also have substantial activity in patients with advanced MF and SS. Multiagent chemotherapy regimens used for the treatment of systemic PTCLs have activity but are associated with greater toxicity and a potentially higher risk of death when used in earlier lines of treatment.[152,153] Therefore, multiagent chemotherapy regimens are generally reserved only for refractory disease to multiple prior therapies or bulky lymph node or solid organ disease, and/or as a bridge to allogeneic hematopoietic cell transplant (HCT).

Data supporting the use of some of these agents in patients with MF and SS are discussed below. The data for systemic therapy agents, particularly those studied in larger prospective phase II and III studies, are also summarized in Table 1.

Systemic Retinoids

Bexarotene, an oral retinoid, can have prolonged disease control without cumulative toxicity and is often considered for patients with higher skin burden with plaque disease.[107,108] In phase II–III studies, oral bexarotene (≥300 mg/m^2) was well tolerated, resulting in an ORR of 45% to 67% in patients with early-stage and advanced-stage disease.[107,108] Results from a retrospective study of the Spanish Working Group of Cutaneous Lymphomas (174 patients with MF and 42 patients with SS) also demonstrated the long-term safety and efficacy of bexarotene (ORR of 70%; 26% CR).[154] Hypertriglyceridemia (79%), hypercholesterolemia (71%), and hypothyroidism (52%) were the most common treatment-related adverse events.

Given the favorable tolerability profile without significant cumulative toxicity, bexarotene should be considered for patients with early-stage MF who have insufficient disease control with skin-directed therapy. It is important to note that bexarotene is associated with hypertriglyceridemia and central hypothyroidism, which necessitates laboratory monitoring for triglycerides, and free thyroxine (T4), often requiring additional management.

Version 2.2026 © 2026 National Comprehensive Cancer Network© (NCCN©), All rights reserved. NCCN Guidelines® and this illustration may not be reproduced in any form without the express written permission of NCCN.

PLEASE NOTE that use of this NCCN Content is governed by the End-User License Agreement, and you MAY NOT distribute this Content or use it with any artificial intelligence model or tool.
Printed by Galya Basol Kochav on 2/16/2026 9:44:21 AM. Copyright © 2026 National Comprehensive Cancer Network, Inc. All Rights Reserved.

Bexarotene is also used in combination with phototherapy or ECP for early-stage disease with inadequate response to single-agent therapy and in patients with advanced-stage disease.[155-158]

Retinoic-acid receptor (RAR) agonists such as acitretin and isotretinoin (13-cis-retinoic acid) have also been shown to be effective for the treatment of early-stage MF.[159-161] In a small cohort of 35 patients with early-stage MF, acitretin and isotretinoin resulted in ORRs of 64% and 80%, respectively (although the CR rates were low at 4% and 8%, respectively).[160]

Brentuximab Vedotin

In the ALCANZA trial, brentuximab vedotin, an anti-CD30 antibody drug conjugate, was more effective than methotrexate or bexarotene in patients with previously treated MF (≥ stage IB).[103] The final analysis confirmed that brentuximab vedotin resulted in significantly improved ORR lasting for at least 4 months (ORR4; 55% vs.13%), median PFS (17 vs. 4 months), and patient-reported symptom burden compared to methotrexate or bexarotene in patients with CD30-positive MF.[104] Peripheral neuropathy was the most common adverse event reported in 44 (69%) patients. At the median follow-up of 46 months, 86% (38 of 44) of patients had complete resolution or improvement to grades 1 and 2.

In the ALCANZA trial, CD30 positivity was defined as CD30 expression in ≥10% of total lymphoid cells in at least one skin biopsy (43% of patients had at least 1 sample with CD30 <10%).[103] The results of an exploratory analysis showed that brentuximab vedotin resulted in higher ORR4 and improved PFS in patients with ≥10% CD30 expression, regardless of LCT status.[162] The ORR4 (41% vs. 10% for <10% $CD30_{min}$ expression; 57% vs. 10% for ≥10% $CD30_{min}$ expression) and median PFS (17 vs. 2 months for <10% $CD30_{min}$ expression; 16 vs. 4 months for ≥10% $CD30_{min}$ expression) were significantly higher for brentuximab vedotin compared to vorinostat across all CD30 expression levels.

In other phase II studies, clinical responses with brentuximab vedotin were observed across all CD30 expression levels (including negligible CD30 expression) and in patients with high blood Sézary cell count.[163,164] Lesions with <5% CD30 expression had a lower likelihood of global response than those with ≥5% CD30 expression ($P < .005$), but responses are still seen in those with CD30 positivity of ≥1% or non-detectable CD30 by IHC using light microscopy.[163,164] While responses were observed in patients with very low or absent CD30 expression, the likelihood and/or depth of response may be lower in these situations and further studies are needed to define the activity of brentuximab in this setting. Real world cohort studies have also reported favorable outcomes with brentuximab vedotin in patients with previously treated MF and SS and variable CD30 positivity.[165,166]

Brentuximab vedotin is a more effective treatment option than methotrexate or bexarotene for patients with CD30-positive MF but carries greater risk, particularly a cumulative risk of peripheral neuropathy.[167] Patients with SS were excluded from the ALCANZA trial and the efficacy of brentuximab vedotin in patients with SS in the setting of refractory disease or low CD30 skin expression has only been demonstrated in a small case series of 13 patients.[168]

Mogamulizumab

In the MAVORIC trial, mogamulizumab, a humanized anti-CCR4 monoclonal antibody, was more effective than vorinostat in patients with previously treated MF (≥ stage IB) and SS. Mogamulizumab resulted in significantly higher ORR (28% vs. 5%) and median PFS (8 vs. 3 months) compared with vorinostat and the ORR was higher in patients with SS than those with MF (37% vs. 21%).[105] Patients with LCT at study entry were excluded from this trial. In a post hoc analysis, the number of prior therapies did not impact the ORR, PFS, and duration of response observed with mogamulizumab.[169] Among the 186 patients randomly assigned to vorinostat, 136 patients (109 patients with disease

Version 2.2026 © 2026 National Comprehensive Cancer Network© (NCCN©), All rights reserved. NCCN Guidelines® and this illustration may not be reproduced in any form without the express written permission of NCCN.

PLEASE NOTE that use of this NCCN Content is governed by the End-User License Agreement, and you MAY NOT distribute this Content or use it with any artificial intelligence model or tool.
Printed by Galya Basol Kochav on 2/16/2026 9:44:21 AM. Copyright © 2026 National Comprehensive Cancer Network, Inc. All Rights Reserved.

progression and 27 patients after intolerable toxicity) crossed over to mogamulizumab. The ORR was 31% for the 133 patients who crossed over from vorinostat to mogamulizumab and subsequently received mogamulizumab. The most common adverse events associated with mogamulizumab were mostly grade 1–2 and manageable (infusion-related reactions [37%], skin eruptions [25%], and diarrhea [14%]). Pyrexia (4%) and cellulitis (3%) were the most common grade 3 adverse events in the mogamulizumab group. Patients with the greatest symptom burden and functional impairment derived the most benefit from mogamulizumab in terms of quality of life.[170]

The clinical benefit with mogamulizumab was higher in patients with stage III or stage IV disease, especially in patients with B1 and B2 blood involvement.[105,171,172] In the post-hoc subgroup analysis by clinical stage, the ORRs for mogamulizumab were 23% and 36%, respectively, for patients with stage III or stage IV disease compared to 19% and 16%, respectively, for patients with stage IB/IIA disease or stage IIB disease.[105] Mogamulizumab also resulted in higher ORR than vorinostat across all disease compartments. The compartment-specific ORRs for mogamulizumab were 42%, 68%, and 17%, respectively, for skin, blood involvement, and lymph nodes. The corresponding ORRs for vorinostat were 16%, 19%, and 4%, respectively. The overall disease control rate was 79% (76% for MF and 82% for SS) and improved with long-term exposure to mogamulizumab.[173] This trial, however, was not powered to detect OS differences between the two groups within the defined follow-up period.

The post-hoc analyses that evaluated the efficacy of mogamulizumab based on blood tumor burden showed that blood involvement was associated with improved ORRs, PFS, and time to next treatment (TTNT) for patients treated with mogamulizumab.[171,172] The ORRs were 26% and 37%, respectively, for patients with B1 and B2 blood involvement compared to 16% for those with B0 blood involvement.[171] The median PFS was 11 months and 8 months, respectively, for patients with B2 and B1 blood involvement compared to 5 months for those with B0 blood involvement.[172] The TTNT was 20 months for those with B2 blood involvement compared to 12 months and 7 months, respectively, for those with B1 and B0 blood involvement.[172] Mogamulizumab also was associated with sustained reductions seen in CD4+ CD26- cell counts and CD4:CD8 ratios in patients for all B classes of blood involvement.

A drug-induced skin eruption that has variable clinical and pathologic features (and can mimic CTCL) was the most frequent adverse event leading to treatment discontinuation in the MAVORIC trial.[105,174-177] Mogamulizumab-associated skin rash has also been identified as a potential marker for tumor response.[178] Skin biopsy (with adequate immunohistochemical stains and clonality assessment) is recommended to rule out disease progression in patients experiencing drug-induced skin eruptions or mogamulizumab-associated skin rash.[176,179,180]

Histone Deacetylase Inhibitors

Vorinostat was the first HDAC inhibitor to be approved for the treatment of MF and SS. In the initial phase IIB registration study, vorinostat resulted in an ORR of 30%.[110] A *post-hoc* subset analysis of patients who experienced clinical benefit with ≥2 years of vorinostat therapy in the phase IIB study provided some evidence for the long-term safety and efficacy of vorinostat in patients with heavily pretreated MF and SS.[111] While cumulative toxicities were rare with vorinostat, patients need to be monitored for gastrointestinal toxicity, including nausea, diarrhea, and resultant dehydration, which could be more detrimental for older patients.

Romidepsin has demonstrated clinical activity across all disease compartments.[112-114] The median duration of response is 13 to 15 months for patients with disease responding to romidepsin.[112,113] Importantly, romidepsin was associated with a high rate of reduction in pruritus score

Version 2.2026 © 2026 National Comprehensive Cancer Network© (NCCN©), All rights reserved. NCCN Guidelines® and this illustration may not be reproduced in any form without the express written permission of NCCN.

PLEASE NOTE that use of this NCCN Content is governed by the End-User License Agreement, and you MAY NOT distribute this Content or use it with any artificial intelligence model or tool.
Printed by Galya Basol Kochav on 2/16/2026 9:44:21 AM. Copyright © 2026 National Comprehensive Cancer Network, Inc. All Rights Reserved.

irrespective of clinical objective response. The compartment-specific ORRs were 40%, 35%, 32%, and 27%, respectively, for skin involvement, erythroderma, blood involvement, and lymphadenopathy.[114] It is important to initially monitor for QTc prolongation when administering romidepsin, particularly with the concomitant use of antiemetics that also prolong QTc. Romidepsin is included as a preferred regimen for patients with SS with high Sézary cell burden.

Denileukin Diftitox

Denileukin diftitox (a recombinant human interleukin-2 diphtheria toxin fusion protein), initially approved for relapsed/refractory CTCL,[181,182] was withdrawn from the market in 2014 due to manufacturing difficulties. A reformulated version of denileukin diftitox was evaluated in Study 302 for patients with relapsed or refractory MF and SS.[106] LCT-MF was not an exclusion criteria but no patients with LCT-MF were enrolled in the study. CD25-positivity was defined as detectable CD25 in ≥20% of total lymphoid cells in biopsy specimen by IHC.

The primary efficacy analysis included 69 patients with MF (stage IA–IIIB). The majority of the patients had stage IB–IIA (n = 25) or stage IIB (n = 24) disease. Denileukin diftitox resulted in an ORR of 36% (as assessed by an independent review committee) and the median duration of response was 9 months.[106] The ORR were higher for stage IIB disease (46%) compared to those with stage IA–IIA disease (37%) or stage III disease (20%). There was no correlation between the CD25 expression and the efficacy of denileukin diftitox. Reduction in skin disease burden was observed across all stages (84%; 54 out of the 64 evaluable patients). Treatment-related adverse events of special interest including capillary leak syndrome (CLS; typically occurring during the first 2 cycles; 20%; grade ≥3, 6%), infusion-related reactions (74%), hypersensitivity (68%), and hepatotoxicity (36%) were mostly grade 1–2, with no evidence of cumulative toxicity.

Denileukin diftitox is included as a preferred systemic therapy option for stage IIB (generalized tumor disease) and as an option under useful in certain circumstances for stage IB–IIA, stage IIB (limited) and stage III disease.

Alemtuzumab

Alemtuzumab (a humanized anti-CD52 monoclonal antibody) has significant clinical activity in patients with previously treated advanced MF and SS.[118-123] The ORR with alemtuzumab (30 mg IV) was higher in patients with erythroderma or SS than those with advanced MF; however, it was associated with myelotoxicities and infectious complications.[119,123] Reduced-dose subcutaneous alemtuzumab (3–15 mg per administration) given for a shorter duration was equally effective with lower incidence of infectious complications in patients with SS.[120] While alemtuzumab is no longer commercially available, it may be obtained for compassionate use for patients with CTCL and other hematologic malignancies.

Pembrolizumab

In a phase II trial, pembrolizumab (an immune checkpoint inhibitor) resulted in durable responses in both MF and SS with an ORR of 38% and median duration of response not reached at a median follow-up of 58 weeks.[124] Pembrolizumab was associated with a skin flare reaction, occurring exclusively in patients with SS; the flare reaction correlated with high PD-1 expression on Sezary cells, and it should be distinguished from disease progression.

Pralatrexate

Pralatrexate is a folate analog with demonstrated activity in patients with heavily pretreated MF and SS.[115-117] In a multicenter dose-finding study that evaluated pralatrexate (10–30 mg/m^2 given weekly for 2 of 3 weeks or 3 of 4 weeks) in 54 patients with relapsed or refractory MF and SS, the ORR for all evaluable patients was 41% (6% CR).[115] Among the 29 patients who received the recommended dose (15 mg/m^2 weekly for 3

Version 2.2026 © 2026 National Comprehensive Cancer Network© (NCCN©), All rights reserved. NCCN Guidelines® and this illustration may not be reproduced in any form without the express written permission of NCCN.

PLEASE NOTE that use of this NCCN Content is governed by the End-User License Agreement, and you MAY NOT distribute this Content or use it with any artificial intelligence model or tool.
Printed by Galya Basol Kochav on 2/16/2026 9:44:21 AM. Copyright © 2026 National Comprehensive Cancer Network, Inc. All Rights Reserved.

weeks of a 4-week cycle), the ORR was 45% (3% CR).[115] In the subgroup of patients with relapsed/refractory LCT of MF treated on the PROPEL trial, pralatrexate (30 mg/m^2) resulted in an ORR of 58% (25% by independent review).[116] The median PFS and OS were 5 months and 13 months, respectively.

Gemcitabine

Gemcitabine monotherapy is an effective treatment option for patients with heavily pretreated advanced-stage MF and SS.[139-146] In a retrospective observational study of 25 patients with advanced MF and SS, after a long-term follow-up of 15 years, the estimated OS, PFS, and DFS rates were 47%, 9%, and 40%, respectively.[143] In a single-center study of 14 patients with heavily pretreated MF (n = 12) and SS (n = 2), gemcitabine resulted in an ORR of 57% (all were in the skin compartment) and the median TTNT was 12 months.[146] Retrospective studies have also reported favorable clinical outcomes (ORR and PFS) with low-dose gemcitabine in patients with previously treated MF and SS.[144,145]

Liposomal Doxorubicin

Pegylated liposomal doxorubicin has shown single-agent activity in patients with pretreated, advanced, or refractory MF and SS.[146-151]

In a phase II EORTC multicenter trial of 49 patients with relapsed/refractory advanced MF (stage IIB, IVA, or IVB) after at least two prior systemic therapies, pegylated liposomal doxorubicin resulted in an ORR of 41% (6% CR), with a median duration of response and median time to progression (TTP) of 6 months and 7 months, respectively.[149] Pegylated liposomal doxorubicin was well tolerated with no grade 3 or 4 hematologic toxicities; the most common grade 3 or 4 toxicities included dermatologic toxicity other than hand and foot reaction (6%), constitutional symptoms (4%), gastrointestinal toxicities (4%), and infection (4%).

In a single-center study of 32 patients (MF, n = 25; SS, n = 7) treated with pegylated liposomal doxorubicin for heavily pretreated MF (n = 25) and SS (n = 7), the ORR was 58% for the entire study population (71% in skin, 44% in blood, and 33% in lymph nodes).[146] The toxicity profile was also consistent with that reported in the phase II study, with fatigue, peripheral edema, anemia, hyperpigmentation, and hand-foot syndrome being the most common toxicities of all grades. Another real-life cohort study (36 patients; MF, n = 34; SS, n = 2) also confirmed the activity of pegylated liposomal doxorubicin for advanced MF and SS, especially in patients with tumor stage disease.[151]

Extracorporeal Photopheresis

ECP has been demonstrated as an effective treatment option in many retrospective studies, resulting in an ORR of 42% to 74%.[137,183-190]

In a meta-analysis involving more than 400 patients with MF and SS, ECP as monotherapy resulted in a 56% ORR with a 15% CR.[184] The corresponding response rates were 58% (15% CR) for erythrodermic disease (T4) and 43% (10% CR) for SS. In one retrospective study of 39 patients with MF and SS (31 patients with T4 disease and 8 patients with T2 disease), ECP resulted in a skin ORR of 74% (33% of patients achieved ≥50% partial skin response and 41% of patients achieved ≥90% improvement).[187] After a median follow-up of 72 months, the median OS was 9 years from diagnosis and 7 years from the initiation of treatment with ECP. Another retrospective study of 50 patients with MF reported an ORR of 42% and an OS of 72 months with no statistically significant differences in OS among patients with early-stage and late-stage disease (77 months and 69 months, respectively; $P = .077$).[189] A real-word retrospective analysis (52 patients; 50% of patients had SS and 37% had MF) also showed that ECP is an effective treatment option for patients with MF and SS, resulting in a response rate of 37% (51% reduction in BSA) and the median time to response was 6.5 months. The median duration of treatment was 10 months.[191]

Version 2.2026 © 2026 National Comprehensive Cancer Network© (NCCN©), All rights reserved. NCCN Guidelines® and this illustration may not be reproduced in any form without the express written permission of NCCN.

PLEASE NOTE that use of this NCCN Content is governed by the End-User License Agreement, and you MAY NOT distribute this Content or use it with any artificial intelligence model or tool.
Printed by Galya Basol Kochav on 2/16/2026 9:44:21 AM. Copyright © 2026 National Comprehensive Cancer Network, Inc. All Rights Reserved.

The degree of blood involvement, CD4/CD8 ratio, and amount of circulating CD3+CD8+ cells or CD4(+)CD7(-) lymphocytes have been identified as predictors of clinical response.[136,137,192] ECP is generally given for at least 6 months and may be more appropriate as systemic therapy for patients with or at risk of blood involvement (B1 or B2; erythrodermic stage III disease or IVA with SS).[184,190]

Combination Therapies

Skin-Directed + Systemic Therapies

Phototherapy is most commonly used in combination with either IFN[193-196] or systemic retinoid.[155,161,197-199]

In a prospective randomized study that evaluated IFN combined with PUVA versus IFN combined with retinoids in patients with stage I or II CTCL (n = 82 evaluable), the combination of IFN with PUVA resulted in significantly higher CR rates in this patient population (70% vs. 38%).[193] In another prospective phase II trial in patients with early-stage MF (stages IA–IIA; n = 89), the combination of low-dose IFN alfa with PUVA resulted in an ORR of 98% (84% CR).[195]

In a phase III randomized study from the EORTC that evaluated the combination of bexarotene with PUVA compared with PUVA alone in patients with early-stage MF (stage IB and IIA; n = 93), the ORR for the combination of bexarotene with PUVA was 77% (31% CR) compared to 71% (22% CR) for PUVA alone; the median duration of response was 6 months and 10 months, respectively.[155] A trend towards fewer PUVA sessions and lower UVA doses to achieve CR was observed with the combination arm, although the differences were not significant.[155] This trial was closed prematurely due to low patient accrual.

A small prospective study evaluated the combination of low-dose bexarotene in combination with PUVA maintenance in 21 patients with MF and SS (stage IB–IV) resistant or intolerant to previous therapies.[197] The ORR was 86% after induction therapy with bexarotene (93% for early-stage disease and 66.6% for advanced disease). At the end of maintenance, the ORR was 76% (33% CR) and the median event-free survival (EFS) for the whole group was 31 months.

In a retrospective analysis of 128 patients with MF (118 patients had early-stage disease; stage ≤IIA), acitretin (either as monotherapy or in combination with phototherapy or topical steroids) resulted in an ORR of 77% (44% CR and 33% PR) with a trend towards better response rate in the combination arm compared to monotherapy.[161] The median duration of response was 24 months.

ECP used in combination with TSEBT or phototherapy (narrowband UVB or PUVA) has also resulted in high durable clinical response in patients with erythrodermic MF and SS.[200,201] In a retrospective study of 44 patients with erythrodermic MF, the combination of TSEBT with ECP (concurrent or sequential following TSEBT) significantly improved PFS compared with TSEBT alone.[200] The 2-year PFS and OS rates were 36% and 63%, respectively, for patients treated with TSEBT alone compared with 66% and 88% for those treated with TSEBT + ECP.

There are limited efficacy and safety data for the use of TSEBT in combination with systemic retinoids, brentuximab vedotin, HDAC inhibitors (vorinostat or romidepsin), or mogamulizumab.[202-206]

Systemic Combination Therapies

Systemic combination therapy regimens have been shown to improve response rates in patients with early-stage disease with inadequate response to single-agent therapy or those with advanced-stage CTCL.

ECP with IFN and/or systemic retinoid and IFN with systemic retinoid are the most commonly evaluated combination therapies for patients with CTCL.[156-158,207-209] The combination of oral isotretinoin and IFN alfa

Version 2.2026 © 2026 National Comprehensive Cancer Network© (NCCN©), All rights reserved. NCCN Guidelines® and this illustration may not be reproduced in any form without the express written permission of NCCN.

PLEASE NOTE that use of this NCCN Content is governed by the End-User License Agreement, and you MAY NOT distribute this Content or use it with any artificial intelligence model or tool.
Printed by Galya Basol Kochav on 2/16/2026 9:44:21 AM. Copyright © 2026 National Comprehensive Cancer Network, Inc. All Rights Reserved.

resulted in an ORR of 85% and the estimated 5-year OS rate was 94% for patients with early-stage MF and 35% for advanced-stage MF.[156] ECP in combination with IFN and/or systemic retinoids resulted in a response rate of 84% in patients with advanced CTCL and the 5-year OS rates for the subgroups of patients with stage IIIB, IVA1, IVA2, and IVB were 80%, 80%, 76%, and 0%, respectively.[208,209] Other systemic combination therapy regimens have also been studied.[210-212]

However, aforementioned studies that have evaluated the systemic combination regimens are limited by small sample size and there are no data from prospective randomized clinical studies to support the use of a specific systemic combination therapy regimen.

Additional Therapy Based on Response to Primary Treatment

Historically, the response criteria for MF and SS were poorly defined and validated response assessments were lacking. Response criteria for MF and SS have not been demonstrated to correlate with prognosis, and responses can vary between the different disease compartments (ie, skin, blood, lymph nodes).

More recent studies have incorporated consensus response assessments and newer FDA-approved agents have undergone central review for efficacy outcomes. A proposal for the standardization of definition of response in skin, nodes, blood, and viscera has been published.[213] The decisions to continue with or switch treatment regimens are often made based on clinical parameters. Imaging with the same modalities used in workup is indicated when there is suspicion of disease progression or extracutaneous disease.

All patients (stage IA–IV) with a clinical benefit and/or those with disease responding to primary treatment should be considered for maintenance or tapering of regimens to optimize response duration. Disease relapse (with the same stage) after discontinuation of therapy often responds well to retreatment with previous therapy. Patients with persistent disease following completion of primary treatment should be treated with the other primary treatment options not received before to improve response before moving onto treatment for refractory disease.

Currently there is no definitive treatment for refractory disease that can produce reliable durable remissions or curative results. Participation in a clinical trial is recommended for all patients with refractory disease. Multiagent chemotherapy regimens recommended for PTCL can be considered for the treatment of refractory disease to multiple prior therapies.

Special Considerations for Clinical Situations with Specific Pathologic Features

Folliculotropic Mycosis Fungoides

FMF is characterized by the infiltration of hair follicles by atypical T lymphocytes and resultant alopecia. Disease typically presents as plaques and tumors mainly on the head/neck and the risk profile varies with stage of the disease.[21,214-217] Recent studies have reported that FMF presents with two distinct patterns of clinicopathologic features with different prognostic implications (early stage and advanced stage). In a subgroup of patients with early skin-limited disease, FMF has an indolent disease course and a favorable prognosis, with early-stage cutaneous disease associated with significantly higher disease-specific survival compared to advanced-stage cutaneous disease.[218-220]

In a report from the Dutch Cutaneous Lymphoma Group that evaluated the treatment outcomes in patients with FMF (203 patients; 84 patients with early-stage FMF, 102 patients with advanced-stage FMF, and 17 patients with extracutaneous FMF), treatment with topical steroids and phototherapy with UVB or PUVA were more effective in patients with early-stage FMF resulting in an ORR of 83% (28% CR), 83%, and 88%, respectively.[221] Local RT, TSEBT, and PUVA combined with RT were

Version 2.2026 © 2026 National Comprehensive Cancer Network© (NCCN©), All rights reserved. NCCN Guidelines® and this illustration may not be reproduced in any form without the express written permission of NCCN.

PLEASE NOTE that use of this NCCN Content is governed by the End-User License Agreement, and you MAY NOT distribute this Content or use it with any artificial intelligence model or tool.
Printed by Galya Basol Kochav on 2/16/2026 9:44:21 AM. Copyright © 2026 National Comprehensive Cancer Network, Inc. All Rights Reserved.

more effective in patients with advanced-stage FMF resulting in an ORR of 100% (63% CR), 100% (59% CR), and 75% (5% CR), respectively.

Patients with early-stage FMF may benefit from standard skin-directed therapies used for the treatment of early-stage MF, and those with generalized indolent/plaque FMF (without evidence of LCT) should initially be considered for single-agent systemic therapy regimens before receiving multiagent chemotherapy regimens.

Large-Cell Transformation

LCT is diagnosed when large cells are present in >25% of lymphoid/tumor cell infiltrates in a skin lesion biopsy, and the incidence of LCT is strongly dependent on the disease stage at diagnosis (1% for early-stage disease, compared with 27% for stage IIB disease and 56%–67% for stage IV disease).[8-10] LCT is often, but not always, aggressive. CD30 expression is associated with LCT in MF or SS in 30% to 50% of cases, and this finding may have potential implications for CD30-directed therapies.[8-10,222] However, it should be noted that CD30 expression is variable in MF and SS, with the leukemic Sézary cells typically being CD30-negative.

Systemic therapy (brentuximab vedotin, gemcitabine, liposomal doxorubicin, pralatrexate, romidepsin, or pembrolizumab) with skin-directed therapies is the initial treatment for generalized cutaneous or extracutaneous lesions with LCT. In addition, concurrent management of coexisting disease based on clinical stage is recommended. Selected patients with localized LCT (ie, restricted to one or few T3 lesions or stage IA–IIA plaque disease) could be treated with EBRT alone, with continuation of other treatment modalities used prior to transformation. Depending on the goals of treatment, multiagent chemotherapy regimens recommended for PTCL may be appropriate for the management of LCT, which is refractory to multiple prior therapies or when significant extracutaneous disease is present.

Role of Allogeneic Hematopoietic Cell Transplant in MFSS

Allogeneic HCT has a role in a subset of patients with advanced-stage MF and SS who have received multiple lines of therapy as shown in retrospective studies and small prospective series of patients with advanced MF and SS.[223-230]

In a multicenter retrospective analysis of 37 patients with advanced-stage primary CTCL treated with allogeneic HCT (24 patients [65%] had stage IV MFSS or disseminated nodal or visceral involvement), after a median follow-up of 29 months, the incidence of relapse was 56% and the estimated 2-year OS and PFS rates were 57% and 31%, respectively.[223]

In a retrospective analysis of patients with advanced-stage MF and SS in the European Group for Blood and Marrow Transplantation (EBMT) database (n = 60) treated with allogeneic HCT, the 5-year PFS and OS rates were 32% and 46%, respectively. The corresponding 7-year survival rates were 44% and 30%, respectively.[224] The non-relapse mortality (NRM) rate at 7 years was 22%. Outcomes were not significantly different between histology types. However, patients with advanced-stage disease had an increased risk of relapse or progression as well as lower PFS, and myeloablative conditioning was associated with poorer NRM and OS. In an updated analysis, advanced-stage disease (refractory disease or PD after ≥3 lines of systemic therapy prior to transplant), a short interval between diagnosis, and transplant (<18 months) were independent adverse prognostic factors for PFS; advanced-stage disease and the use of unrelated donors were independent adverse prognostic factors for OS.[228]

In a case series of 47 patients with advanced-stage MF and SS who underwent allogeneic HCT after disease progression on conventional therapy, the estimated 4-year OS and PFS rates were 51% and 26%, respectively.[226] While there was no statistical difference in the OS in

Version 2.2026 © 2026 National Comprehensive Cancer Network© (NCCN©), All rights reserved. NCCN Guidelines® and this illustration may not be reproduced in any form without the express written permission of NCCN.

PLEASE NOTE that use of this NCCN Content is governed by the End-User License Agreement, and you MAY NOT distribute this Content or use it with any artificial intelligence model or tool.
Printed by Galya Basol Kochav on 2/16/2026 9:44:21 AM. Copyright © 2026 National Comprehensive Cancer Network, Inc. All Rights Reserved.

patients who had MF without LCT, SS, MF with LCT, or SS with LCT, the 4-year PFS rate was superior in patients who had SS versus those who did not (52% vs.10%; *P* = .02). Another multicenter retrospective study, although limited by small sample size (26 patients; MF, n = 17; SS, n = 9), reported superior outcomes with allogeneic HCT in patients with SS compared to MF.[230] After a median follow-up of 5 years, patients with SS had lower relapse rates (11% at 5 years), longer TTNT (not reached), higher treatment-free survival (89% at 5 years) and OS (5-year OS rate was 100%) compared to those with MF (74%, 24 months, 16% and 52%, respectively). Other systematic review and meta-analysis have reported pooled PFS and OS rates of 36% and 59%, respectively, following allogeneic HCT in patients with advanced-stage MF and SS.[231,232]

The survival benefit of allogeneic HCT in patients with advanced MF and SS was confirmed in a prospective, multicenter, propensity score-matched, controlled trial (99 patients with advanced MF and SS; 55 patients assigned to the allogeneic HCT group and 44 patients assigned to the non-allogeneic HCT treatment option of investigator's choice).[233] After a median follow-up of 13 months, the median PFS was significantly longer in the allogeneic HCT group (9 vs. 3 months in the non-allogeneic HCT group; *P* < .0001). The 1-year PFS rates were 51% and 14%, respectively, for patients in the allogeneic HCT group and non-allogeneic HCT group. The 1-year cumulative incidence of relapse was also lower in the allogeneic HCT group (45% compared to 86% in the non-allogeneic HCT group).

The use of TSEBT with non-myeloablative allogeneic HCT has also been evaluated in patients with advanced MF and SS.[234-236] In a study of 19 patients with advanced CTCL, the use of TSEBT prior to allogeneic HCT provided improved disease control with an ORR of 68% (58% CR) with median OS not reached at the time of the report; the treatment-related mortality (TRM) rate was 21%.[234] The safety and efficacy of a non-myeloablative conditioning regimen consisting of TSEBT and total lymphoid irradiation (TLI) + anti-thymocyte globulin (ATG) has also been demonstrated in prospective clinical studies.[237,238] In a prospective clinical study of 35 patients with advanced-stage disease (13 patients with MF and 22 patients with SS), this regimen was associated with 1-year and 2-year NRM of 3% and 14%, respectively.[237] The 2-year incidence of moderate/severe chronic graft-versus-host disease (GVHD) was 32%. With a median post-transplant follow-up of 5 years, the 2-year, 3-year, and 5-year OS rates were 68%, 62%, and 56%, respectively. The 5-year PFS rate was 41%. Patients >65 years of age at the time of transplant had similar clinical outcomes compared with younger patients. This study also evaluated the utilization of high-throughput sequencing (HTS) to monitor minimal residual disease (MRD), and molecular remission after allogeneic HCT (achieved in 43% of patients) was associated with a lower incidence of PD or relapse. In another prospective study that evaluated the same non-myeloablative conditioning regimen (TSEBT + TLI + ATG) in 41 patients with advanced-stage disease (34 patients with MF and 7 patients with SS), the 1-year and 2-year NRM rates were 10% and 13%, respectively.[238] Grade ≥2 acute and chronic GVHD were reported in 32% and 24% of patients, respectively. After a median follow-up of 5 years after transplant, the 5-year OS rate was 38% for the entire study population (37% for MF and 57% for SS). The 5-year cumulative incidence of disease progression or relapse was 53% for all patients and these rates were significantly lower for patients achieving CR following transplant (21% compared to 71% in those not in CR; *P* = .006).

Allogeneic HCT may be considered for appropriate patients with stage IIB–IV disease that is refractory to multiple primary treatment options.[239] Based on the limited evidence, patients with erythrodermic MF and SS appear to receive the most benefit from allogeneic HCT, despite high post-transplant relapse rate. Allogeneic HCT is generally reserved for patients with systemic disease and/or extensive skin involvement that is

Version 2.2026 © 2026 National Comprehensive Cancer Network© (NCCN©), All rights reserved. NCCN Guidelines® and this illustration may not be reproduced in any form without the express written permission of NCCN.

PLEASE NOTE that use of this NCCN Content is governed by the End-User License Agreement, and you MAY NOT distribute this Content or use it with any artificial intelligence model or tool.
Printed by Galya Basol Kochav on 2/16/2026 9:44:21 AM. Copyright © 2026 National Comprehensive Cancer Network, Inc. All Rights Reserved.

refractory to or progressive after multiple lines of systemic therapy options. When appropriate, TSEBT may be considered as cytoreductive therapy before transplant.[234,237] Novel conditioning regimens are being explored to provide improved disease control while limiting transplant-related complications.

A transplant decision requires careful counseling to weigh the significant risks of this procedure versus the likelihood of long-term benefits and availability of alternate treatments. The ideal timing for allogeneic HCT is when the disease is well controlled with induction therapy and before the disease has progressed to a state where the chance of response or survival with allogeneic HCT is low.[240]

Autologous HCT is not recommended for patients with CTCL, due to short duration of response despite its toxicity, thus limiting its utility.[239,241] While the majority of the deaths among patients undergoing autologous HCT may be attributable to PD, deaths associated with allogeneic HCT may be more due to NRM (the incidence of 1-year NRM in published reports with allogeneic HCT is approximately 11%–25%).[223-227]

Supportive Care

Management of Pruritus

Symptoms of pruritus can be present in a large majority (nearly 90%) of patients with CTCL, and may be associated with decreased quality of life for patients.[242-244] Patients should be evaluated for pruritus at each visit. Other potential causes of pruritus (eg, contact dermatitis, atopic dermatitis, psoriasis, other inflammatory skin conditions) should be ruled out. The extent of pruritus (localized vs. generalized) and potential correlation between disease site and localization of pruritus should be noted.

The treatment of pruritus requires optimizing skin-directed and systemic treatments. Daily use of moisturizers and emollients are helpful in maintaining and protecting the skin barrier. Topical steroids (with or without occlusion) can be effective in managing the disease and accompanying pruritus in early-stage disease.[244,245] First-line options include H1 antihistamines (single-agent or combination of antihistamines from different classes) or the anticonvulsant gabapentin.[242,246,247] Neurokinin-1 (NK-1) receptor antagonist aprepitant,[248-250] the tetracyclic antidepressant mirtazapine, or selective serotonin reuptake inhibitors (SSRIs) may be considered in the second-line setting.[251,252] Treatment with the oral opioid receptor antagonist naltrexone may be considered if symptoms of pruritus do not resolve with the above agents.[253]

Prevention and Treatment of Infections

Infectious complications are frequent among patients with MF and SS, particularly cutaneous bacterial infections and cutaneous herpes viral infections (eg, herpes simplex virus [HSV] or herpes zoster virus [HZV] infections).[254] Bacteremia/sepsis and bacterial pneumonia were reported as the major cause of death due to infections in a retrospective cohort study of patients with MF and SS.[254] Several preventive measures such as maintaining/protecting the skin barrier (routine use of skin moisturizers and/or emollients), bleach baths or soaks (for limited areas only), avoidance of central lines (particularly for erythrodermic patients), and prophylactic use of mupirocin in cases of *Staphylococcus aureus* colonization can be incorporated to minimize infectious complications. HSV prophylaxis with acyclovir or equivalent should be considered for patients with frequent recurrence of HSV infection. Patients undergoing treatment with alemtuzumab-containing regimens should be closely monitored for cytomegalovirus (CMV) reactivation and preemptively treated with antivirals to avoid overt CMV disease.

Cultures from skin swab and nares (nostrils) should be taken to evaluate for *S. aureus* colonization/infection in patients with erythroderma and an active or suspected infection. Antimicrobial treatments may include intranasal mupirocin and/or oral dicloxacillin or cephalexin. Bleach baths or soaks may be helpful if the affected area is limited. Doxycycline or

Version 2.2026 © 2026 National Comprehensive Cancer Network© (NCCN©), All rights reserved. NCCN Guidelines® and this illustration may not be reproduced in any form without the express written permission of NCCN.

PLEASE NOTE that use of this NCCN Content is governed by the End-User License Agreement, and you MAY NOT distribute this Content or use it with any artificial intelligence model or tool.
Printed by Galya Basol Kochav on 2/16/2026 9:44:21 AM. Copyright © 2026 National Comprehensive Cancer Network, Inc. All Rights Reserved.

trimethoprim/sulfamethoxazole (TMP/SMX) should be considered for patients with suspected methicillin-resistant *S. aureus* (MRSA) infection. If no improvements in infection status are observed with the above agents, or if bacteremia is suspected, vancomycin should be initiated, or appropriate alternative antibiotic options can be considered.[255]

Infection with Gram-negative rods is common in necrotic tumors, and may lead to serious complications such as bacteremia/sepsis. For active or suspected infections in patients with ulcerated and necrotic tumors, blood cultures should be obtained and empiric therapy with antibacterials should be considered even in the absence of a fever. An antimicrobial agent with broad-spectrum coverage (including coverage for both Gram-negative rods and Gram-positive cocci) should be chosen initially. The role of skin/wound culture is not clear in this setting.

Further information on empiric therapy in patients with cancer at risk for infections is included in the NCCN Guidelines for the Prevention and Treatment of Cancer-Related Infections, available at www.NCCN.org.

Version 2.2026 © 2026 National Comprehensive Cancer Network© (NCCN©), All rights reserved. NCCN Guidelines® and this illustration may not be reproduced in any form without the express written permission of NCCN.

PLEASE NOTE that use of this NCCN Content is governed by the End-User License Agreement, and you MAY NOT distribute this Content or use it with any artificial intelligence model or tool.
Printed by Galya Basol Kochav on 2/16/2026 9:44:21 AM. Copyright © 2026 National Comprehensive Cancer Network, Inc. All Rights Reserved.

Table 1. Systemic Therapy for MF and SS

Trial	Regimen/Dose		Disease Stage and No. of Patients (n)	Patient Characteristics	Median Follow-up	ORR	Median PFS
ALCANZA trial (Phase III RCT)[104]	**Brentuximab vedotin** (1.8 mg/kg every 3 weeks; 16 3-week cycles)		Stage IA–IVB MF (n = 48)	ECOG PS 0–2; ≥18 years with relapsed or refractory CD30-expressing MF[a] (≥1 prior systemic therapy or RT); Patients with MF and B1 blood involvement were considered eligible; Patients with SS (B2 blood involvement) and those with disease progression on prior methotrexate and bexarotene were excluded.	46 months	55% (17% CR)	17 months
	Oral methotrexate (5–50 mg once per week) for 48 weeks		Stage IA–IVB MF (n = 49)			13% (2% CR)	4 months
	Oral bexarotene (300 mg/m² once per day) for 48 weeks						
MAVORIC trial (Phase III RCT)[105]	**Mogamulizumab** (1 mg/kg IV on a weekly basis for the first 28-day cycle, then on days 1 and 15 of subsequent cycles)		Stage IB–IVA (n = 186)	ECOG PS 0–1; ≥18 years with relapsed or refractory MF and SS (≥1 prior systemic therapy); Patients with LCT at study entry were excluded. CCR4 expression was not a requirement for participation in the trial.	17 months	28% (23% by IRC)	8 months (7 months by IR)
	Vorinostat (400 mg daily)		Stage IB–IVA (n = 186)			5% (4% by IRC)	3 months (4 months by IR)
Study 302 [106]	**Denileukin diftitox (reformulated)** (9 mcg/kg/day IV over 60 min for 5 days every 21 days up to 8 cycles)		Stage IA–IIIB MF (n = 69)[b]	ECOG PS 0–2; Adequate organ function; ≥18 years with recurrent or persistent CD25-positive MF and SS[c] (≥1 prior systemic therapy; no prior denileukin diftitox).	—	42% (36% by IRC);	—
Phase II and III[107]	**Bexarotene**	300 mg/m²/day	Stage IA–IIA (n = 28)	≥18 years with refractory or persistent MF (after ≥2 prior therapies: phototherapy or TSEBT or topical mechlorethamine)	—	54%	—
		>300 mg/m²/day	Stage IA–IIA (n = 15)		—	67%	—
Phase II and III[108]	**Bexarotene**	300 mg/m²/day	Stage IIB–IVB (n = 56)	≥18 years with refractory or persistent MF and SS	—	45%	—
		>300 mg/m²/day	Stage IIB–IVB (n = 38)		—	55% (13% CR)	—

a. CD30 expression in ≥10% of total lymphoid cells in at least one skin biopsy. b. Patients with stage IV disease were enrolled in the study but not included in the primary efficacy analysis. c. CD25-positiity was defined as detectable CD25 in ≥20% of total lymphoid cells in biopsy specimen by IHC.

CR, complete response; IRC, independent review committee; LCT, large-cell transformation; MF, mycosis fungoides; ORR, overall response rate; PFS, progression-free survival; PS, performance status; RCT, randomized control trial; RT, radiation therapy; SS, Sézary syndrome; TSEBT, total skin electronic beam therapy. Continued on next page

Version 2.2026 © 2026 National Comprehensive Cancer Network© (NCCN©), All rights reserved. NCCN Guidelines® and this illustration may not be reproduced in any form without the express written permission of NCCN.

PLEASE NOTE that use of this NCCN Content is governed by the End-User License Agreement, and you MAY NOT distribute this Content or use it with any artificial intelligence model or tool.
Printed by Galya Basol Kochav on 2/16/2026 9:44:21 AM. Copyright © 2026 National Comprehensive Cancer Network, Inc. All Rights Reserved.

Table 1. Systemic Therapy for MF and SS

Trial	Regimen/Dose	Disease Stage and No. of Patients (n)	Patient Characteristics	Median Follow-up	ORR	Median PFS
Phase IIB[110]	**Vorinostat** (400 mg daily)	Stage IB–IVA (n = 74)	ECOG PS 0–2; ≥18 years with progressive, persistent, or recurrent MF and SS (after ≥2 prior systemic therapies including bexarotene)	—	30%	
Phase II[113]	**Romidepsin** (14 mg/m^2 as a 4-hour IV infusion on days 1, 8, and 15 of each 28-day cycle for up to 6 cycles)	Stage IB–IVA (n = 96)	ECOG PS 0–1; ≥18 years with relapsed or refractory MF and SS (≥1 prior systemic therapy)	—	34% (6% CR)	
PDX-010 (Dose-escalation study)[115]	**Pralatrexate** (15 mg/m^2, weekly for 3 out of 4 weeks)	Stage IB–IVA (n = 29)	ECOG PS 0–2; ≥18 years with progressive MF and SS (after ≥1 prior systemic therapy)	—	45%	Not reached
Phase II[119]	**Alemtuzumab** (IV 30 mg)	Stage II or IV (n = 22)	WHO PS ≤2; ≥18 years with CD52-positive relapsed or refractory MF and SS (≤5 prior systemic therapy)	—	55% (32% CR)	
Subcutaneous alemtuzumab[120]	**Alemtuzumab** (SC 10 mg maximum per administration)	SS (n = 14)	Median age 72 years; Previously untreated (n = 3) or relapsed/refractory (n = 11) SS with high counts of circulating Sézary cells	—	86% (21% CR)	Median survival (35 months)
Phase II (CITN-10)[124]	**Pembrolizumab** (2 mg/kg IV, every 3 weeks)	Stage IIB–IVB (n = 24)	ECOG PS 0–1; ≥18 years with relapsed or refractory MF and SS (≥1 prior systemic therapy)	—	38%	65% (1-year PFS rate)

CR, complete response; MF, mycosis fungoides; ORR, overall response rate; PFS, progression-free survival; PS, performance status; SS, Sézary syndrome.

Version 2.2026 © 2026 National Comprehensive Cancer Network© (NCCN©), All rights reserved. NCCN Guidelines® and this illustration may not be reproduced in any form without the express written permission of NCCN.

PLEASE NOTE that use of this NCCN Content is governed by the End-User License Agreement, and you MAY NOT distribute this Content or use it with any artificial intelligence model or tool.
Printed by Galya Basol Kochav on 2/16/2026 9:44:21 AM. Copyright © 2026 National Comprehensive Cancer Network, Inc. All Rights Reserved.

This discussion corresponds to the NCCN Guidelines for Cutaneous Lymphomas. Last updated: February 13, 2026.

Primary Cutaneous CD30+ T-Cell Lymphoproliferative Disorders

Primary cutaneous CD30+ T-cell lymphoproliferative disorders (PCTLD) represent a spectrum that includes primary cutaneous anaplastic large-cell lymphoma (PC-ALCL), lymphomatoid papulosis (LyP), and “borderline” cases with overlapping clinical and histopathologic features.[256,257] In a SEER database analysis of 14,942 cases of CTCL diagnosed in the United States between 2000 and 2018, PC-ALCL was the second most common CTCL with MF being the most common CTCL.[5] Primary cutaneous disease, spontaneous regression, and absence of extracutaneous spread are associated with a better prognosis.[258,259]

PC-ALCL represents approximately 8% of all cutaneous T-cell lymphomas (CTCL) and is histologically characterized by diffuse, cohesive sheets of large CD30-positive (in >75%) cells with anaplastic, pleomorphic, or immunoblastic appearance.[2] Patches and plaques may also be present, and some degree of spontaneous remittance in lesions may also be seen. PC-ALCL typically follows an indolent course with an excellent prognosis, although cutaneous relapses are more common.[260-262] A SEER database analysis of 501 cases of PC-ALCL diagnosed in the United States between 2005 and 2016, reported favorable overall survival (OS) rates (5-year and 10-year OS rates were 81% and 62%, respectively) with age ≥60 years and the use of chemotherapy were predictive of lower OS rates.[263] Clinical features typically include solitary or localized nodules or tumors (often ulcerated); multifocal lesions occur in approximately 20% of cases. Extracutaneous disease occurs in approximately 10% of cases, usually involving regional lymph nodes.[261] The presence of multiple cutaneous lesions at presentation, extensive skin lesions on the leg, disease progression to extracutaneous disease, early cutaneous relapse, and nodal progression are associated with poorer outcomes.[264-266]

LyP is histologically heterogenous with large atypical anaplastic, immunoblastic, or Hodgkin-like cells in a marked inflammatory background.[257] Several histologic subtypes have been defined based on the evolution of skin lesions. Clinical features include chronic, recurrent, spontaneously regressing papulonodular (grouped or generalized) skin lesions. LyP is not considered a malignant disorder and has an excellent prognosis with an OS rate of 92% at 5 and 10 years.[262] However, LyP has also been reported to be associated with an increased risk of secondary lymphomas such as mycosis fungoides (MF), PC-ALCL, systemic ALCL, or Hodgkin lymphoma.[267-272] Older age, positive *TCR* gene rearrangement, or diagnosis of mixed-type LyP have been reported as prognostic indicators of disease progression to lymphoma.[268,270]

Literature Search Criteria

Prior to the update of this version of the NCCN Clinical Practice Guidelines in Oncology (NCCN Guidelines®) for Primary Cutaneous Lymphomas, an electronic search of the PubMed database was performed to obtain key literature on PCTLD published since the previous Guidelines update using the following search terms: primary cutaneous anaplastic large cell lymphoma and LyP. The PubMed database was chosen as it remains the most widely used resource for medical literature and indexes peer-reviewed biomedical literature.[13]

The search results were narrowed by selecting studies in humans published in English. The data from key PubMed articles deemed as relevant to these guidelines have been included in this version of the Discussion section. Recommendations for which high-level evidence is lacking are based on the Panel’s review of lower-level evidence and expert opinion.

Version 2.2026 © 2026 National Comprehensive Cancer Network© (NCCN©), All rights reserved. NCCN Guidelines® and this illustration may not be reproduced in any form without the express written permission of NCCN.

PLEASE NOTE that use of this NCCN Content is governed by the End-User License Agreement, and you MAY NOT distribute this Content or use it with any artificial intelligence model or tool.
Printed by Galya Basol Kochav on 2/16/2026 9:44:21 AM. Copyright © 2026 National Comprehensive Cancer Network, Inc. All Rights Reserved.

The complete details of the Development and Update of the NCCN Guidelines are available at www.NCCN.org.

Diagnosis

As described earlier, PCTLD is a spectrum of clinical presentation including LyP (mostly papular and always regressing), PC-ALCL (mostly nodular and persistent), and also "borderline" presentations where lesions regress but take longer or are larger and not papular as in LyP.[2] Clinical and pathologic correlation is essential for distinguishing within the spectrum of PCTLD as well as distinguishing PCTLD from other cutaneous CD30+ disorders (ie, systemic ALCL, adult T-cell leukemia/lymphoma [ATLL], peripheral T-cell lymphoma [PTCL], MF with large cell transformation [MF-LCT], and benign disorders such as lymphomatoid drug reactions, arthropod bites, viral infections). MF and PCTLD can coexist in the same patient. Lymphomatoid drug reactions have been linked with certain drugs (eg, amlodipine, carbamazepine, cefuroxime) and may be associated with CD30+ atypical large cells in histology. Classic Hodgkin lymphoma (CHL) is less often associated with MF and PCTLD than previously thought; however, coexpression of CD30 and CD15 in these T-cell lymphomas may lead to a mistaken diagnosis of CHL.[273] It is therefore important not to diagnose CD30+ T-cell lymphomas in lymph nodes as Hodgkin lymphoma.

Complete skin examination (for any sign of benign or malignant skin lesions), adequate biopsy (punch, incisional, or excisional) of suspicious skin lesions, and immunohistochemistry (IHC) of skin biopsy specimen are essential to confirm the diagnosis. Molecular analysis to detect clonal *TCR* gene rearrangements, excisional or incisional biopsy of suspicious lymph nodes, and assessment of human T-cell lymphotropic virus type 1 (HTLV-1) serology to identify CD30+ ATLL would be helpful in selected circumstances. However, *TCR* gene rearrangement may not be demonstrated in all cases of PCTLD and *TCR* rearrangements can also be seen in patients with non-malignant conditions. Demonstration of identical clones in skin, blood, and/or lymph nodes may be helpful in selected cases.[32] Identification of clonal *TCR* gene rearrangement has no definitive established prognostic value; however, it could be helpful to determine clinical staging or assess relapsed or residual disease.

PCTLD are characterized by the following immunophenotype: CD30+ (>75% cells), CD4+, variable loss of CD2/CD5/CD3, and CD8+ (<5%) cytotoxic granule-associated proteins positive. ALK-positive PC-ALCL is extremely uncommon and t(2;5) translocation is typically absent in CD30+ PCTLD.[274,275] ALK positivity and differential expression of t(2;5) can help to distinguish between CD30+ PCTLD and ALCL of nodal origin. GATA3 expression by IHC has been proposed to be useful to differentiate between MF-LCT and CD30+ PCTLD.[276] MF-LCT was associated with a strong/diffuse expression of GATA3 while the CD30+ PCTLD showed variable/moderate expression of GATA3. MUM1 expression is valuable to distinguish between LyP and PC-ALCL, since the majority of cases of LyP (87%) are positive for MUM1 staining compared to only 20% of cases with PC-ALCL.[277]

The IHC panel may include CD3, CD4, CD8, CD20, CD30, CD56, and ALK. Additional markers such as CD2, CD5, CD7, CD25, TIA1, granzyme B, perforin, TCR beta, and TCR delta, IRF4/MUM1, and EMA may be useful in selected circumstances. Abnormal T-cell phenotype and perforin expression are significantly more frequent in PC-ALCL than in transformed MF and may be useful for the differential diagnosis between PC-ALCL and CD30-expressing transformed MF.[278]

DUSP22-IRF4 (6p25.3) gene rearrangement has been described in patients with PC-ALCL and LyP but is not associated with prognostic significance.[279-281] In a large multicenter study that investigated the clinical utility of detecting *IRF4* translocations in skin biopsies of T-cell lymphoproliferative disorders, fluorescence in situ hybridization (FISH) for

Version 2.2026 © 2026 National Comprehensive Cancer Network© (NCCN©), All rights reserved. NCCN Guidelines® and this illustration may not be reproduced in any form without the express written permission of NCCN.

PLEASE NOTE that use of this NCCN Content is governed by the End-User License Agreement, and you MAY NOT distribute this Content or use it with any artificial intelligence model or tool.
Printed by Galya Basol Kochav on 2/16/2026 9:44:21 AM. Copyright © 2026 National Comprehensive Cancer Network, Inc. All Rights Reserved.

IRF4 had a specificity and positive predictive value of 99% and 90%, respectively, for cutaneous ALCL.[279] FISH to detect *ALK* and *DUSP22-IRF4* rearrangements would be useful in selected circumstances. HTLV-1 status, assessed either by HTLV-1 serology or other methods, may be useful in populations at risk to exclude the diagnosis of CD30-positive ATLL (which is usually HTLV-1 positive).

Workup

The initial workup involves a history and complete physical examination including entire skin, palpation of peripheral lymph node regions, and liver or spleen. Laboratory studies should include complete blood count (CBC) with differential, a comprehensive metabolic panel, and assessment of lactate dehydrogenase (LDH) levels. Many skin-directed and systemic therapies are contraindicated or are of unknown safety in pregnancy. Therefore, pregnancy testing is recommended for individuals of childbearing age.

Biopsy of enlarged lymph nodes or extracutaneous sites is recommended if biopsy of skin is non-diagnostic. Fine-needle aspiration (FNA) biopsy alone is not sufficient for the initial diagnosis. Excisional or incisional biopsy is preferred over core needle biopsy. In certain circumstances, when a lymph node is not easily accessible for excisional or incisional biopsy, a combination of core needle biopsy and FNA biopsy in conjunction with appropriate ancillary techniques may be sufficient for diagnosis. Bone marrow evaluation has limited value in the staging of patients with PC-ALCL and is not required for disease staging.[282] Bone marrow aspiration and biopsy may be considered for solitary PC-ALCL or PC-ALCL without extracutaneous involvement on imaging.

Contrast-enhanced CT scan of the chest, abdomen, and pelvis or integrated whole-body PET/CT is recommended for PC-ALCL. PET scan may be preferred for patients with extranodal disease, which is inadequately imaged by CT. In LyP, imaging studies and bone marrow evaluation are done only if there is suspicion of systemic involvement by an associated lymphoma.

Primary Cutaneous ALCL

Radiation Therapy

In a report from the Dutch Cutaneous Lymphoma Group that evaluated the long-term outcome of patients with PCTLD (118 patients with LyP, 79 patients with PC-ALCL, and 11 patients with PC-ALCL with regional node involvement), radiation therapy (RT) or surgical excision as initial therapy (given for 48% and 19% of patients, respectively) resulted in a complete response (CR) rate of 100% in patients with PC-ALCL.[261] After a median follow-up of 61 months, subsequent skin-only relapse and extracutaneous disease were reported in 41% and 10% of patients, respectively.

A multicenter retrospective analysis of patients with PC-ALCL (n = 56) eligible to receive RT (primary therapy or after surgical excision) reported a clinical complete response (cCR) rate of 95% and a local control rate of 98% after a median follow-up of 4 years.[283] Although the median RT dose was 35 Gy (range, 6–45 Gy), CRs were seen with doses as low as 6 Gy and the achievement of cCR was independent of the RT dose, suggesting that lower RT dose of <30 Gy may be appropriate for the management of localized lesions. The efficacy of low-dose RT (≤20 Gy) for the treatment of solitary or localized PC-ALCL was also confirmed in other recent reports.[284-286]

Involved-site RT (ISRT) alone or surgical excision (with or without ISRT) are recommended for patients with solitary or grouped lesions.[260-262,287-290] ISRT alone is an appropriate option in selected patients with cutaneous ALCL regional lymph node involvement ± primary skin lesions.

Version 2.2026 © 2026 National Comprehensive Cancer Network© (NCCN©), All rights reserved. NCCN Guidelines® and this illustration may not be reproduced in any form without the express written permission of NCCN.

PLEASE NOTE that use of this NCCN Content is governed by the End-User License Agreement, and you MAY NOT distribute this Content or use it with any artificial intelligence model or tool.
Printed by Galya Basol Kochav on 2/16/2026 9:44:21 AM. Copyright © 2026 National Comprehensive Cancer Network, Inc. All Rights Reserved.

Systemic Therapy

In the ALCANZA study that included 31 patients with previously treated PC-ALCL, overall response rate (ORR) lasting for ≥4 months was significantly higher for brentuximab vedotin compared to the physician's choice of treatment with methotrexate or bexarotene (75% vs. 20%), and the proportion of patients achieving CR was also higher with brentuximab vedotin than with physician's choice (31% vs. 7%).[103]

In a multicenter study that evaluated the efficacy of treatment options in patients with multifocal lesions included in the Dutch Registry for Cutaneous Lymphomas prior to the FDA approval of brentuximab vedotin (24 patients with initial presentation and 17 patients with relapsed disease), RT (n = 21), systemic chemotherapy (n = 9), and low-dose methotrexate (n = 7) were the most common treatment options resulting in ORRs of 100% (100% CR), 100% (78% CR), and 57% (43% CR), respectively.[291] The presence of >5 skin lesions was associated with a higher risk of extracutaneous relapse (56% vs. 20% for the presence of 2–5 skin lesions).

In the aforementioned report from the Dutch Cutaneous Lymphoma Group, which evaluated the long-term outcome of 219 patients with PCTLD, 9 of 11 patients (82%) with PC-ALCL and regional node involvement received CHOP (cyclophosphamide, doxorubicin, vincristine, and prednisone)-like multiagent chemotherapy as initial therapy (82%), resulting in a CR in eight patients (88%).[261] However, five out of these eight patients experienced skin relapses during follow-up. After a median follow-up of 58 months, disease-related 5-year survival rate was 91%.

In November 2018, the FDA approved brentuximab vedotin in combination with cyclophosphamide, doxorubicin, and prednisone (CHP) for the treatment of previously untreated systemic ALCL or other CD30-positive PTCL based on the results of the ECHELON-2 trial, which showed that brentuximab vedotin + CHP was superior to CHOP for patients with CD30-positive PTCL as shown by a significant improvement in progression-free survival (PFS) and OS.[292] This trial, however, excluded patients with PC-ALCL. However, since CHOP is included as an option for primary treatment (other recommended regimens) for cutaneous ALCL with regional nodes, the Panel acknowledged that brentuximab vedotin + CHP would also be an appropriate option for these patients.

Systemic therapy is indicated only for multifocal lesions (± skin-directed therapy) and for those with regional node involvement (± ISRT). Brentuximab vedotin is the preferred systemic treatment option based on the results of the ALCANZA study.[103] Low-dose methotrexate (50 mg weekly),[293,294] pralatrexate,[115] systemic retinoids (bexarotene for multifocal lesions),[295-298] and interferon (multifocal lesions)[295,299-301] are included as options for other recommended regimens based on the limited available data. IFN alfa is no longer commercially available. Peginterferon alfa 2a or ropeginterferon alfa-2b (if peginterferon alfa-2a is unavailable) may be substituted for other IFN preparations.[129-135] Observation (if asymptomatic) is appropriate for patients with multifocal lesions.

Brentuximab vedotin + CHP is included as an option under other recommended regimens for the primary treatment for patients with cutaneous ALCL with regional nodes.[292] Multiagent chemotherapy (CHOP or CHOEP [cyclophosphamide, doxorubicin, vincristine, etoposide, and prednisone]) with or without ISRT is included as an option for selected patients with regional lymph node involvement.[261,302]

Lymphomatoid Papulosis

It is important to be reminded that LyP is not a malignant disorder but a recurrent, benign, self-regressing lymphoid proliferation. Although multiagent chemotherapy often leads to reduction or clearance of lesions, rapid recurrence shortly after or even during treatment is a consistent finding in patients with LyP.

Version 2.2026 © 2026 National Comprehensive Cancer Network© (NCCN©), All rights reserved. NCCN Guidelines® and this illustration may not be reproduced in any form without the express written permission of NCCN.

PLEASE NOTE that use of this NCCN Content is governed by the End-User License Agreement, and you MAY NOT distribute this Content or use it with any artificial intelligence model or tool.
Printed by Galya Basol Kochav on 2/16/2026 9:44:21 AM. Copyright © 2026 National Comprehensive Cancer Network, Inc. All Rights Reserved.

In the aforementioned report from the Dutch Cutaneous Lymphoma Group that included 118 patients with LyP, topical steroids and phototherapy were the most common skin-directed therapies used as initial treatment in 56% and 35% of patients, respectively.[261] Although CR or partial response (PR) were common, none of these therapies resulted in sustained CR. In a retrospective multicenter study of 252 patients with LyP, topical steroids and phototherapy were the most common first-line treatments (prescribed in 35% and 14% of the patients, respectively) resulting in a CR rate of 48%.[303] The overall estimated median disease-free survival (DFS) was 11 months, but the DFS was longer for patients treated with phototherapy (23 months; $P < .03$). The presence of type A LyP and the use of first-line treatment other than phototherapy were significantly associated with increased risk of early cutaneous relapse.

In a retrospective study of 45 patients with LyP and other CD30+ PCTLD, low-dose methotrexate (≤25 mg) resulted in satisfactory disease control in 87% of patients, and the median total duration of treatment was >39 months for all patients.[304] After discontinuation, 25% of patients remained free of disease relapse during the follow-up period of 24 to 227 months. Another study that evaluated the efficacy of low-dose methotrexate in a cohort of 28 patients with LyP reported that satisfactory disease control could be achieved at 7.5- to 10-mg weekly doses of methotrexate.[293]

Observation is preferred for patients with asymptomatic disease. Topical steroids or phototherapy are appropriate initial treatment options for limited lesions (in symptomatic patients) or extensive lesions.[261,296,305-307] In patients receiving phototherapy, narrowband ultraviolet B (UVB) is generally preferred over psoralen plus ultraviolet A (PUVA). Systemic therapy is indicated only for patients with extensive lesions. Methotrexate is widely used for the treatment of LyP.[293,303,304,308-313] Systemic retinoids (bexarotene) are included as an option based on limited available data mainly from case reports.[295-298]

Follow-up and Treatment for Relapsed/Refractory Disease

Patients with a clinical benefit and/or those with disease responding to initial treatment can be considered for maintenance or tapering of regimens to optimize response duration. Patients with disease that does not have adequate response to initial treatment are generally treated with an alternative regimen recommended for initial treatment before moving on to treatment for refractory disease. Disease relapse often responds well to the same treatment. In patients with PC-ALCL, refractory disease to multiple prior therapies should be managed with systemic therapy options recommended for MF with LCT.

Brentuximab vedotin is included as an option for LyP that is refractory to multiple primary treatment options.[163,314] In a phase II study of 12 patients with refractory LyP, brentuximab vedotin resulted in an ORR of 100% and a CR rate of 58%.[314] The median duration of response was 20 weeks. Grade 1 or 2 peripheral neuropathy was the most common adverse event reported in 10 patients (83%). Further studies are needed to optimize the dosing to minimize the incidences of peripheral neuropathy.

Regular follow-up (including complete skin examination) is essential during observation since these patients can develop associated hematologic malignancies (particularly MF or ALCL) over time.[303,315] Life-long follow-up (including thorough skin examination) is warranted for patients with LyP (even for patients with disease responding to initial treatment) due to high risks for second lymphoid malignancies.

Version 2.2026 © 2026 National Comprehensive Cancer Network© (NCCN©), All rights reserved. NCCN Guidelines® and this illustration may not be reproduced in any form without the express written permission of NCCN.

PLEASE NOTE that use of this NCCN Content is governed by the End-User License Agreement, and you MAY NOT distribute this Content or use it with any artificial intelligence model or tool.
Printed by Galya Basol Kochav on 2/16/2026 9:44:21 AM. Copyright © 2026 National Comprehensive Cancer Network, Inc. All Rights Reserved.

Primary Cutaneous Indolent Lymphoproliferative Disorders

Primary cutaneous indolent T-cell lymphomas including primary cutaneous CD4-positive small/medium T-cell lymphoproliferative disorder (PCSM-TLPD) and primary cutaneous CD8-positive acral T-cell lymphoma (PCA-TCL) were previously classified as primary cutaneous lymphomas.[2] Both are associated with the absence of extracutaneous progression and have an excellent prognosis,[316] and these have since been re-classified as primary cutaneous indolent T-cell LPD by the revised 2022 WHO Classification of Hematolymphoid Tumors (WHO5) and International consensus classification (ICC), in order to distinguish these indolent entities from malignant variants of CTCL.[317,318]

PCSM-TLPD and PCA T-cell LPD (PCA-TLPD) are both characterized by clonal T-cell populations detected by *TCR* gene arrangement studies.[319,320] Concurrent immunoglobulin gene rearrangements may also be present in PCSM-TLPD.[320] PCSM-TLPD typically show a CD4+ T-follicular helper (TFH) phenotype while PCA-TLPD expresses CD8 with a cytotoxic phenotype.[319-321] Both these entities present with isolated asymptomatic nodules or plaques. Head and neck, trunk, or upper extremities are the most commons sites of involvement for PCSM-TLPD whereas ear, nose, or other acral sites are most commonly involved in PCA-TLPD.[319-321] PCSM-TLPD demonstrates frequent spontaneous remission. Imaging can be considered as part of the diagnostic workup to exclude the diagnosis of systemic lymphoma in patients presenting with generalized skin lesions or rapidly growing nodules or plaques.

Observation, topical or intralesional steroids, RT or surgical excision can be considered for symptomatic patients.[316] Low-dose RT (4 Gy in 1–2 fractions) has been shown to be effective for PCSM-TLPD, however the efficacy of low-dose RT in patients with PCA-TLPD is yet to be confirmed.[316,322,323] Aggressive treatment including systemic therapy is usually not needed and frequently can be avoided in patients with the confirmed diagnosis of PCSM-TLPD or PCA-TLPD. Surveillance imaging is not needed patients with confirmed diagnosis of PCSM-TLPD and PCA-TLPD due to low risk of relapse.[316]

Version 2.2026 © 2026 National Comprehensive Cancer Network© (NCCN©), All rights reserved. NCCN Guidelines® and this illustration may not be reproduced in any form without the express written permission of NCCN.

PLEASE NOTE that use of this NCCN Content is governed by the End-User License Agreement, and you MAY NOT distribute this Content or use it with any artificial intelligence model or tool.
Printed by Galya Basol Kochav on 2/16/2026 9:44:21 AM. Copyright © 2026 National Comprehensive Cancer Network, Inc. All Rights Reserved.

References

1. Bradford PT, Devesa SS, Anderson WF, Toro JR. Cutaneous lymphoma incidence patterns in the United States: a population-based study of 3884 cases. Blood 2009;113:5064–5073. Available at: https://www.ncbi.nlm.nih.gov/pubmed/19279331.

2. Willemze R, Cerroni L, Kempf W, et al. The 2018 update of the WHO-EORTC classification for primary cutaneous lymphomas. Blood 2019;133:1703–1714. Available at: https://www.ncbi.nlm.nih.gov/pubmed/30635287.

3. Teras LR, DeSantis CE, Cerhan JR, et al. 2016 US lymphoid malignancy statistics by World Health Organization subtypes. CA Cancer J Clin 2016;66:443–459. Available at: https://www.ncbi.nlm.nih.gov/pubmed/27618563.

4. Dummer R, Vermeer MH, Scarisbrick JJ, et al. Cutaneous T cell lymphoma. Nat Rev Dis Primers 2021;7:61. Available at: https://www.ncbi.nlm.nih.gov/pubmed/34446710.

5. Cai ZR, Chen ML, Weinstock MA, et al. Incidence trends of primary cutaneous T-cell lymphoma in the US from 2000 to 2018: A SEER population data analysis. JAMA Oncol 2022;8:1690–1692. Available at: https://www.ncbi.nlm.nih.gov/pubmed/36048455.

6. Campbell JJ, Clark RA, Watanabe R, Kupper TS. Sezary syndrome and mycosis fungoides arise from distinct T-cell subsets: a biologic rationale for their distinct clinical behaviors. Blood 2010;116:767–771. Available at: https://www.ncbi.nlm.nih.gov/pubmed/20484084.

7. Olsen EA, Rook AH, Zic J, et al. Sezary syndrome: immunopathogenesis, literature review of therapeutic options, and recommendations for therapy by the United States Cutaneous Lymphoma Consortium (USCLC). J Am Acad Dermatol 2011;64:352–404. Available at: https://www.ncbi.nlm.nih.gov/pubmed/21145619.

8. Diamandidou E, Colome-Grimmer M, Fayad L, et al. Transformation of mycosis fungoides/Sezary syndrome: clinical characteristics and prognosis. Blood 1998;92:1150–1159. Available at: https://www.ncbi.nlm.nih.gov/pubmed/9694702.

9. Vergier B, de Muret A, Beylot-Barry M, et al. Transformation of mycosis fungoides: clinicopathological and prognostic features of 45 cases. French Study Group of Cutaneious Lymphomas. Blood 2000;95:2212–2218. Available at: https://www.ncbi.nlm.nih.gov/pubmed/10733487.

10. Arulogun SO, Prince HM, Ng J, et al. Long-term outcomes of patients with advanced-stage cutaneous T-cell lymphoma and large cell transformation. Blood 2008;112:3082–3087. Available at: https://www.ncbi.nlm.nih.gov/pubmed/18647960.

11. Choi J, Goh G, Walradt T, et al. Genomic landscape of cutaneous T cell lymphoma. Nat Genet 2015;47:1011–1019. Available at: https://www.ncbi.nlm.nih.gov/pubmed/26192916.

12. Kann BH, Park HS, Yeboa DN, et al. Annual facility treatment volume and patient survival for mycosis fungoides and Sezary syndrome. Clin Lymphoma Myeloma Leuk 2017;17:520–526.e522. Available at: https://www.ncbi.nlm.nih.gov/pubmed/28655598.

13. PubMed Overview. Available at: https://pubmed.ncbi.nlm.nih.gov/about/. Accessed February 12, 2025.

14. Olsen EA, Whittaker S, Willemze R, et al. Primary cutaneous lymphoma: recommendations for clinical trial design and staging update from the ISCL, USCLC, and EORTC. Blood 2022;140:419–437. Available at: https://www.ncbi.nlm.nih.gov/pubmed/34758074.

15. de Coninck EC, Kim YH, Varghese A, Hoppe RT. Clinical characteristics and outcome of patients with extracutaneous mycosis fungoides. J Clin Oncol 2001;19:779–784. Available at: https://www.ncbi.nlm.nih.gov/pubmed/11157031.

16. Kim YH, Liu HL, Mraz-Gernhard S, et al. Long-term outcome of 525 patients with mycosis fungoides and Sezary syndrome: clinical prognostic factors and risk for disease progression. Arch Dermatol 2003;139:857–866. Available at: https://www.ncbi.nlm.nih.gov/pubmed/12873880.

Version 2.2026 © 2026 National Comprehensive Cancer Network© (NCCN©), All rights reserved. NCCN Guidelines® and this illustration may not be reproduced in any form without the express written permission of NCCN.

PLEASE NOTE that use of this NCCN Content is governed by the End-User License Agreement, and you MAY NOT distribute this Content or use it with any artificial intelligence model or tool.
Printed by Galya Basol Kochav on 2/16/2026 9:44:21 AM. Copyright © 2026 National Comprehensive Cancer Network, Inc. All Rights Reserved.

17. Vidulich KA, Talpur R, Bassett RL, Duvic M. Overall survival in erythrodermic cutaneous T-cell lymphoma: an analysis of prognostic factors in a cohort of patients with erythrodermic cutaneous T-cell lymphoma. Int J Dermatol 2009;48:243–252. Available at: https://www.ncbi.nlm.nih.gov/pubmed/19261011.

18. Agar NS, Wedgeworth E, Crichton S, et al. Survival outcomes and prognostic factors in mycosis fungoides/Sezary syndrome: validation of the revised International Society for Cutaneous Lymphomas/European Organisation for Research and Treatment of Cancer staging proposal. J Clin Oncol 2010;28:4730–4739. Available at: https://www.ncbi.nlm.nih.gov/pubmed/20855822.

19. Talpur R, Singh L, Daulat S, et al. Long-term outcomes of 1,263 patients with mycosis fungoides and Sezary syndrome from 1982 to 2009. Clin Cancer Res 2012;18:5051–5060. Available at: https://www.ncbi.nlm.nih.gov/pubmed/22850569.

20. Alberti-Violetti S, Talpur R, Schlichte M, et al. Advanced-stage mycosis fungoides and Sezary syndrome: survival and response to treatment. Clin Lymphoma Myeloma Leuk 2015;15:e105–112. Available at: https://www.ncbi.nlm.nih.gov/pubmed/25817937.

21. Scarisbrick JJ, Prince HM, Vermeer MH, et al. Cutaneous Lymphoma International Consortium study of outcome in advanced stages of mycosis fungoides and Sezary syndrome: Effect of specific prognostic markers on survival and development of a prognostic model. J Clin Oncol 2015;33:3766–3773. Available at: https://www.ncbi.nlm.nih.gov/pubmed/26438120.

22. Bontoux C, de Masson A, Thonnart N, et al. Large-cell transformation is an independent poor prognostic factor in Sezary syndrome: analysis of 117 cases. Br J Dermatol 2022;187:815–817. Available at: https://www.ncbi.nlm.nih.gov/pubmed/35791764.

23. Jairath NK, Bardhi R, Runge JS, et al. Predictors of large cell transformation in patients with Sezary Syndrome-A retrospective analysis. PLoS One 2022;17:e0277655. Available at: https://www.ncbi.nlm.nih.gov/pubmed/36383618.

24. Scarisbrick JJ, Quaglino P, Prince HM, et al. The PROCLIPI international registry of early-stage mycosis fungoides identifies substantial diagnostic delay in most patients. Br J Dermatol 2019;181:350–357. Available at: https://www.ncbi.nlm.nih.gov/pubmed/30267549.

25. Hodak E, Sherman S, Papadavid E, et al. Should we be imaging lymph nodes at initial diagnosis of early-stage mycosis fungoides? Results from the PROspective Cutaneous Lymphoma International Prognostic Index (PROCLIPI) international study. Br J Dermatol 2021;184:524–531. Available at: https://www.ncbi.nlm.nih.gov/pubmed/32574377.

26. Quaglino P, Prince HM, Cowan R, et al. Treatment of early-stage mycosis fungoides: results from the PROspective Cutaneous Lymphoma International Prognostic Index (PROCLIPI) study. Br J Dermatol 2021;184:722–730. Available at: https://www.ncbi.nlm.nih.gov/pubmed/32479678.

27. Kim EJ, Hess S, Richardson SK, et al. Immunopathogenesis and therapy of cutaneous T cell lymphoma. J Clin Invest 2005;115:798–812. Available at: https://www.ncbi.nlm.nih.gov/pubmed/15841167.

28. Martinez Villarreal A, Gantchev J, Lagace F, et al. Hypopigmented mycosis fungoides: loss of pigmentation reflects antitumor immune response in young patients. Cancers (Basel) 2020;12. Available at: https://www.ncbi.nlm.nih.gov/pubmed/32707930.

29. Jayasinghe DR, Dissanayake K, de Silva MVC. Comparison between the histopathological and immunophenotypical features of hypopigmented and nonhypopigmented mycosis fungoides: A retrospective study. J Cutan Pathol 2021;48:486–494. Available at: https://www.ncbi.nlm.nih.gov/pubmed/32965737.

30. Jung JM, Lee MY, Won CH, et al. Hyperpigmented mycosis fungoides: a retrospective and comparative analysis with other subtypes of mycosis fungoides. Leuk Lymphoma 2022;63:1598–1606. Available at: https://www.ncbi.nlm.nih.gov/pubmed/35201905.

Version 2.2026 © 2026 National Comprehensive Cancer Network© (NCCN©), All rights reserved. NCCN Guidelines® and this illustration may not be reproduced in any form without the express written permission of NCCN.

PLEASE NOTE that use of this NCCN Content is governed by the End-User License Agreement, and you MAY NOT distribute this Content or use it with any artificial intelligence model or tool.
Printed by Galya Basol Kochav on 2/16/2026 9:44:21 AM. Copyright © 2026 National Comprehensive Cancer Network, Inc. All Rights Reserved.

31. Beygi S, Duran GE, Fernandez-Pol S, et al. Resistance to mogamulizumab is associated with loss of CCR4 in cutaneous T-cell lymphoma. Blood 2022;139:3732–3736. Available at: https://www.ncbi.nlm.nih.gov/pubmed/35436328.

32. Thurber SE, Zhang B, Kim YH, et al. T-cell clonality analysis in biopsy specimens from two different skin sites shows high specificity in the diagnosis of patients with suggested mycosis fungoides. J Am Acad Dermatol 2007;57:782–790. Available at: https://www.ncbi.nlm.nih.gov/pubmed/17646032.

33. Zhang B, Beck AH, Taube JM, et al. Combined use of PCR-based TCRG and TCRB clonality tests on paraffin-embedded skin tissue in the differential diagnosis of mycosis fungoides and inflammatory dermatoses. J Mol Diagn 2010;12:320–327. Available at: https://www.ncbi.nlm.nih.gov/pubmed/20203005.

34. Kirsch IR, Watanabe R, O'Malley JT, et al. TCR sequencing facilitates diagnosis and identifies mature T cells as the cell of origin in CTCL. Sci Transl Med 2015;7:308ra158. Available at: https://www.ncbi.nlm.nih.gov/pubmed/26446955.

35. de Masson A, O'Malley JT, Elco CP, et al. High-throughput sequencing of the T cell receptor beta gene identifies aggressive early-stage mycosis fungoides. Sci Transl Med 2018;10:eaar5894. Available at: https://www.ncbi.nlm.nih.gov/pubmed/29743350.

36. Horna P, Wang SA, Wolniak KL, et al. Flow cytometric evaluation of peripheral blood for suspected Sezary syndrome or mycosis fungoides: International guidelines for assay characteristics. Cytometry B Clin Cytom 2021;100:142–155. Available at: https://www.ncbi.nlm.nih.gov/pubmed/32319723.

37. Martin-Moro F, Martin-Rubio I, Garcia-Vela JA. TRBC1 expression assessed by flow cytometry as a novel marker of clonality in cutaneous alphabeta T-cell lymphomas with peripheral blood involvement. Br J Dermatol 2022;187:623–625. Available at: https://www.ncbi.nlm.nih.gov/pubmed/35606929.

38. Castillo F, Morales C, Spralja B, et al. Integration of T-cell clonality screening using TRBC-1 in lymphoma suspect samples by flow cytometry. Cytometry B Clin Cytom 2024;106:64–73. Available at: https://www.ncbi.nlm.nih.gov/pubmed/38010106.

39. Nguyen PC, Nguyen T, Wilson C, et al. Evaluation of T-cell clonality by anti-TRBC1 antibody-based flow cytometry and correlation with T-cell receptor sequencing. Br J Haematol 2024;204:910–920. Available at: https://www.ncbi.nlm.nih.gov/pubmed/38098188.

40. Battistella M, Beylot-Barry M, Bachelez H, et al. Primary cutaneous follicular helper T-cell lymphoma: a new subtype of cutaneous T-cell lymphoma reported in a series of 5 cases. Arch Dermatol 2012;148:832–839. Available at: https://www.ncbi.nlm.nih.gov/pubmed/22508770.

41. Park JH, Han JH, Kang HY, et al. Expression of follicular helper T-cell markers in primary cutaneous T-cell lymphoma. Am J Dermatopathol 2014;36:465–470. Available at: https://www.ncbi.nlm.nih.gov/pubmed/24162385.

42. Bosisio FM, Cerroni L. Expression of T-follicular helper markers in sequential biopsies of progressive mycosis fungoides and other primary cutaneous T-cell lymphomas. Am J Dermatopathol 2015;37:115–121. Available at: https://www.ncbi.nlm.nih.gov/pubmed/25406852.

43. Park J, Yang J, Wenzel AT, et al. Genomic analysis of 220 CTCLs identifies a novel recurrent gain-of-function alteration in RLTPR (p.Q575E). Blood 2017;130:1430–1440. Available at: https://www.ncbi.nlm.nih.gov/pubmed/28694326.

44. Wang JY, Nguyen GH, Ruan J, Magro CM. Primary cutaneous follicular helper T-cell lymphoma: A case series and review of the literature. Am J Dermatopathol 2017;39:374–383. Available at: https://www.ncbi.nlm.nih.gov/pubmed/28375859.

45. Gallardo F, Pujol RM. Genetics abnormalities with clinical impact in primary cutaneous lymphomas. Cancers (Basel) 2022;14. Available at: https://www.ncbi.nlm.nih.gov/pubmed/36291756.

Version 2.2026 © 2026 National Comprehensive Cancer Network© (NCCN©), All rights reserved. NCCN Guidelines® and this illustration may not be reproduced in any form without the express written permission of NCCN.

PLEASE NOTE that use of this NCCN Content is governed by the End-User License Agreement, and you MAY NOT distribute this Content or use it with any artificial intelligence model or tool.
Printed by Galya Basol Kochav on 2/16/2026 9:44:21 AM. Copyright © 2026 National Comprehensive Cancer Network, Inc. All Rights Reserved.

46. Tsai EY, Taur A, Espinosa L, et al. Staging accuracy in mycosis fungoides and sezary syndrome using integrated positron emission tomography and computed tomography. Arch Dermatol 2006;142:577–584. Available at: https://www.ncbi.nlm.nih.gov/pubmed/16702495.

47. Zackheim HS, Kashani-Sabet M, Amin S. Topical corticosteroids for mycosis fungoides. Experience in 79 patients. Arch Dermatol 1998;134:949–954. Available at: https://www.ncbi.nlm.nih.gov/pubmed/9722724.

48. Zackheim HS. Treatment of patch-stage mycosis fungoides with topical corticosteroids. Dermatol Ther 2003;16:283–287. Available at: https://www.ncbi.nlm.nih.gov/pubmed/14686970.

49. Kartan S, Shalabi D, O'Donnell M, et al. Response to topical corticosteroid monotherapy in mycosis fungoides. J Am Acad Dermatol 2021;84:615–623. Available at: https://www.ncbi.nlm.nih.gov/pubmed/32428610.

50. Kim YH, Martinez G, Varghese A, Hoppe RT. Topical nitrogen mustard in the management of mycosis fungoides: update of the Stanford experience. Arch Dermatol 2003;139:165–173. Available at: https://www.ncbi.nlm.nih.gov/pubmed/12588222.

51. Lessin SR, Duvic M, Guitart J, et al. Topical chemotherapy in cutaneous T-cell lymphoma: positive results of a randomized, controlled, multicenter trial testing the efficacy and safety of a novel mechlorethamine, 0.02%, gel in mycosis fungoides. JAMA Dermatol 2013;149:25–32. Available at: https://www.ncbi.nlm.nih.gov/pubmed/23069814.

52. Breneman D, Duvic M, Kuzel T, et al. Phase 1 and 2 trial of bexarotene gel for skin-directed treatment of patients with cutaneous T-cell lymphoma. Arch Dermatol 2002;138:325–332. Available at: https://www.ncbi.nlm.nih.gov/pubmed/11902983.

53. Heald P, Mehlmauer M, Martin AG, et al. Topical bexarotene therapy for patients with refractory or persistent early-stage cutaneous T-cell lymphoma: results of the phase III clinical trial. J Am Acad Dermatol 2003;49:801–815. Available at: https://www.ncbi.nlm.nih.gov/pubmed/14576658.

54. Apisarnthanarax N, Talpur R, Ward S, et al. Tazarotene 0.1% gel for refractory mycosis fungoides lesions: an open-label pilot study. J Am Acad Dermatol 2004;50:600–607. Available at: https://www.ncbi.nlm.nih.gov/pubmed/15034511.

55. Besner Morin C, Roberge D, Turchin I, et al. Tazarotene 0.1% cream as monotherapy for early-stage cutaneous T-cell lymphoma. J Cutan Med Surg 2016;20:244–248. Available at: https://www.ncbi.nlm.nih.gov/pubmed/26742957.

56. Deeths MJ, Chapman JT, Dellavalle RP, et al. Treatment of patch and plaque stage mycosis fungoides with imiquimod 5% cream. J Am Acad Dermatol 2005;52:275–280. Available at: https://www.ncbi.nlm.nih.gov/pubmed/15692473.

57. Coors EA, Schuler G, Von Den Driesch P. Topical imiquimod as treatment for different kinds of cutaneous lymphoma. Eur J Dermatol 2006;16:391–393. Available at: https://www.ncbi.nlm.nih.gov/pubmed/16935796.

58. Martinez-Gonzalez MC, Verea-Hernando MM, Yebra-Pimentel MT, et al. Imiquimod in mycosis fungoides. Eur J Dermatol 2008;18:148–152. Available at: https://www.ncbi.nlm.nih.gov/pubmed/18424373.

59. Lewis DJ, Byekova YA, Emge DA, Duvic M. Complete resolution of mycosis fungoides tumors with imiquimod 5% cream: a case series. J Dermatolog Treat 2017;28:567–569. Available at: https://www.ncbi.nlm.nih.gov/pubmed/28635518.

60. Zackheim HS. Topical carmustine (BCNU) for patch/plaque mycosis fungoides. Semin Dermatol 1994;13:202–206. Available at: https://www.ncbi.nlm.nih.gov/pubmed/7986689.

61. Zackheim HS. Topical carmustine (BCNU) in the treatment of mycosis fungoides. Dermatol Ther 2003;16:299–302. Available at: https://www.ncbi.nlm.nih.gov/pubmed/14686972.

Version 2.2026 © 2026 National Comprehensive Cancer Network© (NCCN©), All rights reserved. NCCN Guidelines® and this illustration may not be reproduced in any form without the express written permission of NCCN.

PLEASE NOTE that use of this NCCN Content is governed by the End-User License Agreement, and you MAY NOT distribute this Content or use it with any artificial intelligence model or tool.
Printed by Galya Basol Kochav on 2/16/2026 9:44:21 AM. Copyright © 2026 National Comprehensive Cancer Network, Inc. All Rights Reserved.

62. Ortiz-Romero PL, Maronas Jimenez L, Muniesa C, et al. Activity and safety of topical pimecrolimus in patients with early stage mycosis fungoides (PimTo-MF): a single-arm, multicentre, phase 2 trial. Lancet Haematol 2022;9:e425–e433. Available at: https://www.ncbi.nlm.nih.gov/pubmed/35654076.

63. Weiner DM, Clark AK, Bhansali RS, et al. Usage and safety of topical tacrolimus in patients with mycosis fungoides. Clin Exp Dermatol 2022;47:1200–1201. Available at: https://www.ncbi.nlm.nih.gov/pubmed/35245947.

64. Piccinno R, Caccialanza M, Cuka E, Recalcati S. Localized conventional radiotherapy in the treatment of Mycosis Fungoides: our experience in 100 patients. J Eur Acad Dermatol Venereol 2014;28:1040–1044. Available at: https://www.ncbi.nlm.nih.gov/pubmed/23998331.

65. Specht L, Dabaja B, Illidge T, et al. Modern radiation therapy for primary cutaneous lymphomas: field and dose guidelines from the International Lymphoma Radiation Oncology Group. Int J Radiat Oncol Biol Phys 2015;92:32–39. Available at: https://www.ncbi.nlm.nih.gov/pubmed/25863751.

66. Neelis KJ, Schimmel EC, Vermeer MH, et al. Low-dose palliative radiotherapy for cutaneous B- and T-cell lymphomas. Int J Radiat Oncol Biol Phys 2009;74:154–158. Available at: https://www.ncbi.nlm.nih.gov/pubmed/18834672.

67. Thomas TO, Agrawal P, Guitart J, et al. Outcome of patients treated with a single-fraction dose of palliative radiation for cutaneous T-cell lymphoma. Int J Radiat Oncol Biol Phys 2013;85:747–753. Available at: https://www.ncbi.nlm.nih.gov/pubmed/22818412.

68. Elsayad K, Guenova E, Assaf C, et al. Radiotherapy in cutaneous lymphomas: Recommendations from the EORTC cutaneous lymphoma tumour group. Eur J Cancer 2024;212:115064. Available at: https://www.ncbi.nlm.nih.gov/pubmed/39418694.

69. Ysebaert L, Truc G, Dalac S, et al. Ultimate results of radiation therapy for T1-T2 mycosis fungoides (including reirradiation). Int J Radiat Oncol Biol Phys 2004;58:1128–1134. Available at: https://www.ncbi.nlm.nih.gov/pubmed/15001254.

70. Harrison C, Young J, Navi D, et al. Revisiting low-dose total skin electron beam therapy in mycosis fungoides. Int J Radiat Oncol Biol Phys 2011;81:e651–657. Available at: https://www.ncbi.nlm.nih.gov/pubmed/21489711.

71. Navi D, Riaz N, Levin YS, et al. The Stanford University experience with conventional-dose, total skin electron-beam therapy in the treatment of generalized patch or plaque (T2) and tumor (T3) mycosis fungoides. Arch Dermatol 2011;147:561–567. Available at: https://www.ncbi.nlm.nih.gov/pubmed/21576575.

72. Elsayad K, Kriz J, Moustakis C, et al. Total skin electron beam for primary cutaneous T-cell lymphoma. Int J Radiat Oncol Biol Phys 2015;93:1077–1086. Available at: https://www.ncbi.nlm.nih.gov/pubmed/26581145.

73. Kamstrup MR, Lindahl LM, Gniadecki R, et al. Low-dose total skin electron beam therapy as a debulking agent for cutaneous T-cell lymphoma: an open-label prospective phase II study. Br J Dermatol 2012;166:399–404. Available at: https://www.ncbi.nlm.nih.gov/pubmed/21967035.

74. Hoppe RT, Harrison C, Tavallaee M, et al. Low-dose total skin electron beam therapy as an effective modality to reduce disease burden in patients with mycosis fungoides: results of a pooled analysis from 3 phase-II clinical trials. J Am Acad Dermatol 2015;72:286–292. Available at: https://www.ncbi.nlm.nih.gov/pubmed/25476993.

75. Kamstrup MR, Gniadecki R, Iversen L, et al. Low-dose (10-Gy) total skin electron beam therapy for cutaneous T-cell lymphoma: an open clinical study and pooled data analysis. Int J Radiat Oncol Biol Phys 2015;92:138–143. Available at: https://www.ncbi.nlm.nih.gov/pubmed/25863761.

76. Kroeger K, Elsayad K, Moustakis C, et al. Low-dose total skin electron beam therapy for cutaneous lymphoma : Minimal risk of acute toxicities.

Version 2.2026 © 2026 National Comprehensive Cancer Network© (NCCN©), All rights reserved. NCCN Guidelines® and this illustration may not be reproduced in any form without the express written permission of NCCN.

PLEASE NOTE that use of this NCCN Content is governed by the End-User License Agreement, and you MAY NOT distribute this Content or use it with any artificial intelligence model or tool.
Printed by Galya Basol Kochav on 2/16/2026 9:44:21 AM. Copyright © 2026 National Comprehensive Cancer Network, Inc. All Rights Reserved.

Strahlenther Onkol 2017;193:1024–1030. Available at: https://www.ncbi.nlm.nih.gov/pubmed/28785772.

77. Morris S, Scarisbrick J, Frew J, et al. The results of low-dose total skin electron beam radiation therapy (TSEB) in patients with mycosis fungoides from the UK cutaneous lymphoma group. Int J Radiat Oncol Biol Phys 2017;99:627–633. Available at: https://www.ncbi.nlm.nih.gov/pubmed/28843374.

78. Georgakopoulos I, Papadavid E, Platoni K, et al. Low dose total skin electron beam therapy for the management of T cell cutaneous lymphomas. Dermatol Ther 2020;33:e13478. Available at: https://www.ncbi.nlm.nih.gov/pubmed/32391976.

79. Song A, Gochoco A, Zhan T, et al. A prospective cohort study of condensed low-dose total skin electron beam therapy for mycosis fungoides: Reduction of disease burden and improvement in quality of life. J Am Acad Dermatol 2020;83:78–85. Available at: https://www.ncbi.nlm.nih.gov/pubmed/32004646.

80. Elsayad K, Kroeger K, Greve B, et al. Low-dose total skin electron beam therapy: Quality of life improvement and clinical impact of maintenance and adjuvant treatment in patients with mycosis fungoides or Sezary syndrome. Strahlenther Onkol 2020;196:77–84. Available at: https://www.ncbi.nlm.nih.gov/pubmed/31591658.

81. Kudelka MR, Switchenko JM, Lechowicz MJ, et al. Maintenance therapy for cutaneous T-cell lymphoma after total skin electron irradiation: Evidence for improved overall survival with ultraviolet therapy. Clin Lymphoma Myeloma Leuk 2020;20:757–767 e753. Available at: https://www.ncbi.nlm.nih.gov/pubmed/32703750.

82. Elsayad K, Rolf D, Sunderkotter C, et al. Low-dose total skin electron beam therapy plus oral bexarotene maintenance therapy for cutaneous T-cell lymphoma. J Dtsch Dermatol Ges 2022;20:279–285. Available at: https://www.ncbi.nlm.nih.gov/pubmed/34984837.

83. Gathers RC, Scherschun L, Malick F, et al. Narrowband UVB phototherapy for early-stage mycosis fungoides. J Am Acad Dermatol 2002;47:191–197. Available at: https://www.ncbi.nlm.nih.gov/pubmed/12140464.

84. Dereure O, Picot E, Comte C, et al. Treatment of early stages of mycosis fungoides with narrowband ultraviolet B. A clinical, histological and molecular evaluation of results. Dermatology 2009;218:1–6. Available at: https://www.ncbi.nlm.nih.gov/pubmed/18832806.

85. Gokdemir G, Barutcuoglu B, Sakiz D, Koslu A. Narrowband UVB phototherapy for early-stage mycosis fungoides: evaluation of clinical and histopathological changes. J Eur Acad Dermatol Venereol 2006;20:804–809. Available at: https://www.ncbi.nlm.nih.gov/pubmed/16898902.

86. Drucker AM, Baibergenova A, Rosen CF, Shear NH. Narrowband UVB as an effective substitute for psoralen plus UVA: lessons from a psoralen shortage. Photodermatol Photoimmunol Photomed 2012;28:267–268. Available at: https://www.ncbi.nlm.nih.gov/pubmed/22971194.

87. Elcin G, Duman N, Karahan S, et al. Long-term follow-up of early mycosis fungoides patients treated with narrowband ultraviolet B phototherapy. J Dermatolog Treat 2014;25:268–273. Available at: https://www.ncbi.nlm.nih.gov/pubmed/23030414.

88. Querfeld C, Rosen ST, Kuzel TM, et al. Long-term follow-up of patients with early-stage cutaneous T-cell lymphoma who achieved complete remission with psoralen plus UV-A monotherapy. Arch Dermatol 2005;141:305–311. Available at: https://www.ncbi.nlm.nih.gov/pubmed/15781671.

89. Pavlotsky F, Hodak E, Ben Amitay D, Barzilai A. Role of bath psoralen plus ultraviolet A in early-stage mycosis fungoides. J Am Acad Dermatol 2014;71:536–541. Available at: https://www.ncbi.nlm.nih.gov/pubmed/24836546.

90. Amitay-Laish I, Prag-Naveh H, Dalal A, et al. Treatment of early folliculotropic mycosis fungoides with special focus on psoralen plus ultraviolet A. Acta Derm Venereol 2018;98:951–955. Available at: https://www.ncbi.nlm.nih.gov/pubmed/30085321.

Version 2.2026 © 2026 National Comprehensive Cancer Network© (NCCN©), All rights reserved. NCCN Guidelines® and this illustration may not be reproduced in any form without the express written permission of NCCN.

PLEASE NOTE that use of this NCCN Content is governed by the End-User License Agreement, and you MAY NOT distribute this Content or use it with any artificial intelligence model or tool.
Printed by Galya Basol Kochav on 2/16/2026 9:44:21 AM. Copyright © 2026 National Comprehensive Cancer Network, Inc. All Rights Reserved.

91. Vieyra-Garcia P, Fink-Puches R, Porkert S, et al. Evaluation of low-dose, low-frequency oral psoralen-UV-A treatment with or without maintenance on early-stage mycosis fungoides: A randomized clinical trial. JAMA Dermatol 2019;155:538–547. Available at: https://www.ncbi.nlm.nih.gov/pubmed/30892603.

92. Almohideb M, Walsh S, Walsh S, et al. Bath psoralen-ultraviolet A and narrowband ultraviolet B phototherapy as initial therapy for early-stage mycosis fungoides: A retrospective cohort of 267 cases at the University of Toronto. Clin Lymphoma Myeloma Leuk 2017;17:604–612. Available at: https://www.ncbi.nlm.nih.gov/pubmed/28711574.

93. Nikolaou V, Sachlas A, Papadavid E, et al. Phototherapy as a first-line treatment for early-stage mycosis fungoides: The results of a large retrospective analysis. Photodermatol Photoimmunol Photomed 2018;34:307–313. Available at: https://www.ncbi.nlm.nih.gov/pubmed/29533478.

94. Phan K, Ramachandran V, Fassihi H, Sebaratnam DF. Comparison of narrowband UV-B with psoralen-UV-A phototherapy for patients with early-stage mycosis fungoides: a systematic review and meta-analysis. JAMA Dermatol 2019;155:335–341. Available at: https://www.ncbi.nlm.nih.gov/pubmed/30698622.

95. Ahmad K, Rogers S, McNicholas PD, Collins P. Narrowband UVB and PUVA in the treatment of mycosis fungoides: a retrospective study. Acta Derm Venereol 2007;87:413–417. Available at: https://www.ncbi.nlm.nih.gov/pubmed/17721648.

96. Ponte P, Serrao V, Apetato M. Efficacy of narrowband UVB vs. PUVA in patients with early-stage mycosis fungoides. J Eur Acad Dermatol Venereol 2010;24:716–721. Available at: https://www.ncbi.nlm.nih.gov/pubmed/19929938.

97. Hearn RM, Kerr AC, Rahim KF, et al. Incidence of skin cancers in 3867 patients treated with narrow-band ultraviolet B phototherapy. Br J Dermatol 2008;159:931–935. Available at: https://www.ncbi.nlm.nih.gov/pubmed/18834483.

98. Ahad T, Wang EY, Liu YA, et al. Incidence of skin cancers in patients with eczema treated with ultraviolet phototherapy. J Am Acad Dermatol 2022;87:387–389. Available at: https://www.ncbi.nlm.nih.gov/pubmed/34864113.

99. Wang E, Ahad T, Liu YA, et al. Incidence and profile of skin cancers in patients following ultraviolet phototherapy without psoralens: A retrospective cohort study. J Am Acad Dermatol 2024;90:759–766. Available at: https://www.ncbi.nlm.nih.gov/pubmed/38070541.

100. Diederen PV, van Weelden H, Sanders CJ, et al. Narrowband UVB and psoralen-UVA in the treatment of early-stage mycosis fungoides: a retrospective study. J Am Acad Dermatol 2003;48:215–219. Available at: https://www.ncbi.nlm.nih.gov/pubmed/12582391.

101. Olsen EA, Hodak E, Anderson T, et al. Guidelines for phototherapy of mycosis fungoides and Sezary syndrome: A consensus statement of the United States Cutaneous Lymphoma Consortium. J Am Acad Dermatol 2016;74:27–58. Available at: https://www.ncbi.nlm.nih.gov/pubmed/26547257.

102. Khodadoust MS, Mou E, Kim YH. Integrating novel agents into the treatment of advanced mycosis fungoides and Sezary syndrome. Blood 2023;141:695–703. Available at: https://www.ncbi.nlm.nih.gov/pubmed/36379025.

103. Prince HM, Kim YH, Horwitz SM, et al. Brentuximab vedotin or physician's choice in CD30-positive cutaneous T-cell lymphoma (ALCANZA): an international, open-label, randomised, phase 3, multicentre trial. Lancet 2017;390:555–566. Available at: https://www.ncbi.nlm.nih.gov/pubmed/28600132.

104. Horwitz SM, Scarisbrick JJ, Dummer R, et al. Randomized phase 3 ALCANZA study of brentuximab vedotin vs physician's choice in cutaneous T-cell lymphoma: final data. Blood Adv 2021;5:5098–5106. Available at: https://www.ncbi.nlm.nih.gov/pubmed/34507350.

105. Kim YH, Bagot M, Pinter-Brown L, et al. Mogamulizumab versus vorinostat in previously treated cutaneous T-cell lymphoma (MAVORIC):

Version 2.2026 © 2026 National Comprehensive Cancer Network© (NCCN©), All rights reserved. NCCN Guidelines® and this illustration may not be reproduced in any form without the express written permission of NCCN.

PLEASE NOTE that use of this NCCN Content is governed by the End-User License Agreement, and you MAY NOT distribute this Content or use it with any artificial intelligence model or tool.
Printed by Galya Basol Kochav on 2/16/2026 9:44:21 AM. Copyright © 2026 National Comprehensive Cancer Network, Inc. All Rights Reserved.

an international, open-label, randomised, controlled phase 3 trial. Lancet Oncol 2018;19:1192–1204. Available at: https://www.ncbi.nlm.nih.gov/pubmed/30100375.

106. Foss FM, Kim YH, Prince HM, et al. Efficacy and Safety of Denileukin Diftitox-Cxdl, an Improved Purity Formulation of Denileukin Diftitox, in Patients With Relapsed or Refractory Cutaneous T-Cell Lymphoma. J Clin Oncol 2025;43:1198–1209. Available at: https://www.ncbi.nlm.nih.gov/pubmed/39700456.

107. Duvic M, Martin AG, Kim Y, et al. Phase 2 and 3 clinical trial of oral bexarotene (Targretin capsules) for the treatment of refractory or persistent early-stage cutaneous T-cell lymphoma. Arch Dermatol 2001;137:581–593. Available at: https://www.ncbi.nlm.nih.gov/pubmed/11346336.

108. Duvic M, Hymes K, Heald P, et al. Bexarotene is effective and safe for treatment of refractory advanced-stage cutaneous T-cell lymphoma: multinational phase II-III trial results. J Clin Oncol 2001;19:2456–2471. Available at: https://www.ncbi.nlm.nih.gov/pubmed/11331325.

109. Duvic M, Talpur R, Ni X, et al. Phase 2 trial of oral vorinostat (suberoylanilide hydroxamic acid, SAHA) for refractory cutaneous T-cell lymphoma (CTCL). Blood 2007;109:31–39. Available at: https://www.ncbi.nlm.nih.gov/pubmed/16960145.

110. Olsen EA, Kim YH, Kuzel TM, et al. Phase IIb multicenter trial of vorinostat in patients with persistent, progressive, or treatment refractory cutaneous T-cell lymphoma. J Clin Oncol 2007;25:3109–3115. Available at: https://www.ncbi.nlm.nih.gov/pubmed/17577020.

111. Duvic M, Olsen EA, Breneman D, et al. Evaluation of the long-term tolerability and clinical benefit of vorinostat in patients with advanced cutaneous T-cell lymphoma. Clin Lymphoma Myeloma 2009;9:412–416. Available at: https://www.ncbi.nlm.nih.gov/pubmed/19951879.

112. Piekarz RL, Frye R, Turner M, et al. Phase II multi-institutional trial of the histone deacetylase inhibitor romidepsin as monotherapy for patients with cutaneous T-cell lymphoma. J Clin Oncol 2009;27:5410–5417. Available at: http://www.ncbi.nlm.nih.gov/pubmed/19826128.

113. Whittaker SJ, Demierre MF, Kim EJ, et al. Final results from a multicenter, international, pivotal study of romidepsin in refractory cutaneous T-cell lymphoma. J Clin Oncol 2010;28:4485–4491. Available at: https://www.ncbi.nlm.nih.gov/pubmed/20697094.

114. Kim EJ, Kim YH, Rook AH, et al. Clinically significant responses achieved with romidepsin across disease compartments in patients with cutaneous T-cell lymphoma. Leuk Lymphoma 2015;56:2847–2854. Available at: https://www.ncbi.nlm.nih.gov/pubmed/25791237.

115. Horwitz SM, Kim YH, Foss F, et al. Identification of an active, well-tolerated dose of pralatrexate in patients with relapsed or refractory cutaneous T-cell lymphoma. Blood 2012;119:4115–4122. Available at: https://www.ncbi.nlm.nih.gov/pubmed/22394596.

116. Foss F, Horwitz SM, Coiffier B, et al. Pralatrexate is an effective treatment for relapsed or refractory transformed mycosis fungoides: a subgroup efficacy analysis from the PROPEL study. Clin Lymphoma Myeloma Leuk 2012;12:238–243. Available at: https://www.ncbi.nlm.nih.gov/pubmed/22542448.

117. Talpur R, Thompson A, Gangar P, Duvic M. Pralatrexate alone or in combination with bexarotene: long-term tolerability in relapsed/refractory mycosis fungoides. Clin Lymphoma Myeloma Leuk 2014;14:297–304. Available at: https://www.ncbi.nlm.nih.gov/pubmed/24589156.

118. Kennedy GA, Seymour JF, Wolf M, et al. Treatment of patients with advanced mycosis fungoides and Sezary syndrome with alemtuzumab. Eur J Haematol 2003;71:250–256. Available at: https://www.ncbi.nlm.nih.gov/pubmed/12950233.

119. Lundin J, Hagberg H, Repp R, et al. Phase 2 study of alemtuzumab (anti-CD52 monoclonal antibody) in patients with advanced mycosis fungoides/Sezary syndrome. Blood 2003;101:4267–4272. Available at: https://www.ncbi.nlm.nih.gov/pubmed/12543862.

Version 2.2026 © 2026 National Comprehensive Cancer Network© (NCCN©), All rights reserved. NCCN Guidelines® and this illustration may not be reproduced in any form without the express written permission of NCCN.

PLEASE NOTE that use of this NCCN Content is governed by the End-User License Agreement, and you MAY NOT distribute this Content or use it with any artificial intelligence model or tool.
Printed by Galya Basol Kochav on 2/16/2026 9:44:21 AM. Copyright © 2026 National Comprehensive Cancer Network, Inc. All Rights Reserved.

120. Bernengo MG, Quaglino P, Comessatti A, et al. Low-dose intermittent alemtuzumab in the treatment of Sezary syndrome: clinical and immunologic findings in 14 patients. Haematologica 2007;92:784–794. Available at: https://www.ncbi.nlm.nih.gov/pubmed/17550851.

121. Alinari L, Geskin L, Grady T, et al. Subcutaneous alemtuzumab for Sezary Syndrome in the very elderly. Leuk Res 2008;32:1299–1303. Available at: http://www.ncbi.nlm.nih.gov/pubmed/18096224.

122. Querfeld C, Mehta N, Rosen ST, et al. Alemtuzumab for relapsed and refractory erythrodermic cutaneous T-cell lymphoma: a single institution experience from the Robert H. Lurie Comprehensive Cancer Center. Leuk Lymphoma 2009;50:1969–1976. Available at: https://www.ncbi.nlm.nih.gov/pubmed/19860617.

123. de Masson A, Guitera P, Brice P, et al. Long-term efficacy and safety of alemtuzumab in advanced primary cutaneous T-cell lymphomas. Br J Dermatol 2014;170:720–724. Available at: https://www.ncbi.nlm.nih.gov/pubmed/24438061.

124. Khodadoust MS, Rook AH, Porcu P, et al. Pembrolizumab in relapsed and refractory mycosis fungoides and Sezary syndrome: A multicenter phase II study. J Clin Oncol 2020;38:20–28. Available at: https://www.ncbi.nlm.nih.gov/pubmed/31532724.

125. Olsen EA. Interferon in the treatment of cutaneous T-cell lymphoma. Dermatol Ther 2003;16:311–321. Available at: https://www.ncbi.nlm.nih.gov/pubmed/14686974.

126. Kaplan EH, Rosen ST, Norris DB, et al. Phase II study of recombinant human interferon gamma for treatment of cutaneous T-cell lymphoma. J Natl Cancer Inst 1990;82:208–212. Available at: https://www.ncbi.nlm.nih.gov/pubmed/2104937.

127. Zackheim HS, Kashani-Sabet M, McMillan A. Low-dose methotrexate to treat mycosis fungoides: a retrospective study in 69 patients. J Am Acad Dermatol 2003;49:873–878. Available at: https://www.ncbi.nlm.nih.gov/pubmed/14576667.

128. Nikolaou V, Panou E, Tsimpidakis A, et al. Effectiveness and safety of methotrexate in the treatment of mycosis fungoides: Real-world data from a multicentre study. J Eur Acad Dermatol Venereol 2024. Available at: https://www.ncbi.nlm.nih.gov/pubmed/39297278.

129. Schiller M, Tsianakas A, Sterry W, et al. Dose-escalation study evaluating pegylated interferon alpha-2a in patients with cutaneous T-cell lymphoma. J Eur Acad Dermatol Venereol 2017;31:1841–1847. Available at: https://www.ncbi.nlm.nih.gov/pubmed/28557110.

130. Patsatsi A, Papadavid E, Kyriakou A, et al. The use of pegylated interferon a-2a in a cohort of Greek patients with mycosis fungoides. J Eur Acad Dermatol Venereol 2022;36:e291–e293. Available at: https://www.ncbi.nlm.nih.gov/pubmed/34753217.

131. Osman S, Chia JC, Street L, Hardin J. Transitioning to pegylated interferon for the treatment of cutaneous T-cell lymphoma: Meeting the challenge of therapy discontinuation and a proposed algorithm. Dermatologic Therapy 2023;2023:7171937. Available at: https://doi.org/10.1155/2023/7171937.

132. Gosmann J, Stadler R, Quint KD, et al. Use of pegylated interferon alpha-2a in cutaneous T-cell lymphoma: A retrospective case collection. Acta Derm Venereol 2023;103:adv10306. Available at:

133. Hansen-Abeck I, Geidel G, Abeck F, et al. Pegylated interferon-alpha2a in cutaneous T-cell lymphoma - a multicenter retrospective data analysis with 70 patients. J Dtsch Dermatol Ges 2024;22:1489–1497. Available at: https://www.ncbi.nlm.nih.gov/pubmed/39358932.

134. Mitsunaga K, Bagot M, Ram-Wolff C, et al. Real-world study of pegylated interferon alpha-2a to treat mycosis fungoides/Sezary syndrome using time to next treatment as a measure of clinical benefit: an EORTC CLTG study. Br J Dermatol 2024;191:419–427. Available at: https://www.ncbi.nlm.nih.gov/pubmed/38596857.

135. Mesa R, Yacoub A, Tashi T, et al. Navigating the peginterferon alfa-2a shortage: practical guidance on transitioning patients to ropeginterferon

Version 2.2026 © 2026 National Comprehensive Cancer Network© (NCCN©), All rights reserved. NCCN Guidelines® and this illustration may not be reproduced in any form without the express written permission of NCCN.

PLEASE NOTE that use of this NCCN Content is governed by the End-User License Agreement, and you MAY NOT distribute this Content or use it with any artificial intelligence model or tool.
Printed by Galya Basol Kochav on 2/16/2026 9:44:21 AM. Copyright © 2026 National Comprehensive Cancer Network, Inc. All Rights Reserved.

alfa-2b. Ann Hematol 2025;104:2571–2573. Available at: https://www.ncbi.nlm.nih.gov/pubmed/40178604.

136. McGirt LY, Thoburn C, Hess A, Vonderheid EC. Predictors of response to extracorporeal photopheresis in advanced mycosis fungoides and Sezary syndrome. Photodermatol Photoimmunol Photomed 2010;26:182–191. Available at: https://www.ncbi.nlm.nih.gov/pubmed/20626820.

137. Quaglino P, Knobler R, Fierro MT, et al. Extracorporeal photopheresis for the treatment of erythrodermic cutaneous T-cell lymphoma: a single center clinical experience with long-term follow-up data and a brief overview of the literature. Int J Dermatol 2013;52:1308–1318. Available at: https://www.ncbi.nlm.nih.gov/pubmed/23786842.

138. Knobler R, Arenberger P, Arun A, et al. European dermatology forum - updated guidelines on the use of extracorporeal photopheresis 2020 - part 1. J Eur Acad Dermatol Venereol 2020;34:2693–2716. Available at: https://www.ncbi.nlm.nih.gov/pubmed/33025659.

139. Zinzani PL, Baliva G, Magagnoli M, et al. Gemcitabine treatment in pretreated cutaneous T-cell lymphoma: experience in 44 patients. J Clin Oncol 2000;18:2603–2606. Available at: https://www.ncbi.nlm.nih.gov/pubmed/10893292.

140. Marchi E, Alinari L, Tani M, et al. Gemcitabine as frontline treatment for cutaneous T-cell lymphoma: phase II study of 32 patients. Cancer 2005;104:2437–2441. Available at: https://www.ncbi.nlm.nih.gov/pubmed/16216001.

141. Duvic M, Talpur R, Wen S, et al. Phase II evaluation of gemcitabine monotherapy for cutaneous T-cell lymphoma. Clin Lymphoma Myeloma 2006;7:51–58. Available at: https://www.ncbi.nlm.nih.gov/pubmed/16879770.

142. Jidar K, Ingen-Housz-Oro S, Beylot-Barry M, et al. Gemcitabine treatment in cutaneous T-cell lymphoma: a multicentre study of 23 cases. Br J Dermatol 2009;161:660–663. Available at: https://www.ncbi.nlm.nih.gov/pubmed/19438862.

143. Pellegrini C, Stefoni V, Casadei B, et al. Long-term outcome of patients with advanced-stage cutaneous T cell lymphoma treated with gemcitabine. Ann Hematol 2014;93:1853–1857. Available at: https://www.ncbi.nlm.nih.gov/pubmed/24908331.

144. Blazejak C, Stranzenbach R, Gosman J, et al. Clinical outcomes of advanced-stage cutaneous lymphoma under low-dose gemcitabine treatment: Real-life data from the German Cutaneous Lymphoma Network. Dermatology 2022;238:498–506. Available at: https://www.ncbi.nlm.nih.gov/pubmed/34474414.

145. Di Raimondo C, Vaccarini S, Nunzi A, et al. Continuous low-dose gemcitabine in primary cutaneous T cell lymphoma: A retrospective study. Dermatol Ther 2022;35:e15482. Available at: https://www.ncbi.nlm.nih.gov/pubmed/35373414.

146. Weiner D, Ly A, Talluru S, et al. Efficacy of single-agent chemotherapy with pegylated liposomal doxorubicin or gemcitabine in a diverse cohort of patients with recalcitrant cutaneous T-cell lymphoma. Br J Dermatol 2024;190:436–438. Available at: https://www.ncbi.nlm.nih.gov/pubmed/37655919.

147. Pulini S, Rupoli S, Goteri G, et al. Pegylated liposomal doxorubicin in the treatment of primary cutaneous T-cell lymphomas. Haematologica 2007;92:686–689. Available at: https://www.ncbi.nlm.nih.gov/pubmed/17488695.

148. Quereux G, Marques S, Nguyen JM, et al. Prospective multicenter study of pegylated liposomal doxorubicin treatment in patients with advanced or refractory mycosis fungoides or Sezary syndrome. Arch Dermatol 2008;144:727–733. Available at: https://www.ncbi.nlm.nih.gov/pubmed/18559761.

149. Dummer R, Quaglino P, Becker JC, et al. Prospective international multicenter phase II trial of intravenous pegylated liposomal doxorubicin monochemotherapy in patients with stage IIB, IVA, or IVB advanced mycosis fungoides: final results from EORTC 21012. J Clin Oncol 2012;30:4091–4097. Available at: https://www.ncbi.nlm.nih.gov/pubmed/23045580.

Version 2.2026 © 2026 National Comprehensive Cancer Network© (NCCN©), All rights reserved. NCCN Guidelines® and this illustration may not be reproduced in any form without the express written permission of NCCN.

PLEASE NOTE that use of this NCCN Content is governed by the End-User License Agreement, and you MAY NOT distribute this Content or use it with any artificial intelligence model or tool.
Printed by Galya Basol Kochav on 2/16/2026 9:44:21 AM. Copyright © 2026 National Comprehensive Cancer Network, Inc. All Rights Reserved.

150. Falkenhain-Lopez D, Fulgencio-Barbarin J, Puerta-Pena M, et al. Single-centre experience of using pegylated liposomal doxorubicin as maintenance treatment in mycosis fungoides. Br J Dermatol 2022;186:363–365. Available at: https://www.ncbi.nlm.nih.gov/pubmed/34528240.

151. Falkenhain-Lopez D, Puerta-Pena M, Fulgencio-Barbarin J, et al. Real-life experience of using pegylated liposomal doxorubicin in primary cutaneous T-cell lymphomas. Clin Exp Dermatol 2022;47:1712–1715. Available at: https://www.ncbi.nlm.nih.gov/pubmed/35426448.

152. Hughes CF, Khot A, McCormack C, et al. Lack of durable disease control with chemotherapy for mycosis fungoides and Sezary syndrome: a comparative study of systemic therapy. Blood 2015;125:71–81. Available at: https://www.ncbi.nlm.nih.gov/pubmed/25336628.

153. Quaglino P, Maule M, Prince HM, et al. Global patterns of care in advanced stage mycosis fungoides/Sezary syndrome: a multicenter retrospective follow-up study from the Cutaneous Lymphoma International Consortium. Ann Oncol 2017;28:2517–2525. Available at: https://www.ncbi.nlm.nih.gov/pubmed/28961843.

154. Izu-Belloso R, Gainza-Apraiz I, Ortiz-Romero P, et al. Experience with bexarotene to treat cutaneous T-cell lymphomas: A study of the Spanish Working Group of cutaneous lymphomas. Actas Dermosifiliogr 2024;115:547–554. Available at: https://www.ncbi.nlm.nih.gov/pubmed/38395224.

155. Whittaker S, Ortiz P, Dummer R, et al. Efficacy and safety of bexarotene combined with psoralen-ultraviolet A (PUVA) compared with PUVA treatment alone in stage IB-IIA mycosis fungoides: final results from the EORTC Cutaneous Lymphoma Task Force phase III randomized clinical trial (NCT00056056). Br J Dermatol 2012;167:678–687. Available at: https://www.ncbi.nlm.nih.gov/pubmed/22924950.

156. Duvic M, Apisarnthanarax N, Cohen DS, et al. Analysis of long-term outcomes of combined modality therapy for cutaneous T-cell lymphoma. J Am Acad Dermatol 2003;49:35–49. Available at: https://www.ncbi.nlm.nih.gov/pubmed/12833006.

157. Straus DJ, Duvic M, Kuzel T, et al. Results of a phase II trial of oral bexarotene (Targretin) combined with interferon alfa-2b (Intron-A) for patients with cutaneous T-cell lymphoma. Cancer 2007;109:1799–1803. Available at: https://www.ncbi.nlm.nih.gov/pubmed/17366595.

158. Siakantaris MP, Tsirigotis P, Stavroyianni N, et al. Management of cutaneous T-Cell lymphoma patients with extracorporeal photopheresis. The Hellenic experience. Transfus Apher Sci 2012;46:189–193. Available at: https://www.ncbi.nlm.nih.gov/pubmed/22178592.

159. Cheeley J, Sahn RE, DeLong LK, Parker SR. Acitretin for the treatment of cutaneous T-cell lymphoma. J Am Acad Dermatol 2013;68:247–254. Available at: https://www.ncbi.nlm.nih.gov/pubmed/22917895.

160. Amitay-Laish I, Reiter O, Prag-Naveh H, et al. Retinoic acid receptor agonist as monotherapy for early-stage mycosis fungoides: does it work? J Dermatolog Treat 2019;30:258–263. Available at: https://www.ncbi.nlm.nih.gov/pubmed/29889596.

161. Nikolaou V, Patsatsi A, Sidiropoulou P, et al. Monotherapy and combination therapy with acitretin for mycosis fungoides: results of a retrospective, multicentre study. J Eur Acad Dermatol Venereol 2020;34:2534–2540. Available at: https://www.ncbi.nlm.nih.gov/pubmed/32364303.

162. Kim YH, Prince HM, Whittaker S, et al. Response to brentuximab vedotin versus physician's choice by CD30 expression and large cell transformation status in patients with mycosis fungoides: An ALCANZA sub-analysis. Eur J Cancer 2021;148:411–421. Available at: https://www.ncbi.nlm.nih.gov/pubmed/33794441.

163. Duvic M, Tetzlaff MT, Gangar P, et al. Results of a phase II trial of brentuximab vedotin for CD30+ cutaneous T-cell lymphoma and lymphomatoid papulosis. J Clin Oncol 2015;33:3759–3765. Available at: https://www.ncbi.nlm.nih.gov/pubmed/26261247.

164. Kim YH, Tavallaee M, Sundram U, et al. Phase II investigator-initiated study of brentuximab vedotin in mycosis fungoides and Sezary

Version 2.2026 © 2026 National Comprehensive Cancer Network© (NCCN©), All rights reserved. NCCN Guidelines® and this illustration may not be reproduced in any form without the express written permission of NCCN.

PLEASE NOTE that use of this NCCN Content is governed by the End-User License Agreement, and you MAY NOT distribute this Content or use it with any artificial intelligence model or tool.
Printed by Galya Basol Kochav on 2/16/2026 9:44:21 AM. Copyright © 2026 National Comprehensive Cancer Network, Inc. All Rights Reserved.

syndrome with variable CD30 expression level: A multi-institution collaborative project. J Clin Oncol 2015;33:3750–3758. Available at: https://www.ncbi.nlm.nih.gov/pubmed/26195720.

165. Papadavid E, Kapniari E, Pappa V, et al. Multicentric EORTC retrospective study shows efficacy of brentuximab vedotin in patients who have mycosis fungoides and Sezary syndrome with variable CD30 positivity. Br J Dermatol 2021;185:1035–1044. Available at: https://www.ncbi.nlm.nih.gov/pubmed/34137025.

166. Barta SK, Liu N, DerSarkissian M, et al. Real-world treatment patterns and clinical outcomes with brentuximab vedotin or other standard therapies in patients with previously treated cutaneous T-cell lymphoma in the United States. Clin Lymphoma Myeloma Leuk 2024;24:e21–e32 e24. Available at: https://www.ncbi.nlm.nih.gov/pubmed/37919137.

167. Dummer R, Prince HM, Whittaker S, et al. Patient-reported quality of life in patients with relapsed/refractory cutaneous T-cell lymphoma: Results from the randomised phase III ALCANZA study. Eur J Cancer 2020;133:120–130. Available at: https://www.ncbi.nlm.nih.gov/pubmed/32502876.

168. Lewis DJ, Haun PL, Samimi SS, et al. Brentuximab vedotin for relapsed or refractory Sezary syndrome. JAMA Dermatol 2021;157:317–321. Available at: https://www.ncbi.nlm.nih.gov/pubmed/33377934.

169. Horwitz S, Zinzani PL, Bagot M, et al. Lack of impact of type and extent of prior therapy on outcomes of mogamulizumab therapy in patients with cutaneous T cell lymphoma in the MAVORIC trial. Leuk Lymphoma 2021;62:3109–3118. Available at: https://www.ncbi.nlm.nih.gov/pubmed/34304674.

170. Porcu P, Hudgens S, Horwitz S, et al. Quality of life effect of the anti-CCR4 monoclonal antibody mogamulizumab versus vorinostat in patients with cutaneous T-cell lymphoma. Clin Lymphoma Myeloma Leuk 2021;21:97–105. Available at: https://www.ncbi.nlm.nih.gov/pubmed/33158772.

171. Cowan RA, Scarisbrick JJ, Zinzani PL, et al. Efficacy and safety of mogamulizumab by patient baseline blood tumour burden: a post hoc analysis of the MAVORIC trial. J Eur Acad Dermatol Venereol 2021;35:2225–2238. Available at: https://www.ncbi.nlm.nih.gov/pubmed/34273208.

172. Beylot-Barry M, Booken N, Weishaupt C, et al. Impact of blood involvement on efficacy and time to response with mogamulizumab in mycosis fungoides and Sezary syndrome. J Eur Acad Dermatol Venereol 2023;37:311–316. Available at: https://www.ncbi.nlm.nih.gov/pubmed/35993803.

173. Bagot M, Dalle S, Sokol L, et al. Long-term disease control and safety with the anti-CCR4 antibody mogamulizumab: Post-hoc analyses from the MAVORIC trial of patients with previously treated cutaneous T-cell lymphoma. Dermatol Ther 2022;35:e15634. Available at: https://www.ncbi.nlm.nih.gov/pubmed/35695215.

174. Hirotsu KE, Neal TM, Khodadoust MS, et al. Clinical characterization of mogamulizumab-associated rash during treatment of mycosis fungoides or Sezary syndrome. JAMA Dermatol 2021;157:700–707. Available at: https://www.ncbi.nlm.nih.gov/pubmed/33881447.

175. Trum NA, Zain J, Martinez XU, et al. Mogamulizumab efficacy is underscored by its associated rash that mimics cutaneous T-cell lymphoma: a retrospective single-centre case series. Br J Dermatol 2022;186:153–166. Available at: https://www.ncbi.nlm.nih.gov/pubmed/34427917.

176. Wang JY, Hirotsu KE, Neal TM, et al. Histopathologic characterization of mogamulizumab-associated rash. Am J Surg Pathol 2020;44:1666–1676. Available at: https://www.ncbi.nlm.nih.gov/pubmed/32976123.

177. Wang J, de Masson A, Ram-Wolff C, et al. Granulomatous rash associated with mogamulizumab mimicking mycosis fungoides: a case series. Eur J Cancer 2021;156 Suppl 1:S49. Available at: https://www.ncbi.nlm.nih.gov/pubmed/34649659.

Version 2.2026 © 2026 National Comprehensive Cancer Network© (NCCN©), All rights reserved. NCCN Guidelines® and this illustration may not be reproduced in any form without the express written permission of NCCN.

PLEASE NOTE that use of this NCCN Content is governed by the End-User License Agreement, and you MAY NOT distribute this Content or use it with any artificial intelligence model or tool.
Printed by Galya Basol Kochav on 2/16/2026 9:44:21 AM. Copyright © 2026 National Comprehensive Cancer Network, Inc. All Rights Reserved.

178. Chen L, Carson KR, Staser KW, et al. Mogamulizumab-associated cutaneous granulomatous drug eruption mimicking mycosis fungoides but possibly indicating durable clinical response. JAMA Dermatol 2019;155:968–971. Available at:

179. Musiek ACM, Rieger KE, Bagot M, et al. Dermatologic events associated with the anti-CCR4 antibody mogamulizumab: characterization and management. Dermatol Ther (Heidelb) 2022;12:29–40. Available at: https://www.ncbi.nlm.nih.gov/pubmed/34816383.

180. Avallone G, Roccuzzo G, Pileri A, et al. Clinicopathological definition, management and prognostic value of mogamulizumab-associated rash and other cutaneous events: A systematic review. J Eur Acad Dermatol Venereol 2024;38:1738–1748. Available at: https://www.ncbi.nlm.nih.gov/pubmed/38279614.

181. Prince HM, Duvic M, Martin A, et al. Phase III placebo-controlled trial of denileukin diftitox for patients with cutaneous T-cell lymphoma. J Clin Oncol 2010;28:1870–1877. Available at: https://www.ncbi.nlm.nih.gov/pubmed/20212249.

182. Duvic M, Geskin L, Prince HM. Duration of response in cutaneous T-cell lymphoma patients treated with denileukin diftitox: results from 3 phase III studies. Clin Lymphoma Myeloma Leuk 2013;13:377–384. Available at: https://www.ncbi.nlm.nih.gov/pubmed/23770157.

183. Bisaccia E, Gonzalez J, Palangio M, et al. Extracorporeal photochemotherapy alone or with adjuvant therapy in the treatment of cutaneous T-cell lymphoma: a 9-year retrospective study at a single institution. J Am Acad Dermatol 2000;43:263–271. Available at: https://www.ncbi.nlm.nih.gov/pubmed/10906649.

184. Zic JA. The treatment of cutaneous T-cell lymphoma with photopheresis. Dermatol Ther 2003;16:337–346. Available at: https://www.ncbi.nlm.nih.gov/pubmed/14686977.

185. Arulogun S, Prince HM, Gambell P, et al. Extracorporeal photopheresis for the treatment of Sezary syndrome using a novel treatment protocol. J Am Acad Dermatol 2008;59:589–595. Available at: https://www.ncbi.nlm.nih.gov/pubmed/18656282.

186. Talpur R, Demierre MF, Geskin L, et al. Multicenter photopheresis intervention trial in early-stage mycosis fungoides. Clin Lymphoma Myeloma Leuk 2011;11:219–227. Available at: https://www.ncbi.nlm.nih.gov/pubmed/21575927.

187. Knobler R, Duvic M, Querfeld C, et al. Long-term follow-up and survival of cutaneous T-cell lymphoma patients treated with extracorporeal photopheresis. Photodermatol Photoimmunol Photomed 2012;28:250–257. Available at: https://www.ncbi.nlm.nih.gov/pubmed/22971190.

188. Knobler R, Berlin G, Calzavara-Pinton P, et al. Guidelines on the use of extracorporeal photopheresis. J Eur Acad Dermatol Venereol 2014;28 Suppl 1:1–37. Available at: https://www.ncbi.nlm.nih.gov/pubmed/24354653.

189. Atilla E, Atilla PA, Bozdag SC, et al. Extracorporeal photochemotherapy in mycosis fungoides. Transfus Clin Biol 2017;24:454–457. Available at: https://www.ncbi.nlm.nih.gov/pubmed/28578935.

190. Gao C, McCormack C, van der Weyden C, et al. Prolonged survival with the early use of a novel extracorporeal photopheresis regimen in patients with Sezary syndrome. Blood 2019;134:1346–1350. Available at: https://www.ncbi.nlm.nih.gov/pubmed/31467061.

191. Girardi M, Carlson K, Huang X, et al. Chart review study of real-world clinical outcomes in patients with cutaneous T-cell lymphoma treated with extracorporeal photopheresis in the US in 2017-2019. J Dermatolog Treat 2024;35:2360568. Available at: https://www.ncbi.nlm.nih.gov/pubmed/38852942.

192. Stevens SR, Baron ED, Masten S, Cooper KD. Circulating CD4+CD7- lymphocyte burden and rapidity of response: predictors of outcome in the treatment of Sezary syndrome and erythrodermic mycosis fungoides with extracorporeal photopheresis. Arch Dermatol

Version 2.2026 © 2026 National Comprehensive Cancer Network© (NCCN©), All rights reserved. NCCN Guidelines® and this illustration may not be reproduced in any form without the express written permission of NCCN.

PLEASE NOTE that use of this NCCN Content is governed by the End-User License Agreement, and you MAY NOT distribute this Content or use it with any artificial intelligence model or tool.
Printed by Galya Basol Kochav on 2/16/2026 9:44:21 AM. Copyright © 2026 National Comprehensive Cancer Network, Inc. All Rights Reserved.

2002;138:1347–1350. Available at: https://www.ncbi.nlm.nih.gov/pubmed/12374541.

193. Stadler R, Otte HG, Luger T, et al. Prospective randomized multicenter clinical trial on the use of interferon -2a plus acitretin versus interferon -2a plus PUVA in patients with cutaneous T-cell lymphoma stages I and II. Blood 1998;92:3578–3581. Available at: http://www.ncbi.nlm.nih.gov/pubmed/9808550.

194. Chiarion-Sileni V, Bononi A, Fornasa CV, et al. Phase II trial of interferon-alpha-2a plus psolaren with ultraviolet light A in patients with cutaneous T-cell lymphoma. Cancer 2002;95:569–575. Available at: https://www.ncbi.nlm.nih.gov/pubmed/12209749.

195. Rupoli S, Goteri G, Pulini S, et al. Long-term experience with low-dose interferon-alpha and PUVA in the management of early mycosis fungoides. Eur J Haematol 2005;75:136–145. Available at: https://www.ncbi.nlm.nih.gov/pubmed/16000130.

196. Olisova OY, Megna M, Grekova EV, et al. PUVA and interferon alpha2b combined therapy for patients with mycosis fungoides at different stages of the disease: a seven-year retrospective study in Russia. J Eur Acad Dermatol Venereol 2019;33:e72–e74. Available at: https://www.ncbi.nlm.nih.gov/pubmed/30102807.

197. Rupoli S, Canafoglia L, Goteri G, et al. Results of a prospective phase II trial with oral low-dose bexarotene plus photochemotherapy (PUVA) in refractory and/or relapsed patients with mycosis fungoides. Eur J Dermatol 2016;26:13–20. Available at: https://www.ncbi.nlm.nih.gov/pubmed/26678311.

198. Fujimura T, Sato Y, Tanita K, et al. Case series of cutaneous T-cell lymphomas treated with bexarotene-based therapy. J Dermatol 2020;47:636–640. Available at: https://www.ncbi.nlm.nih.gov/pubmed/32207181.

199. Morita A, Tateishi C, Muramatsu S, et al. Efficacy and safety of bexarotene combined with photo(chemo)therapy for cutaneous T-cell lymphoma. J Dermatol 2020;47:443–451. Available at: https://www.ncbi.nlm.nih.gov/pubmed/32189402.

200. Wilson LD, Jones GW, Kim D, et al. Experience with total skin electron beam therapy in combination with extracorporeal photopheresis in the management of patients with erythrodermic (T4) mycosis fungoides. J Am Acad Dermatol 2000;43:54–60. Available at: https://www.ncbi.nlm.nih.gov/pubmed/10863224.

201. Atzmony L, Amitay-Laish I, Gurion R, et al. Erythrodermic mycosis fungoides and Sezary syndrome treated with extracorporeal photopheresis as part of a multimodality regimen: A single-centre experience. J Eur Acad Dermatol Venereol 2015;29:2382–2389. Available at: https://www.ncbi.nlm.nih.gov/pubmed/26299651.

202. Akilov OE, Grant C, Frye R, et al. Low-dose electron beam radiation and romidepsin therapy for symptomatic cutaneous T-cell lymphoma lesions. Br J Dermatol 2012;167:194–197. Available at: https://www.ncbi.nlm.nih.gov/pubmed/22372971.

203. Jothishankar B, Almazan T, Kim Y, et al. Romidepsin and total skin electron beam therapy in advanced stage mycosis fungoides and Sezary syndrome. Br J Haematol 2019;186:377–379. Available at: https://www.ncbi.nlm.nih.gov/pubmed/30937886.

204. Durgin JS, Jariwala NN, Wysocka M, et al. Low-Dose Total Skin Electron Beam Therapy as Part of a Multimodality Regimen for Treatment of Sezary Syndrome: Clinical, Immunologic, and Molecular Analysis. JAMA Dermatol 2021;157:90–95. Available at: https://www.ncbi.nlm.nih.gov/pubmed/33112366.

205. Fong S, Hong EK, Khodadoust MS, et al. Low-dose total skin electron beam therapy combined with mogamulizumab for refractory Mycosis Fungoides and Sezary Syndrome. Adv Radiat Oncol 2021;6:100629. Available at: https://www.ncbi.nlm.nih.gov/pubmed/33748543.

206. Wu SY, Fang PQ, Wang EB, et al. Safety of concurrent radiation therapy with brentuximab vedotin in the treatment of lymphoma. Adv

Version 2.2026 © 2026 National Comprehensive Cancer Network© (NCCN©), All rights reserved. NCCN Guidelines® and this illustration may not be reproduced in any form without the express written permission of NCCN.

PLEASE NOTE that use of this NCCN Content is governed by the End-User License Agreement, and you MAY NOT distribute this Content or use it with any artificial intelligence model or tool.
Printed by Galya Basol Kochav on 2/16/2026 9:44:21 AM. Copyright © 2026 National Comprehensive Cancer Network, Inc. All Rights Reserved.

Radiat Oncol 2023;8:101279. Available at: https://www.ncbi.nlm.nih.gov/pubmed/37448588.

207. Wollina U, Looks A, Meyer J, et al. Treatment of stage II cutaneous T-cell lymphoma with interferon alfa-2a and extracorporeal photochemotherapy: a prospective controlled trial. J Am Acad Dermatol 2001;44:253–260. Available at: https://www.ncbi.nlm.nih.gov/pubmed/11174383.

208. Suchin KR, Cucchiara AJ, Gottleib SL, et al. Treatment of cutaneous T-cell lymphoma with combined immunomodulatory therapy: a 14-year experience at a single institution. Arch Dermatol 2002;138:1054–1060. Available at: https://www.ncbi.nlm.nih.gov/pubmed/12164743.

209. Raphael BA, Shin DB, Suchin KR, et al. High clinical response rate of Sezary syndrome to immunomodulatory therapies: prognostic markers of response. Arch Dermatol 2011;147:1410–1415. Available at: https://www.ncbi.nlm.nih.gov/pubmed/21844430.

210. Straus DJ, Duvic M, Horwitz SM, et al. Final results of phase II trial of doxorubicin HCl liposome injection followed by bexarotene in advanced cutaneous T-cell lymphoma. Ann Oncol 2014;25:206–210. Available at: https://www.ncbi.nlm.nih.gov/pubmed/24285015.

211. Ninosu N, Melchers S, Kappenstein M, et al. Mogamulizumab combined with extracorporeal photopheresis as a novel therapy in erythrodermic cutaneous T-cell lymphoma. Cancers (Basel) 2023;16. Available at: https://www.ncbi.nlm.nih.gov/pubmed/38201568.

212. Campbell BA, Dobos G, Haider Z, et al. International study of treatment efficacy in SS shows superiority of combination therapy and heterogeneity of treatment strategies. Blood Adv 2023;7:6639–6647. Available at: https://www.ncbi.nlm.nih.gov/pubmed/37648672.

213. Olsen EA, Whittaker S, Kim YH, et al. Clinical end points and response criteria in mycosis fungoides and Sezary syndrome: a consensus statement of the International Society for Cutaneous Lymphomas, the United States Cutaneous Lymphoma Consortium, and the Cutaneous Lymphoma Task Force of the European Organisation for Research and Treatment of Cancer. J Clin Oncol 2011;29:2598–2607. Available at: https://www.ncbi.nlm.nih.gov/pubmed/21576639.

214. van Doorn R, Scheffer E, Willemze R. Follicular mycosis fungoides, a distinct disease entity with or without associated follicular mucinosis: a clinicopathologic and follow-up study of 51 patients. Arch Dermatol 2002;138:191–198. Available at: https://www.ncbi.nlm.nih.gov/pubmed/11843638.

215. Gerami P, Rosen S, Kuzel T, et al. Folliculotropic mycosis fungoides: an aggressive variant of cutaneous T-cell lymphoma. Arch Dermatol 2008;144:738–746. Available at: https://www.ncbi.nlm.nih.gov/pubmed/18559762.

216. Lehman JS, Cook-Norris RH, Weed BR, et al. Folliculotropic mycosis fungoides: single-center study and systematic review. Arch Dermatol 2010;146:607–613. Available at: https://www.ncbi.nlm.nih.gov/pubmed/20566923.

217. Wieser I, Wang C, Alberti-Violetti S, et al. Clinical characteristics, risk factors and long-term outcome of 114 patients with folliculotropic mycosis fungoides. Arch Dermatol Res 2017;309:453–459. Available at: https://www.ncbi.nlm.nih.gov/pubmed/28516243.

218. Hodak E, Amitay-Laish I, Atzmony L, et al. New insights into folliculotropic mycosis fungoides (FMF): A single-center experience. J Am Acad Dermatol 2016;75:347–355. Available at: https://www.ncbi.nlm.nih.gov/pubmed/27245278.

219. van Santen S, Roach RE, van Doorn R, et al. Clinical staging and prognostic factors in folliculotropic mycosis fungoides. JAMA Dermatol 2016;152:992–1000. Available at: https://www.ncbi.nlm.nih.gov/pubmed/27276223.

220. Charli-Joseph Y, Kashani-Sabet M, McCalmont TH, et al. Association of a proposed new staging system for folliculotropic mycosis fungoides with prognostic variables in a US cohort. JAMA Dermatol 2021;157:157–165. Available at: https://www.ncbi.nlm.nih.gov/pubmed/33295938.

Version 2.2026 © 2026 National Comprehensive Cancer Network© (NCCN©), All rights reserved. NCCN Guidelines® and this illustration may not be reproduced in any form without the express written permission of NCCN.

PLEASE NOTE that use of this NCCN Content is governed by the End-User License Agreement, and you MAY NOT distribute this Content or use it with any artificial intelligence model or tool.
Printed by Galya Basol Kochav on 2/16/2026 9:44:21 AM. Copyright © 2026 National Comprehensive Cancer Network, Inc. All Rights Reserved.

221. van Santen S, van Doorn R, Neelis KJ, et al. Recommendations for treatment in folliculotropic mycosis fungoides: report of the Dutch Cutaneous Lymphoma Group. Br J Dermatol 2017;177:223–228. Available at: https://www.ncbi.nlm.nih.gov/pubmed/28132406.

222. Lansigan F, Horwitz SM, Pinter-Brown LC, et al. Outcomes of patients with transformed mycosis fungoides: Analysis from a prospective multicenter US cohort study. Clin Lymphoma Myeloma Leuk 2020;20:744–748. Available at: https://www.ncbi.nlm.nih.gov/pubmed/32532611.

223. de Masson A, Beylot-Barry M, Bouaziz JD, et al. Allogeneic stem cell transplantation for advanced cutaneous T-cell lymphomas: a study from the French Society of Bone Marrow Transplantation and French Study Group on Cutaneous Lymphomas. Haematologica 2014;99:527–534. Available at: https://www.ncbi.nlm.nih.gov/pubmed/24213148.

224. Duarte RF, Boumendil A, Onida F, et al. Long-term outcome of allogeneic hematopoietic cell transplantation for patients with mycosis fungoides and Sezary syndrome: a European society for blood and marrow transplantation lymphoma working party extended analysis. J Clin Oncol 2014;32:3347–3348. Available at: https://www.ncbi.nlm.nih.gov/pubmed/25154828.

225. Lechowicz MJ, Lazarus HM, Carreras J, et al. Allogeneic hematopoietic cell transplantation for mycosis fungoides and Sezary syndrome. Bone Marrow Transplant 2014;49:1360–1365. Available at: https://www.ncbi.nlm.nih.gov/pubmed/25068422.

226. Hosing C, Bassett R, Dabaja B, et al. Allogeneic stem-cell transplantation in patients with cutaneous lymphoma: updated results from a single institution. Ann Oncol 2015;26:2490–2495. Available at: https://www.ncbi.nlm.nih.gov/pubmed/26416896.

227. Shiratori S, Fujimoto K, Nishimura M, et al. Allogeneic hematopoietic stem cell transplantation following reduced-intensity conditioning for mycosis fungoides and Sezary syndrome. Hematol Oncol 2016;34:9–16. Available at: https://www.ncbi.nlm.nih.gov/pubmed/25312300.

228. Domingo-Domenech E, Duarte RF, Boumedil A, et al. Allogeneic hematopoietic stem cell transplantation for advanced mycosis fungoides and Sezary syndrome. An updated experience of the Lymphoma Working Party of the European Society for Blood and Marrow Transplantation. Bone Marrow Transplant 2021;56:1391–1401. Available at: https://www.ncbi.nlm.nih.gov/pubmed/33420392.

229. Cengiz Seval G, Sahin U, Bozdag SC, et al. Allogeneic hematopoietic stem cell transplantation for heavily pretreated patients with mycosis fungoides and Sezary syndrome. Dermatol Ther 2022;35:e15447. Available at: https://www.ncbi.nlm.nih.gov/pubmed/35289037.

230. Elliott J, Ahlawat S, Prince HM, et al. Long-term outcomes for allogeneic bone marrow transplantation in Sezary syndrome and mycosis fungoides. Bone Marrow Transplant 2022;57:1724–1726. Available at: https://www.ncbi.nlm.nih.gov/pubmed/36028756.

231. Johnson WT, Mukherji R, Kartan S, et al. Allogeneic hematopoietic stem cell transplantation in advanced stage mycosis fungoides and Sezary syndrome: a concise review. Chin Clin Oncol 2019;8:12. Available at: https://www.ncbi.nlm.nih.gov/pubmed/30525754.

232. Iqbal M, Reljic T, Ayala E, et al. Efficacy of allogeneic hematopoietic cell transplantation in cutaneous T cell lymphoma: Results of a systematic review and meta-analysis. Biol Blood Marrow Transplant 2020;26:76–82. Available at: https://www.ncbi.nlm.nih.gov/pubmed/31494227.

233. de Masson A, Beylot-Barry M, Ram-Wolff C, et al. Allogeneic transplantation in advanced cutaneous T-cell lymphomas (CUTALLO): a propensity score matched controlled prospective study. Lancet 2023;401:1941–1950. Available at: https://www.ncbi.nlm.nih.gov/pubmed/37105210.

234. Duvic M, Donato M, Dabaja B, et al. Total skin electron beam and non-myeloablative allogeneic hematopoietic stem-cell transplantation in advanced mycosis fungoides and Sezary syndrome. J Clin Oncol 2010;28:2365–2372. Available at: https://www.ncbi.nlm.nih.gov/pubmed/20351328.

Version 2.2026 © 2026 National Comprehensive Cancer Network© (NCCN©), All rights reserved. NCCN Guidelines® and this illustration may not be reproduced in any form without the express written permission of NCCN.

PLEASE NOTE that use of this NCCN Content is governed by the End-User License Agreement, and you MAY NOT distribute this Content or use it with any artificial intelligence model or tool.
Printed by Galya Basol Kochav on 2/16/2026 9:44:21 AM. Copyright © 2026 National Comprehensive Cancer Network, Inc. All Rights Reserved.

235. Isufi I, Seropian S, Gowda L, et al. Outcomes for allogeneic stem cell transplantation in refractory mycosis fungoides and primary cutaneous gamma Delta T cell lymphomas. Leuk Lymphoma 2020;61:2955–2961. Available at: https://www.ncbi.nlm.nih.gov/pubmed/32643494.

236. Thompson LL, Pan CX, Chang MS, et al. Alemtuzumab, total skin electron beam, and non-myeloablative allogeneic haematopoietic stem-cell transplantation in advanced sezary syndrome: a retrospective cohort study. J Eur Acad Dermatol Venereol 2021;35:e373–e375. Available at: https://www.ncbi.nlm.nih.gov/pubmed/33545747.

237. Weng WK, Arai S, Rezvani A, et al. Nonmyeloablative allogeneic transplantation achieves clinical and molecular remission in cutaneous T-cell lymphoma. Blood Adv 2020;4:4474–4482. Available at: https://www.ncbi.nlm.nih.gov/pubmed/32941647.

238. Morris SL, Thomas BR, Palanicawandar R, et al. Long term outcomes of nonmyeloablative allogeneic stem cell transplantation with TSEB TLI and ATG for Mycosis Fungoides and Sezary Syndrome. Bone Marrow Transplant 2024;59:874–879. Available at: https://www.ncbi.nlm.nih.gov/pubmed/38472408.

239. Goyal A, O'Leary D, Dabaja B, et al. ASTCT and USCLC clinical practice recommendations for allogeneic stem cell transplant in Mycosis Fungoides and Sezary Syndrome. Transplant Cell Ther 2024;30:1047–1060. Available at: https://www.ncbi.nlm.nih.gov/pubmed/39222792.

240. Mori T, Shiratori S, Suzumiya J, et al. Outcome of allogeneic hematopoietic stem cell transplantation for mycosis fungoides and Sezary syndrome. Hematol Oncol 2020;38:266–271. Available at: https://www.ncbi.nlm.nih.gov/pubmed/32011008.

241. Duarte RF, Schmitz N, Servitje O, Sureda A. Haematopoietic stem cell transplantation for patients with primary cutaneous T-cell lymphoma. Bone Marrow Transplant 2008;41:597–604. Available at: https://www.ncbi.nlm.nih.gov/pubmed/18176611.

242. Demierre MF, Gan S, Jones J, Miller DR. Significant impact of cutaneous T-cell lymphoma on patients' quality of life: results of a 2005 National Cutaneous Lymphoma Foundation Survey. Cancer 2006;107:2504–2511. Available at: https://www.ncbi.nlm.nih.gov/pubmed/17048251.

243. Sampogna F, Frontani M, Baliva G, et al. Quality of life and psychological distress in patients with cutaneous lymphoma. Br J Dermatol 2009;160:815–822. Available at: https://www.ncbi.nlm.nih.gov/pubmed/19120325.

244. Meyer N, Paul C, Misery L. Pruritus in cutaneous T-cell lymphomas: frequent, often severe and difficult to treat. Acta Derm Venereol 2010;90:12–17. Available at: https://www.ncbi.nlm.nih.gov/pubmed/20107719.

245. Trautinger F, Knobler R, Willemze R, et al. EORTC consensus recommendations for the treatment of mycosis fungoides/Sezary syndrome. Eur J Cancer 2006;42:1014–1030. Available at: https://www.ncbi.nlm.nih.gov/pubmed/16574401.

246. Eschler DC, Klein PA. An evidence-based review of the efficacy of topical antihistamines in the relief of pruritus. J Drugs Dermatol 2010;9:992–997. Available at: https://www.ncbi.nlm.nih.gov/pubmed/20684150.

247. Matsuda KM, Sharma D, Schonfeld AR, Kwatra SG. Gabapentin and pregabalin for the treatment of chronic pruritus. J Am Acad Dermatol 2016;75:619–625.e616. Available at: https://www.ncbi.nlm.nih.gov/pubmed/27206757.

248. Duval A, Dubertret L. Aprepitant as an antipruritic agent? N Engl J Med 2009;361:1415–1416. Available at: https://www.ncbi.nlm.nih.gov/pubmed/19797294.

249. Booken N, Heck M, Nicolay JP, et al. Oral aprepitant in the therapy of refractory pruritus in erythrodermic cutaneous T-cell lymphoma. Br J Dermatol 2011;164:665–667. Available at: https://www.ncbi.nlm.nih.gov/pubmed/21039410.

Version 2.2026 © 2026 National Comprehensive Cancer Network© (NCCN©), All rights reserved. NCCN Guidelines® and this illustration may not be reproduced in any form without the express written permission of NCCN.

PLEASE NOTE that use of this NCCN Content is governed by the End-User License Agreement, and you MAY NOT distribute this Content or use it with any artificial intelligence model or tool.
Printed by Galya Basol Kochav on 2/16/2026 9:44:21 AM. Copyright © 2026 National Comprehensive Cancer Network, Inc. All Rights Reserved.

250. Jimenez Gallo D, Albarran Planelles C, Linares Barrios M, et al. Treatment of pruritus in early-stage hypopigmented mycosis fungoides with aprepitant. Dermatol Ther 2014;27:178–182. Available at: https://www.ncbi.nlm.nih.gov/pubmed/24517320.

251. Demierre MF, Taverna J. Mirtazapine and gabapentin for reducing pruritus in cutaneous T-cell lymphoma. J Am Acad Dermatol 2006;55:543–544. Available at: https://www.ncbi.nlm.nih.gov/pubmed/16908377.

252. Stander S, Bockenholt B, Schurmeyer-Horst F, et al. Treatment of chronic pruritus with the selective serotonin re-uptake inhibitors paroxetine and fluvoxamine: results of an open-labelled, two-arm proof-of-concept study. Acta Derm Venereol 2009;89:45–51. Available at: https://www.ncbi.nlm.nih.gov/pubmed/19197541.

253. Bigliardi PL, Stammer H, Jost G, et al. Treatment of pruritus with topically applied opiate receptor antagonist. J Am Acad Dermatol 2007;56:979–988. Available at: https://www.ncbi.nlm.nih.gov/pubmed/17320241.

254. Axelrod PI, Lorber B, Vonderheid EC. Infections complicating mycosis fungoides and Sezary syndrome. JAMA 1992;267:1354–1358. Available at: https://www.ncbi.nlm.nih.gov/pubmed/1740857.

255. Lindahl LM, Willerslev-Olsen A, Gjerdrum LMR, et al. Antibiotics inhibit tumor and disease activity in cutaneous T-cell lymphoma. Blood 2019;134:1072–1083. Available at: https://www.ncbi.nlm.nih.gov/pubmed/31331920.

256. Kim YH, Willemze R, Pimpinelli N, et al. TNM classification system for primary cutaneous lymphomas other than mycosis fungoides and Sezary syndrome: a proposal of the International Society for Cutaneous Lymphomas (ISCL) and the Cutaneous Lymphoma Task Force of the European Organization of Research and Treatment of Cancer (EORTC). Blood 2007;110:479–484. Available at: https://www.ncbi.nlm.nih.gov/pubmed/17339420.

257. Kempf W, Pfaltz K, Vermeer MH, et al. EORTC, ISCL, and USCLC consensus recommendations for the treatment of primary cutaneous CD30-positive lymphoproliferative disorders: lymphomatoid papulosis and primary cutaneous anaplastic large-cell lymphoma. Blood 2011;118:4024–4035. Available at: https://www.ncbi.nlm.nih.gov/pubmed/21841159.

258. Paulli M, Berti E, Rosso R, et al. CD30/Ki-1-positive lymphoproliferative disorders of the skin--clinicopathologic correlation and statistical analysis of 86 cases: a multicentric study from the European Organization for Research and Treatment of Cancer Cutaneous Lymphoma Project Group. J Clin Oncol 1995;13:1343–1354. Available at: https://www.ncbi.nlm.nih.gov/pubmed/7751878.

259. Vergier B, Beylot-Barry M, Pulford K, et al. Statistical evaluation of diagnostic and prognostic features of CD30+ cutaneous lymphoproliferative disorders: a clinicopathologic study of 65 cases. Am J Surg Pathol 1998;22:1192–1202. Available at: https://www.ncbi.nlm.nih.gov/pubmed/9777981.

260. Beljaards RC, Kaudewitz P, Berti E, et al. Primary cutaneous CD30-positive large cell lymphoma: definition of a new type of cutaneous lymphoma with a favorable prognosis. A European Multicenter Study of 47 patients. Cancer 1993;71:2097–2104. Available at: https://www.ncbi.nlm.nih.gov/pubmed/8382999.

261. Bekkenk MW, Geelen FA, van Voorst Vader PC, et al. Primary and secondary cutaneous CD30(+) lymphoproliferative disorders: a report from the Dutch Cutaneous Lymphoma Group on the long-term follow-up data of 219 patients and guidelines for diagnosis and treatment. Blood 2000;95:3653–3661. Available at: https://www.ncbi.nlm.nih.gov/pubmed/10845893.

262. Liu HL, Hoppe RT, Kohler S, et al. CD30+ cutaneous lymphoproliferative disorders: the Stanford experience in lymphomatoid papulosis and primary cutaneous anaplastic large cell lymphoma. J Am Acad Dermatol 2003;49:1049–1058. Available at: https://www.ncbi.nlm.nih.gov/pubmed/14639383.

263. Sarfraz H, Gentille C, Ensor J, et al. Primary cutaneous anaplastic large-cell lymphoma: a review of the SEER database from 2005 to 2016.

Version 2.2026 © 2026 National Comprehensive Cancer Network© (NCCN©), All rights reserved. NCCN Guidelines® and this illustration may not be reproduced in any form without the express written permission of NCCN.

PLEASE NOTE that use of this NCCN Content is governed by the End-User License Agreement, and you MAY NOT distribute this Content or use it with any artificial intelligence model or tool.
Printed by Galya Basol Kochav on 2/16/2026 9:44:21 AM. Copyright © 2026 National Comprehensive Cancer Network, Inc. All Rights Reserved.

Clin Exp Dermatol 2021;46:1420–1426. Available at: https://www.ncbi.nlm.nih.gov/pubmed/34081802.

264. Woo DK, Jones CR, Vanoli-Storz MN, et al. Prognostic factors in primary cutaneous anaplastic large cell lymphoma: characterization of clinical subset with worse outcome. Arch Dermatol 2009;145:667–674. Available at: https://www.ncbi.nlm.nih.gov/pubmed/19528422.

265. Benner MF, Willemze R. Applicability and prognostic value of the new TNM classification system in 135 patients with primary cutaneous anaplastic large cell lymphoma. Arch Dermatol 2009;145:1399–1404. Available at: https://www.ncbi.nlm.nih.gov/pubmed/20026848.

266. Fernandez-de-Misa R, Hernandez-Machin B, Combalia A, et al. Prognostic factors in patients with primary cutaneous anaplastic large cell lymphoma: a multicentric, retrospective analysis of the Spanish Group of Cutaneous Lymphoma. J Eur Acad Dermatol Venereol 2020;34:762–768. Available at: https://www.ncbi.nlm.nih.gov/pubmed/31591786.

267. Wang HH, Myers T, Lach LJ, et al. Increased risk of lymphoid and nonlymphoid malignancies in patients with lymphomatoid papulosis. Cancer 1999;86:1240–1245. Available at: https://www.ncbi.nlm.nih.gov/pubmed/10506709.

268. de Souza A, el-Azhary RA, Camilleri MJ, et al. In search of prognostic indicators for lymphomatoid papulosis: a retrospective study of 123 patients. J Am Acad Dermatol 2012;66:928–937. Available at: https://www.ncbi.nlm.nih.gov/pubmed/21982062.

269. Nikolaou V, Papadavid E, Ekonomidi A, et al. Association of clinicopathological characteristics with secondary neoplastic lymphoproliferative disorders in patients with lymphomatoid papulosis. Leuk Lymphoma 2015;56:1303–1307. Available at: https://www.ncbi.nlm.nih.gov/pubmed/25242096.

270. Cordel N, Tressieres B, D'Incan M, et al. Frequency and risk factors for associated lymphomas in patients with lymphomatoid papulosis. Oncologist 2016;21:76–83. Available at: https://www.ncbi.nlm.nih.gov/pubmed/26668250.

271. Wieser I, Oh CW, Talpur R, Duvic M. Lymphomatoid papulosis: Treatment response and associated lymphomas in a study of 180 patients. J Am Acad Dermatol 2016;74:59–67. Available at: https://www.ncbi.nlm.nih.gov/pubmed/26518172.

272. AbuHilal M, Walsh S, Shear N. Associated hematolymphoid malignancies in patients with lymphomatoid papulosis: A Canadian retrospective study. J Cutan Med Surg 2017;21:507–512. Available at: https://www.ncbi.nlm.nih.gov/pubmed/28614957.

273. Eberle FC, Song JY, Xi L, et al. Nodal involvement by cutaneous CD30-positive T-cell lymphoma mimicking classical Hodgkin lymphoma. Am J Surg Pathol 2012;36:716–725. Available at: https://www.ncbi.nlm.nih.gov/pubmed/22367293.

274. DeCoteau JF, Butmarc JR, Kinney MC, Kadin ME. The t(2;5) chromosomal translocation is not a common feature of primary cutaneous CD30+ lymphoproliferative disorders: comparison with anaplastic large-cell lymphoma of nodal origin. Blood 1996;87:3437–3441. Available at: https://www.ncbi.nlm.nih.gov/pubmed/8605362.

275. Melchers RC, Willemze R, van de Loo M, et al. Clinical, histologic, and molecular characteristics of anaplastic lymphoma kinase-positive primary cutaneous anaplastic large cell lymphoma. Am J Surg Pathol 2020;44:776–781. Available at: https://www.ncbi.nlm.nih.gov/pubmed/32412717.

276. Collins K, Gu J, Aung PP, et al. Is immunohistochemical expression of GATA3 helpful in the differential diagnosis of transformed mycosis fungoides and primary cutaneous CD30-positive T cell lymphoproliferative disorders? Virchows Arch 2021;479:377–383. Available at: https://www.ncbi.nlm.nih.gov/pubmed/33604757.

277. Kempf W, Kutzner H, Cozzio A, et al. MUM1 expression in cutaneous CD30+ lymphoproliferative disorders: a valuable tool for the distinction between lymphomatoid papulosis and primary cutaneous anaplastic large-cell lymphoma. Br J Dermatol 2008;158:1280–1287. Available at: https://www.ncbi.nlm.nih.gov/pubmed/18410414.

Version 2.2026 © 2026 National Comprehensive Cancer Network© (NCCN©), All rights reserved. NCCN Guidelines® and this illustration may not be reproduced in any form without the express written permission of NCCN.

PLEASE NOTE that use of this NCCN Content is governed by the End-User License Agreement, and you MAY NOT distribute this Content or use it with any artificial intelligence model or tool.
Printed by Galya Basol Kochav on 2/16/2026 9:44:21 AM. Copyright © 2026 National Comprehensive Cancer Network, Inc. All Rights Reserved.

278. Fauconneau A, Pham-Ledard A, Cappellen D, et al. Assessment of diagnostic criteria between primary cutaneous anaplastic large-cell lymphoma and CD30-rich transformed mycosis fungoides; a study of 66 cases. Br J Dermatol 2015;172:1547–1554. Available at: https://www.ncbi.nlm.nih.gov/pubmed/25645336.

279. Wada DA, Law ME, Hsi ED, et al. Specificity of IRF4 translocations for primary cutaneous anaplastic large cell lymphoma: a multicenter study of 204 skin biopsies. Mod Pathol 2011;24:596–605. Available at: https://www.ncbi.nlm.nih.gov/pubmed/21169992.

280. Karai LJ, Kadin ME, Hsi ED, et al. Chromosomal rearrangements of 6p25.3 define a new subtype of lymphomatoid papulosis. Am J Surg Pathol 2013;37:1173–1181. Available at: https://www.ncbi.nlm.nih.gov/pubmed/23648461.

281. Onaindia A, Montes-Moreno S, Rodriguez-Pinilla SM, et al. Primary cutaneous anaplastic large cell lymphomas with 6p25.3 rearrangement exhibit particular histological features. Histopathology 2015;66:846–855. Available at: https://www.ncbi.nlm.nih.gov/pubmed/25131361.

282. Benner MF, Willemze R. Bone marrow examination has limited value in the staging of patients with an anaplastic large cell lymphoma first presenting in the skin. Retrospective analysis of 107 patients. Br J Dermatol 2008;159:1148–1151. Available at: https://www.ncbi.nlm.nih.gov/pubmed/18782320.

283. Million L, Yi EJ, Wu F, et al. Radiation therapy for primary cutaneous anaplastic large cell lymphoma: An International Lymphoma Radiation Oncology Group multi-institutional experience. Int J Radiat Oncol Biol Phys 2016;95:1454–1459. Available at: https://www.ncbi.nlm.nih.gov/pubmed/27315663.

284. Melchers RC, Willemze R, Daniels LA, et al. Recommendations for the optimal radiation dose in patients with primary cutaneous anaplastic large cell lymphoma: a report of the Dutch Cutaneous Lymphoma Group. Int J Radiat Oncol Biol Phys 2017;99:1279–1285. Available at: https://www.ncbi.nlm.nih.gov/pubmed/28958772.

285. Smith GL, Duvic M, Yehia ZA, et al. Effectiveness of low-dose radiation for primary cutaneous anaplastic large cell lymphoma. Adv Radiat Oncol 2017;2:363–369. Available at: https://www.ncbi.nlm.nih.gov/pubmed/29114604.

286. Piccinno R, Damiani G, Rossi LC, Berti E. Radiotherapy of primary cutaneous anaplastic large cell lymphoma: our experience in 30 cases. Int J Dermatol 2020;59:469–473. Available at: https://www.ncbi.nlm.nih.gov/pubmed/31916593.

287. Yu JB, McNiff JM, Lund MW, Wilson LD. Treatment of primary cutaneous CD30+ anaplastic large-cell lymphoma with radiation therapy. Int J Radiat Oncol Biol Phys 2008;70:1542–1545. Available at: https://www.ncbi.nlm.nih.gov/pubmed/18037577.

288. Booken N, Goerdt S, Klemke CD. Clinical spectrum of primary cutaneous CD30-positive anaplastic large cell lymphoma: an analysis of the Mannheim Cutaneous Lymphoma Registry. J Dtsch Dermatol Ges 2012;10:331–339. Available at: https://www.ncbi.nlm.nih.gov/pubmed/22525148.

289. Huang BS, Chen WY, Wang CW, et al. Relapse pattern and treatment outcome of curative radiotherapy for primary cutaneous CD30+ anaplastic large-cell lymphoma: A retrospective cohort study. Acta Derm Venereol 2016;96:394–395. Available at: https://www.ncbi.nlm.nih.gov/pubmed/26463467.

290. Hapgood G, Pickles T, Sehn LH, et al. Outcome of primary cutaneous anaplastic large cell lymphoma: a 20-year British Columbia Cancer Agency experience. Br J Haematol 2017;176:234–240. Available at: https://www.ncbi.nlm.nih.gov/pubmed/27766622.

291. Melchers RC, Willemze R, Bekkenk MW, et al. Evaluation of treatment results in multifocal primary cutaneous anaplastic large cell lymphoma: report of the Dutch Cutaneous Lymphoma Group. Br J Dermatol 2018;179:724–731. Available at: https://www.ncbi.nlm.nih.gov/pubmed/29494757.

Version 2.2026 © 2026 National Comprehensive Cancer Network© (NCCN©), All rights reserved. NCCN Guidelines® and this illustration may not be reproduced in any form without the express written permission of NCCN.

PLEASE NOTE that use of this NCCN Content is governed by the End-User License Agreement, and you MAY NOT distribute this Content or use it with any artificial intelligence model or tool.
Printed by Galya Basol Kochav on 2/16/2026 9:44:21 AM. Copyright © 2026 National Comprehensive Cancer Network, Inc. All Rights Reserved.

292. Horwitz S, O'Connor OA, Pro B, et al. Brentuximab vedotin with chemotherapy for CD30-positive peripheral T-cell lymphoma (ECHELON-2): a global, double-blind, randomised, phase 3 trial. Lancet 2019;393:229–240. Available at: https://www.ncbi.nlm.nih.gov/pubmed/30522922.

293. Bruijn MS, Horvath B, van Voorst Vader PC, et al. Recommendations for treatment of lymphomatoid papulosis with methotrexate: a report from the Dutch Cutaneous Lymphoma Group. Br J Dermatol 2015;173:1319–1322. Available at: https://www.ncbi.nlm.nih.gov/pubmed/25998985.

294. Park JB, Yang MH, Kwon DI, et al. Low-dose methotrexate treatment for solitary or localized primary cutaneous anaplastic large cell lymphoma: A long-term follow-up study. Acta Derm Venereol 2020;100:adv00069. Available at: https://www.ncbi.nlm.nih.gov/pubmed/31996929.

295. Wyss M, Dummer R, Dommann SN, et al. Lymphomatoid papulosis--treatment with recombinant interferon alfa-2a and etretinate. Dermatology 1995;190:288–291. Available at: https://www.ncbi.nlm.nih.gov/pubmed/7655107.

296. Krathen RA, Ward S, Duvic M. Bexarotene is a new treatment option for lymphomatoid papulosis. Dermatology 2003;206:142–147. Available at: https://www.ncbi.nlm.nih.gov/pubmed/12592082.

297. Sheehy O, Catherwood M, Pettengell R, Morris TC. Sustained response of primary cutaneous CD30 positive anaplastic large cell lymphoma to bexarotene and photopheresis. Leuk Lymphoma 2009;50:1389–1391. Available at: https://www.ncbi.nlm.nih.gov/pubmed/19544141.

298. Fujimura T, Furudate S, Tanita K, et al. Successful control of phototherapy-resistant lymphomatoid papulosis with oral bexarotene. J Dermatol 2018;45:e37–e38. Available at: https://www.ncbi.nlm.nih.gov/pubmed/28971510.

299. Proctor SJ, Jackson GH, Lennard AL, Marks J. Lymphomatoid papulosis: response to treatment with recombinant interferon alfa-2b. J Clin Oncol 1992;10:170. Available at: https://www.ncbi.nlm.nih.gov/pubmed/1727920.

300. Yagi H, Tokura Y, Furukawa F, Takigawa M. Th2 cytokine mRNA expression in primary cutaneous CD30-positive lymphoproliferative disorders: successful treatment with recombinant interferon-gamma. J Invest Dermatol 1996;107:827–832. Available at: https://www.ncbi.nlm.nih.gov/pubmed/8941669.

301. Schmuth M, Topar G, Illersperger B, et al. Therapeutic use of interferon-alpha for lymphomatoid papulosis. Cancer 2000;89:1603–1610. Available at: https://www.ncbi.nlm.nih.gov/pubmed/11013377.

302. Brice P, Cazals D, Mounier N, et al. Primary cutaneous large-cell lymphoma: analysis of 49 patients included in the LNH87 prospective trial of polychemotherapy for high-grade lymphomas. Groupe d'Etude des Lymphomes de l'Adulte. Leukemia 1998;12:213–219. Available at: https://www.ncbi.nlm.nih.gov/pubmed/9519784.

303. Fernandez-de-Misa R, Hernandez-Machin B, Servitje O, et al. First-line treatment in lymphomatoid papulosis: a retrospective multicentre study. Clin Exp Dermatol 2018;43:137–143. Available at: https://www.ncbi.nlm.nih.gov/pubmed/28994134.

304. Vonderheid EC, Sajjadian A, Kadin ME. Methotrexate is effective therapy for lymphomatoid papulosis and other primary cutaneous CD30-positive lymphoproliferative disorders. J Am Acad Dermatol 1996;34:470–481. Available at: https://www.ncbi.nlm.nih.gov/pubmed/8609262.

305. Zackheim HS, Epstein EH, Jr., Crain WR. Topical carmustine therapy for lymphomatoid papulosis. Arch Dermatol 1985;121:1410–1414. Available at: https://www.ncbi.nlm.nih.gov/pubmed/4051529.

306. Thomsen K, Wantzin GL. Lymphomatoid papulosis. A follow-up study of 30 patients. J Am Acad Dermatol 1987;17:632–636. Available at: https://www.ncbi.nlm.nih.gov/pubmed/2889756.

Version 2.2026 © 2026 National Comprehensive Cancer Network© (NCCN©), All rights reserved. NCCN Guidelines® and this illustration may not be reproduced in any form without the express written permission of NCCN.

PLEASE NOTE that use of this NCCN Content is governed by the End-User License Agreement, and you MAY NOT distribute this Content or use it with any artificial intelligence model or tool.
Printed by Galya Basol Kochav on 2/16/2026 9:44:21 AM. Copyright © 2026 National Comprehensive Cancer Network, Inc. All Rights Reserved.

307. Calzavara-Pinton P, Venturini M, Sala R. Medium-dose UVA1 therapy of lymphomatoid papulosis. J Am Acad Dermatol 2005;52:530–532. Available at: https://www.ncbi.nlm.nih.gov/pubmed/15761440.

308. Everett MA. Treatment of lymphomatoid papulosis with methotrexate. Br J Dermatol 1984;111:631. Available at: https://www.ncbi.nlm.nih.gov/pubmed/6498098.

309. Christensen HK, Thomsen K, Vejlsgaard GL. Lymphomatoid papulosis: a follow-up study of 41 patients. Semin Dermatol 1994;13:197–201. Available at: https://www.ncbi.nlm.nih.gov/pubmed/7986688.

310. Yazawa N, Kondo S, Kagaya M, et al. Successful treatment of a patient with lymphomatoid papulosis by methotrexate. J Dermatol 2001;28:373–378. Available at: https://www.ncbi.nlm.nih.gov/pubmed/11510505.

311. Fujita H, Nagatani T, Miyazawa M, et al. Primary cutaneous anaplastic large cell lymphoma successfully treated with low-dose oral methotrexate. Eur J Dermatol 2008;18:360–361. Available at: https://www.ncbi.nlm.nih.gov/pubmed/18474486.

312. Cornejo CM, Novoa RA, Krisch RE, Kim EJ. Low-dose radiotherapy for primary cutaneous anaplastic large-cell lymphoma while on low-dose methotrexate. Cutis 2016;98:253–256. Available at: https://www.ncbi.nlm.nih.gov/pubmed/27874877.

313. Newland KM, McCormack CJ, Twigger R, et al. The efficacy of methotrexate for lymphomatoid papulosis. J Am Acad Dermatol 2015;72:1088–1090. Available at: https://www.ncbi.nlm.nih.gov/pubmed/25981010.

314. Lewis DJ, Talpur R, Huen AO, et al. Brentuximab vedotin for patients with refractory lymphomatoid papulosis: An analysis of phase 2 results. JAMA Dermatol 2017;153:1302–1306. Available at: https://www.ncbi.nlm.nih.gov/pubmed/28980004.

315. Melchers RC, Willemze R, Bekkenk MW, et al. Frequency and prognosis of associated malignancies in 504 patients with lymphomatoid papulosis. J Eur Acad Dermatol Venereol 2020;34:260–266. Available at: https://www.ncbi.nlm.nih.gov/pubmed/31715046.

316. Willemze R, Assaf C, Bagot M, et al. European Organisation for Research and Treatment of Cancer, United States Cutaneous Lymphoma Consortium and International Society for Cutaneous Lymphomas consensus recommendations for management and treatment of cutaneous lymphoproliferative disorders. Br J Dermatol 2025;193:1090–1100. Available at: https://www.ncbi.nlm.nih.gov/pubmed/40795052.

317. WHO Classification of Tumours Editorial Board. Haematolymphoid tumours. (WHO classification of tumours series, 5th ed.; vol. 11). Lyon (France): International Agency for Research on Cancer; 2024.

318. Arber DA, Borowitz MJ, Cook JR, et al. The International Consensus Classification of myeloid and lymphoid neoplasms (ed Edition 1); 2025.

319. Kempf W, Petrella T, Willemze R, et al. Clinical, histopathological and prognostic features of primary cutaneous acral CD8(+) T-cell lymphoma and other dermal CD8(+) cutaneous lymphoproliferations: results of an EORTC Cutaneous Lymphoma Group workshop. Br J Dermatol 2022;186:887–897. Available at: https://www.ncbi.nlm.nih.gov/pubmed/34988968.

320. Surmanowicz P, Doherty S, Sivanand A, et al. The clinical spectrum of primary cutaneous CD4+ small/medium-sized pleomorphic T-cell lymphoproliferative disorder: An updated systematic literature review and case series. Dermatology 2021;237:618–628. Available at: https://www.ncbi.nlm.nih.gov/pubmed/33326960.

321. Beltzung F, Ortonne N, Pelletier L, et al. Primary cutaneous CD4+ small/medium T-cell lymphoproliferative disorders: A clinical, pathologic, and molecular study of 60 cases presenting with a single lesion: A multicenter study of the French Cutaneous Lymphoma Study Group. Am J Surg Pathol 2020;44:862–872. Available at: https://www.ncbi.nlm.nih.gov/pubmed/32271188.

322. Ward J, Prince HM, McCormack C, et al. Excellent treatment outcomes from low dose radiation therapy for primary cutaneous CD4+

Version 2.2026 © 2026 National Comprehensive Cancer Network© (NCCN©), All rights reserved. NCCN Guidelines® and this illustration may not be reproduced in any form without the express written permission of NCCN.

PLEASE NOTE that use of this NCCN Content is governed by the End-User License Agreement, and you MAY NOT distribute this Content or use it with any artificial intelligence model or tool.
Printed by Galya Basol Kochav on 2/16/2026 9:44:21 AM. Copyright © 2026 National Comprehensive Cancer Network, Inc. All Rights Reserved.

small/medium T-Cell lymphoproliferative disorder. Radiother Oncol 2023;178:109430. Available at: https://www.ncbi.nlm.nih.gov/pubmed/36455687.

323. Wu SY, Damron EP, Xu J, et al. Radiotherapy in the treatment of primary cutaneous CD4+ small/medium T-cell lymphoproliferative disorder. Int J Dermatol 2025;64:385–389. Available at: https://www.ncbi.nlm.nih.gov/pubmed/38955474.

Version 2.2026 © 2026 National Comprehensive Cancer Network© (NCCN©), All rights reserved. NCCN Guidelines® and this illustration may not be reproduced in any form without the express written permission of NCCN.

PLEASE NOTE that use of this NCCN Content is governed by the End-User License Agreement, and you MAY NOT distribute this Content or use it with any artificial intelligence model or tool.
Printed by Galya Basol Kochav on 2/16/2026 9:44:21 AM. Copyright © 2026 National Comprehensive Cancer Network, Inc. All Rights Reserved.

This discussion corresponds to the NCCN Guidelines for Cutaneous Lymphomas. Last updated: December 9, 2025.

Subcutaneous Panniculitis-Like T-Cell Lymphoma

Subcutaneous panniculitis-like T-cell lymphoma (SPTCL) is a rare subtype of cutaneous T-cell lymphoma (CTCL) indicated by the presence of pleomorphic cytotoxic T-cell infiltrates primarily affecting subcutaneous tissues. First identified in 1991 by Gonzalez et al,[1] SPTCL commonly follows an indolent course consisting of erythematous subcutaneous nodules and plaques in the lower extremities, but lesions may develop anywhere on the body.[2-4] In unusual circumstances, adipocytes in other regions such as the mesentery can be affected by these malignant T-cells. SPTCL accounts for <1% of all non-Hodgkin lymphomas, with a 5-year survival average of 80%. Patients with SPTCL tend to be relatively younger with a slight bias for females, and may have a family or personal history of autoimmune disorders such as systemic lupus erythematous (SLE).[4-7] As the clinical presentation can mimic other benign inflammatory disorders, sufficient testing should be done to aid in the diagnosis.[8]

Initially, the term SPTCL represented two different entities that were categorized as having either alpha/beta or gamma/delta *TCR* expression, with the latter being the more aggressive phenotype. However, in 2008 the World Health Organization (WHO) reclassified and categorized SPTCL as only SPTCL-alpha/beta; the gamma/delta TCR-positive variant is listed as primary cutaneous gamma/delta T-cell lymphoma (PCGD-TCL).[9] The findings from a SEER database analysis (132 patients with SPTCL and 37 patients with PCGD-TCL diagnosed between 2006 and 2015) indicated that patients with PCGD-TCL were, on average, older, more likely to be male, and were at significantly higher risk of death than those with SPTCL (HR, 5.00; $P = .005$).[10] The alpha/beta TCR phenotype is often CD4-, CD8+, and often restricted to the subcutaneous tissues, which is less common in gamma/delta TCR phenotype in PCGD-TCL.[11,12] Adipocyte rimming by CD8+ T-cells alongside a high Ki-67 staining index is often detected specifically in SPTCL, while tumoral growth in bone marrow or mesenchymal structures is not typically observed.[4,13]

Occasionally, cutaneous findings/lesions can resolve with areas of lipodystrophy and hyperpigmentation without medical intervention. Systemic B symptoms such as fever, fatigue, excessive sweating during sleep, and weight loss are commonly reported in patients with SPTCL. The disease may be complicated by hemophagocytic lymphohistiocytosis (HLH), which is generally associated with a more aggressive course, and a reduced 5-year survival (~46%).[1,4,14] HLH is observed less frequently in SPTCL (~15%–25% of SPTCL cases) than in PCGD-TCL with panniculitis-like lesions.[15] Due to complications such as HLH, SPTCL may be associated with elevated liver enzymes, splenomegaly, and cytopenias.[16] Treatment of 17 patients with SPTCL with HLH resulted in an overall response rate (ORR) of 88%.[17] In cases complicated by HLH, treatment of HLH concurrently with treatment of lymphoma is recommended.

Literature Search Criteria

Prior to the update of this version of the NCCN Clinical Practice Guidelines in Oncology (NCCN Guidelines®), an electronic search of the PubMed database was performed to obtain key literature on SPTCL published since the previous Guidelines update using the following search terms: subcutaneous panniculitis-like T-cell lymphoma. The PubMed database was chosen as it remains the most widely used resource for medical literature and indexes peer-reviewed biomedical literature.[18]

The search results were narrowed by selecting studies in humans published in English. The data from key PubMed articles deemed as relevant to these guidelines have been included in this version of the Discussion section. Recommendations for which high-level evidence is

Version 2.2026 © 2026 National Comprehensive Cancer Network© (NCCN©), All rights reserved. NCCN Guidelines® and this illustration may not be reproduced in any form without the express written permission of NCCN.

PLEASE NOTE that use of this NCCN Content is governed by the End-User License Agreement, and you MAY NOT distribute this Content or use it with any artificial intelligence model or tool.
Printed by Galya Basol Kochav on 2/16/2026 9:44:21 AM. Copyright © 2026 National Comprehensive Cancer Network, Inc. All Rights Reserved.

lacking are based on the Panel's review of lower-level evidence and expert opinion.

The complete details of the Development and Update of the NCCN Guidelines® are available at www.NCCN.org.

Diagnosis

A precise diagnosis of SPTCL is challenging and requires several methods to fully verify. Patients generally present with multiple painless erythematous nodules or plaques on the lower extremities, upper extremities, or trunk. Multiple B symptoms (eg, fever, unintentional weight loss, pruritus) may accompany the external symptoms that a patient has; this is more common with HLH.[16,19] As previously mentioned, the disease is commonly limited to subcutaneous tissues, but more aggressive phenotypes may rarely exhibit dissemination into lymph nodes, peripheral blood, and bone marrow and rarely viscerally.

Upon initial presentation, deep subcutaneous skin biopsy (deep telescope punch biopsy vs. wedge excision) with adequate amount of adipose tissue (multiple skin biopsies, if necessary) and immunophenotyping is essential to establish an accurate diagnosis. SPTCL is commonly CD3+, CD8+, βF1+, CD2+, CD5+, and CD7+.[15,20,21]

In SPTCL, CD3, CD5, CD7, CD8, TCRbeta, TIA-1, and granzyme are positive in most cases.[22] CD8+ adipocyte-rimming T-cells involved in SPTCL frequently express high levels of Ki-67, a feature minimally observed in differential diagnoses such as lupus erythematosus panniculitis (LEP) and SLE.[6,22] Perforin and granzyme were present in 22 Asian patients with SPTCL, a common feature of malignant lymphocytes expressing CD8.[9,23,24]

Initial immunohistochemistry (IHC) panel may include TCRbeta, TCRdelta, CD2, CD3, CD20, CD4, CD5, CD7, CD8, CD30, and CD56. Additional IHC markers Ki-67, CD123, TIA1, perforin, granzyme-B, CD1a, TdT, and TCL1 will be useful in certain circumstances. In situ hybridization of Epstein-Barr virus-encoded RNA (EBER-ISH) is often included in the features tested when directing toward a diagnosis. In the majority of studies where a diagnosis of SPTCL is confirmed, the patients were EBER-ISH negative.[9,13,16,25-27] EBER positivity is a potential trigger for secondary HLH in patients with immune-related disease, and thus should be included in diagnostic procedures.

Molecular analysis to detect *TCR* gene rearrangements or other assessment of clonality are recommended to identify the clonality of T-cells.[22,28] Recurrent mutations in genes involved in epigenetic modification (*KMT2C* and *KMT2D*), and the PI3K/AKT/mTOR pathway (*PLCG1* and *ARID1B*) have been identified in SPTCL.[22,29]

An inherited autosomal recessive condition characterized by SPTCL with HLH resulting from germline mutations in *HAVCR2* can lead to unregulated immune cell activation. *HAVCR2* germline mutations (Y82C, I97M, and T101I) represent a well-documented genetic alteration present in 25% to 85% of patients with SPTCL and *HAVCR2* Y82C germline mutation is more prevalent in patients of Asian ancestry [24,31-33] *HAVCR2* encodes T-cell immunoglobulin mucin 3 (TIM-3) protein, which is an immune checkpoint molecule that regulates immune responses.[24,30] Significant changes in TIM-3 expression are associated with HLH, shorter relapse-free survival, refractory disease, and severe disease, which account for nearly 20% of all SPTCL cases.[14,15,31,34,35] Generally, *HAVCR2*–mutant SPTCL cases are controlled by immunosuppression. *HAVCR2* mutation is a useful marker that may aid in distinguishing SPTCL from non-malignant differential diagnoses and treatment decisions.[36]

Workup

Initial examination of patients with suspected SPTCL will generally consist of a thorough skin examination and palpations of abdominal organs as

Version 2.2026 © 2026 National Comprehensive Cancer Network© (NCCN©), All rights reserved. NCCN Guidelines® and this illustration may not be reproduced in any form without the express written permission of NCCN.

PLEASE NOTE that use of this NCCN Content is governed by the End-User License Agreement, and you MAY NOT distribute this Content or use it with any artificial intelligence model or tool.
Printed by Galya Basol Kochav on 2/16/2026 9:44:21 AM. Copyright © 2026 National Comprehensive Cancer Network, Inc. All Rights Reserved.

well as lymph node regions to check for any potential masses or growth. If a patient has a personal or family history of immunologic diseases including autoimmunity, genomic profiling, antinuclear antibody (ANA) with reflex, rheumatoid factor (RF), thyroid-stimulating hormone (TSH), and primary immunodeficiency (PID) gene panels may help to narrow down the diagnosis. A single positive result for any of these individual markers does not necessarily rule out SPTCL. However, an assessment for predispositions to autoimmune diseases is crucial to identify other conditions that can be mistaken for SPTCL.

Blood tests (eg, complete blood count [CBC] with differential) can reveal the relative number of relevant immune cells and markers, since there are many that exist that can point toward a more precise diagnosis. Markers such as lactate dehydrogenase (LDH) and ferritin are usually higher than normal when there is HLH involved in SPTCL. The Histiocyte Society outlines eight diagnostic criteria that include ferritin elevation[37] and serum LDH, which are also commonly elevated in patients with SPTCL.[16,38]

Bone marrow biopsy is important for the workup of suspected HLH or unexplained cytopenias.[26] Peripheral blood flow cytometry can be considered to rule out the diagnosis of other subtypes of T-cell lymphomas. However, SPTCL is not typically associated with peripheral blood involvement.

PET/CT scans are routinely utilized to assess the extent of disease, determine the stage, and identify disease locations. 18F-fluorodeoxyglucose (FDG)-PET/CT is used before and after treatment. Of 63 individuals who underwent PET/CT or CT, abnormal findings were present in 59 individuals (94%), revealing considerable involvement of subcutaneous fat. Additionally, avid adenopathy was reported in 23 (37%) of these individuals.[4] In a retrospective study of 11 patients with SPTCL, PET/CT revealed lesions with varying morphologies from multiple subcutaneous nodules.[39] FDG uptake was variable within each patient and among all lesions. Though diagnosis of SPTCL is reliant on IHC, PET/CT has utility in diagnostic confirmation and direction of biopsy of enlarged lymph nodes or other suspected FDG-avid extracutaneous sites.[39-41] Whole body FDG-PET/CT scan can be used to assess the extent of subcutaneous involvement and exclude systemic involvement.

Treatment Options

Since SPTCL is a rare subtype of lymphoma, there are not much data from large prospective trials to support a standardized treatment regimen or protocol. There are, however, several small studies and case reports that have helped illustrate some pathways for clinicians to treat patients with SPTCL. Published reports and studies have shown that treatment options for SPTCL vary widely in their dosing, efficacy, and responses, which is reflective of staging and diagnostic discrepancies. As mentioned previously, obtaining an accurate diagnosis and developing a treatment plan for patients with SPTCL is challenging, and requires more studies with extensive data.

While chemotherapy may be considered for patients presenting with HLH, immunomodulatory therapies are considered for patients who present without HLH.

A comparison of immunosuppressive drugs (n = 16) and polychemotherapy (n = 7) for SPTCL revealed that patients who received polychemotherapy showed a significantly lower complete response (CR) rate (28%) when compared to those receiving immunosuppressive drugs (81%).[20] The polychemotherapy regimens used were either CHOEP (cyclophosphamide, doxorubicin, vincristine, etoposide, and prednisone) or CHOP (cyclophosphamide, doxorubicin, vincristine, and prednisone)-related chemotherapy, while the immunosuppressive drugs given were corticosteroid alone or low-dose methotrexate, cyclosporine A (CsA), and hydroxychloroquine. These results were similar to Guitart et al who

Version 2.2026 © 2026 National Comprehensive Cancer Network© (NCCN©), All rights reserved. NCCN Guidelines® and this illustration may not be reproduced in any form without the express written permission of NCCN.

PLEASE NOTE that use of this NCCN Content is governed by the End-User License Agreement, and you MAY NOT distribute this Content or use it with any artificial intelligence model or tool.
Printed by Galya Basol Kochav on 2/16/2026 9:44:21 AM. Copyright © 2026 National Comprehensive Cancer Network, Inc. All Rights Reserved.

reported that patients with SPTCL receiving immunomodulatory therapies had comparable or better ORR than chemotherapy regimens.[4] The ORRs of CsA, methotrexate, bexarotene, and systemic steroids were 94%, 58%, 25%, and 33%, respectively. Further treatment regimens were required in patients with progressive SPTCL. The study concluded that immunomodulatory regimens could be beneficial prior to aggressive therapy with etoposide-containing chemotherapy regimens.

Chemotherapy-free regimens containing immunomodulatory drugs seem to result in improved disease control rates (compared to treatment with subsequent lines of chemotherapy) in patients with relapsed or refractory disease after first- and second-line chemotherapy.[42,43]

Limited available data on the use of immunomodulatory drugs and other single agents as treatment options for SPTCL are discussed below.

Cyclosporine A

CsA has been used successfully as both first- and second-line treatment for SPTCL. Several case studies of patients with SPTCL with and without HLH revealed that CsA was effective with minimal side effects and a sustained CR, regardless of previous treatments and responses to treatments.[44-51] In 11 patients with SPTCL receiving CsA, 6 achieved progression-free survival (PFS) ranging from 9 to 24 months.[44-46,50] CsA in combination with oral steroids in patients with SPTCL can control and occasionally eliminate disease with low probability of relapse.[27] Prior to single- or multi-agent chemotherapy, CsA may be an effective option, including in cases with early signs of HLH.

Bexarotene

Bexarotene, an oral retinoid used for CTCL, has been shown to be effective at treating patients with SPTCL with an ORR of 82% (11/13) in SPTCL.[52] Durable responses were observed in several patients at 57, 58, and 92 months, with a median duration of response of 26 months, and the median PFS of 38 months. In patients who received bexarotene as maintenance therapy following remission to chemotherapy, the effect of bexarotene alone cannot be established.

Pralatrexate

Pralatrexate has been used as a treatment for SPTCL-refractory chemotherapy regimens and immune suppressants. In a study of patients with SPTCL who had between two to four previous lines of therapy, pralatrexate treatment led to a CR in two patients, with the other two patients requiring further intervention.[53] In a recent study involving patients diagnosed with various cytotoxic CTCLs, seven individuals with SPTCL received pralatrexate as a single-agent therapy, resulting in a median time to next treatment (TTNT) of 18 months.[54] Pralatrexate was also successful as a bridging therapy to allogeneic HCT in selected patients. As a subsequent treatment for a patient with SPTCL refractory to chemotherapy, CsA, and allogeneic HCT, but without HLH, pralatrexate induced metabolic remission for >18 months.[55] As a single agent, pralatrexate may be considered as a first-line treatment option, an additional therapy for those with progressive disease, or as a maintenance therapy for those who have achieved a CR.

Methotrexate

Among 14 patients with SPTCL, treatment with methotrexate resulted in a response rate of 58% (five patients with a CR and two patients with a partial response [PR]).[4] In the same study, all patients without HLH had a positive response to methotrexate as a first-line therapy. Alongside prednisone, methotrexate helped a patient with SPTCL achieve remission for >21 months.[56] Combination of oral steroids and methotrexate or CsA led to a CR of 85% among 16 patients with SPTCL, and was associated with an estimated 5-year disease-specific survival of 88%.[27]

Version 2.2026 © 2026 National Comprehensive Cancer Network© (NCCN©), All rights reserved. NCCN Guidelines® and this illustration may not be reproduced in any form without the express written permission of NCCN.

PLEASE NOTE that use of this NCCN Content is governed by the End-User License Agreement, and you MAY NOT distribute this Content or use it with any artificial intelligence model or tool.
Printed by Galya Basol Kochav on 2/16/2026 9:44:21 AM. Copyright © 2026 National Comprehensive Cancer Network, Inc. All Rights Reserved.

Romidepsin

The efficacy of histone deacetylase inhibitors such as romidepsin as a potential treatment option for SPTCL has been demonstrated in case reports.[57,58,59] In the first case report, romidepsin was administered at standard dosing following the development of increased systemic symptoms with oral prednisone in one patient. After three cycles, all symptoms disappeared, with complete resolution of metabolic foci in subcutaneous tissue by PET/CT. Disease progression after prednisone and bexarotene led to treatment with romidepsin for two cycles in the second patient. A CR was seen upon PET/CT. Romidepsin was employed to treat SPTCL refractory to prednisone, methotrexate, bexarotene, hydroxychloroquine, and acitretin.[59] After starting romidepsin, 50% of nodules disappeared. The patient achieved a CR at 12 months, and treatment was discontinued at 18 months. No evidence of disease progression was reported. In a later study, two patients, one with SPTCL and the other with PCGD-TCL, received romidepsin among other treatments.[57] The patient with SPTCL remained in CR (median follow-up of 5 years) with no evidence of disease recurrence, while the patient with PCGD-TCL experienced disease progression after romidepsin treatment. More recently, among 22 patients with SPTCL, nine received romidepsin as a single agent, resulting in a median TTNT of 10 months.[54]

Chemotherapy

Optimal first-line combination chemotherapy in patients with SPTCL has been widely debated since SPTCL was classified as its own disease. In selected patients requiring chemotherapy, combination chemotherapy regimens have resulted in favorable response rates.[4,12,60]

In a large retrospective analysis of 75 patients with SPTCL, 73 received chemotherapy, many of which contained etoposide (eg, CHOEP [cyclophosphamide, doxorubicin, vincristine, etoposide, and prednisone]; ICE [ifosfamide, carboplatin, and etoposide]; SMILE [dexamethasone, methotrexate, ifosfamide, and etoposide]; CDE [cyclophosphamide, doxorubicin, and etoposide]; and CMED [cyclophosphamide, etoposide, methotrexate, and dexamethasone]).[4] The ORR for the entire cohort was 72%, with 47% achieving a CR and 22% achieving a PR.

In several instances, SPTCL becomes refractory after treatment with CHOP and alternative interventions with CsA[44] or hematopoietic cell transplant (HCT) are needed for the treatment of refractory disease.[49,57,61,62] The presence of *HAVCR2* mutations also confers resistance to CHOP chemotherapy, necessitating subsequent treatment with immunosuppressive regimens or HCT.[33]

Hematopoietic Cell Transplant

HCT may be an effective treatment option for SPTCL, especially in patients with progressive or refractory disease after first-line systemic therapy.[49,63] Mou et al reported that in five patients with SPTCL with HLH who underwent allogeneic HCT, all of them were alive after a median follow-up of 3 years.[54] Autologous HCT was also successful at treating aggressive SPTCL with HLH in various case reports.[61,64,65,66] HCT has led to durable remissions in patients with SPTCL with HLH (range 30–132 months) and an equivalent 3-year survival (80%) when compared to patients with SPTCL without HLH.[65] A similar result was seen in a patient with B cell expansion with NF-κB and T-cell anergy (BENTA) disease who developed SPTCL. The patient required an autologous HCT for progressive disease after multiple treatment regimens.[51]

NCCN Recommendations

Treatment options outlined in the NCCN Guidelines for patients with SPTCL are based on the presence of HLH and the extent of tumor burden (limited or localized vs. widespread subcutaneous disease).

Version 2.2026 © 2026 National Comprehensive Cancer Network© (NCCN©), All rights reserved. NCCN Guidelines® and this illustration may not be reproduced in any form without the express written permission of NCCN.

PLEASE NOTE that use of this NCCN Content is governed by the End-User License Agreement, and you MAY NOT distribute this Content or use it with any artificial intelligence model or tool.
Printed by Galya Basol Kochav on 2/16/2026 9:44:21 AM. Copyright © 2026 National Comprehensive Cancer Network, Inc. All Rights Reserved.

SPTCL with HLH, Systemic Disease, or High Tumor Burden (Widespread Subcutaneous Disease)

First-Line Therapy

Single agents (CsA, pralatrexate, or romidepsin) with or without prednisone or etoposide-based combination chemotherapy regimens can be considered as options for first-line therapy.[4,54] It is recommended to start with etoposide-based regimens to control HLH first and then move to disease-specific therapies. Oral CsA is typically initiated at 3–5 mg/kg/day in divided doses.[44-46] Dose adjustment is based on response and tolerance. Higher dosage may be necessary to achieve disease control. Involved-site radiation therapy (ISRT) can be considered for single lesion or limited disease with or without symptoms or HLH.

Etoposide-based combination chemotherapy regimens including CHOEP, or DA-EPOCH (dose-adjusted etoposide, prednisone, vincristine, cyclophosphamide, and doxorubicin) or ESHA (etoposide, methylprednisolone, and high-dose cytarabine) + cisplatin or oxaliplatin or ICE are also appropriate options for patients who are eligible for transplant.[4]

Response Assessment and Additional Therapy

Depending on the response to first-line therapy (CR or PR), options such as observation or single-agent maintenance therapy (CsA, pralatrexate, romidepsin, methotrexate, or bexarotene) are recommended.[52,53,55,58] Most patients will achieve a PR after first-line therapy, with a CR being less common. Generally, maintenance therapy is utilized for patients with disease who achieve some clinical benefit and/or those with disease responding to first-line therapy. Additionally, if a more marked response is seen, tapering of regimens to optimize duration of response is feasible. Select patients with SPTCL may be candidates for allogeneic HCT, depending on response to first-line therapy.[63,65] Patients who do not achieve an adequate response to first-line therapy may be given a different first-line therapy or the same therapy at a higher dose to achieve disease control.[44,49]

Patients with disease relapse (after a period of observation or maintenance therapy) should receive treatment with either the same regimen previously given or an alternate regimen that was not given as first-line therapy. Patients with disease relapse or refractory disease after multiple prior therapies may be recommended to enroll in clinical trials or to consider allogeneic HCT (if eligible).[57,61,65]

SPTCL Without HLH and Low Tumor Burden (Localized or Limited Subcutaneous Disease)

First-Line Therapy

Single agents (CsA, methotrexate, or bexarotene), with or without prednisone, can be considered as options for first-line therapy.[4,27,50,56] As mentioned above for SPTCL with HLH, CsA is typically initiated at 3–5 mg/kg/day in divided doses. It may be necessary to increase the dose to achieve disease control. Dose adjustment is based on response and tolerance. ISRT can be considered as a local therapy for single lesion or limited disease with and without symptoms of HLH.

Response Assessment and Additional Therapy

Depending on the response to first-line therapy (CR or PR), options such as observation or single-agent maintenance therapy (CsA, pralatrexate, romidepsin, methotrexate, or bexarotene) are recommended.[4,52,53,55,58] Regarding CsA, gradual tapering or continuation as maintenance can be considered for patients with disease responding to first-line therapy. If single-agent therapy results in clinical benefits or adequate response to first-line therapy, the single-agent therapy may be gradually tapered to optimize duration of response or used as maintenance therapy.

Patients who do not achieve an adequate response to first-line therapy may be given a different first-line therapy or a local therapy (if not given as

Version 2.2026 © 2026 National Comprehensive Cancer Network© (NCCN©), All rights reserved. NCCN Guidelines® and this illustration may not be reproduced in any form without the express written permission of NCCN.

PLEASE NOTE that use of this NCCN Content is governed by the End-User License Agreement, and you MAY NOT distribute this Content or use it with any artificial intelligence model or tool.
Printed by Galya Basol Kochav on 2/16/2026 9:44:21 AM. Copyright © 2026 National Comprehensive Cancer Network, Inc. All Rights Reserved.

a first-line therapy) to achieve disease control. Further, pralatrexate or romidepsin can be given with or without prednisone as additional therapies if other treatment options are insufficient.

Patients may experience relapse after a period of observation or maintenance therapy. Retreatment with the same regimen used previously or an alternate regimen not used in first-line therapy may be considered to prevent disease progression. However, relapse or refractory disease after multiple previous therapies may occur, which may warrant a patient enrolling in a clinical trial, or consideration of an alternate regimen not previously used, such as in SPTCL with HLH, systemic disease, or high tumor burden.

Version 2.2026 © 2026 National Comprehensive Cancer Network© (NCCN©), All rights reserved. NCCN Guidelines® and this illustration may not be reproduced in any form without the express written permission of NCCN.

PLEASE NOTE that use of this NCCN Content is governed by the End-User License Agreement, and you MAY NOT distribute this Content or use it with any artificial intelligence model or tool.
Printed by Galya Basol Kochav on 2/16/2026 9:44:21 AM. Copyright © 2026 National Comprehensive Cancer Network, Inc. All Rights Reserved.

References

1. Gonzalez CL, Medeiros LJ, Braziel RM, Jaffe ES. T-cell lymphoma involving subcutaneous tissue. A clinicopathologic entity commonly associated with hemophagocytic syndrome. Am J Surg Pathol 1991;15:17–27. Available at: https://www.ncbi.nlm.nih.gov/pubmed/1985499.

2. Salhany KE, Macon WR, Choi JK, et al. Subcutaneous panniculitis-like T-cell lymphoma: clinicopathologic, immunophenotypic, and genotypic analysis of alpha/beta and gamma/delta subtypes. Am J Surg Pathol 1998;22:881–893. Available at: https://www.ncbi.nlm.nih.gov/pubmed/9669350.

3. Hahtola S, Burghart E, Jeskanen L, et al. Clinicopathological characterization and genomic aberrations in subcutaneous panniculitis-like T-cell lymphoma. J Invest Dermatol 2008;128:2304–2309. Available at: https://www.ncbi.nlm.nih.gov/pubmed/18337827.

4. Guitart J, Mangold AR, Martinez-Escala ME, et al. Clinical and pathological characteristics and outcomes among patients with subcutaneous panniculitis-like T-cell lymphoma and related adipotropic lymphoproliferative disorders. JAMA Dermatol 2022;158:1167–1174. Available at: https://www.ncbi.nlm.nih.gov/pubmed/36001337.

5. Bosisio FM, Cerroni L. Expression of T-follicular helper markers in sequential biopsies of progressive mycosis fungoides and other primary cutaneous T-cell lymphomas. Am J Dermatopathol 2015;37:115–121. Available at: https://www.ncbi.nlm.nih.gov/pubmed/25406852.

6. LeBlanc RE, Tavallaee M, Kim YH, Kim J. Useful parameters for distinguishing subcutaneous panniculitis-like T-cell lymphoma from lupus erythematosus panniculitis. Am J Surg Pathol 2016;40:745–754. Available at: https://www.ncbi.nlm.nih.gov/pubmed/26796503.

7. Bhatt VR, Giri S, Verma V, et al. Survival of subcutaneous panniculitis-like T-cell lymphoma and peripheral T-cell lymphoma not otherwise specified: A propensity-matched analysis of the Surveillance, Epidemiology, and End Results Database. Clin Lymphoma Myeloma Leuk 2016;16:373–378. Available at: https://www.ncbi.nlm.nih.gov/pubmed/27349764.

8. Yamamoto Y, Mitsui A, Noda K, et al. Subcutaneous panniculitis-like T-cell lymphoma with a HAVCR2 mutation diagnosed after 10 years of treatment with glucocorticoids and cyclosporine as lupus panniculitis. Intern Med 2023;62:1537–1540. Available at: https://www.ncbi.nlm.nih.gov/pubmed/36171125.

9. Kong YY, Dai B, Kong JC, et al. Subcutaneous panniculitis-like T-cell lymphoma: a clinicopathologic, immunophenotypic, and molecular study of 22 Asian cases according to WHO-EORTC classification. Am J Surg Pathol 2008;32:1495–1502. Available at: https://www.ncbi.nlm.nih.gov/pubmed/18708940.

10. Goyal A, Goyal K, Bohjanen K, Pearson D. Epidemiology of primary cutaneous gammadelta T-cell lymphoma and subcutaneous panniculitis-like T-cell lymphoma in the U.S.A. from 2006 to 2015: a Surveillance, Epidemiology, and End Results-18 analysis. Br J Dermatol 2019;181:848–850. Available at: https://www.ncbi.nlm.nih.gov/pubmed/30951189.

11. Willemze R, Jaffe ES, Burg G, et al. WHO-EORTC classification for cutaneous lymphomas. Blood 2005;105:3768–3785. Available at: https://www.ncbi.nlm.nih.gov/pubmed/15692063.

12. Go RS, Wester SM. Immunophenotypic and molecular features, clinical outcomes, treatments, and prognostic factors associated with subcutaneous panniculitis-like T-cell lymphoma: a systematic analysis of 156 patients reported in the literature. Cancer 2004;101:1404–1413. Available at: https://www.ncbi.nlm.nih.gov/pubmed/15368328.

13. Rutnin S, Porntharukcharoen S, Boonsakan P. Clinicopathologic, immunophenotypic, and molecular analysis of subcutaneous panniculitis-like T-cell lymphoma: A retrospective study in a tertiary care center. J Cutan Pathol 2019;46:44–51. Available at: https://www.ncbi.nlm.nih.gov/pubmed/30350476.

14. Koh J, Jang I, Mun S, et al. Genetic profiles of subcutaneous panniculitis-like T-cell lymphoma and clinicopathological impact of

Version 2.2026 © 2026 National Comprehensive Cancer Network© (NCCN©), All rights reserved. NCCN Guidelines® and this illustration may not be reproduced in any form without the express written permission of NCCN.

PLEASE NOTE that use of this NCCN Content is governed by the End-User License Agreement, and you MAY NOT distribute this Content or use it with any artificial intelligence model or tool.
Printed by Galya Basol Kochav on 2/16/2026 9:44:21 AM. Copyright © 2026 National Comprehensive Cancer Network, Inc. All Rights Reserved.

HAVCR2 mutations. Blood Adv 2021;5:3919–3930. Available at: https://www.ncbi.nlm.nih.gov/pubmed/34535012.

15. Willemze R, Jansen PM, Cerroni L, et al. Subcutaneous panniculitis-like T-cell lymphoma: definition, classification, and prognostic factors: an EORTC Cutaneous Lymphoma Group Study of 83 cases. Blood 2008;111:838–845. Available at: https://www.ncbi.nlm.nih.gov/pubmed/17934071.

16. Ghobrial IM, Weenig RH, Pittlekow MR, et al. Clinical outcome of patients with subcutaneous panniculitis-like T-cell lymphoma. Leuk Lymphoma 2005;46:703–708. Available at: https://www.ncbi.nlm.nih.gov/pubmed/16019507.

17. Ou W, Zhao Y, Wei A, et al. Subcutaneous panniculitis-like T-cell lymphoma associated with hemophagocytic lymphohistiocytosis: a systematic review of 63 patients reported in the literature. Clin Exp Med 2023;23:4575–4583. Available at: https://www.ncbi.nlm.nih.gov/pubmed/37840116.

18. PubMed Overview. Available at: https://pubmed.ncbi.nlm.nih.gov/about/. Accessed February 12, 2025.

19. Parveen Z, Thompson K. Subcutaneous panniculitis-like T-cell lymphoma: redefinition of diagnostic criteria in the recent World Health Organization-European Organization for Research and Treatment of Cancer classification for cutaneous lymphomas. Arch Pathol Lab Med 2009;133:303–308. Available at: https://www.ncbi.nlm.nih.gov/pubmed/19195975.

20. Michonneau D, Petrella T, Ortonne N, et al. Subcutaneous Panniculitis-like T-cell Lymphoma: Immunosuppressive Drugs Induce Better Response than Polychemotherapy. Acta Derm Venereol 2017;97:358–364. Available at: https://www.ncbi.nlm.nih.gov/pubmed/27722764.

21. Maliniemi P, Hahtola S, Ovaska K, et al. Molecular characterization of subcutaneous panniculitis-like T-cell lymphoma reveals upregulation of immunosuppression- and autoimmunity-associated genes. Orphanet J Rare Dis 2014;9:160. Available at: https://www.ncbi.nlm.nih.gov/pubmed/25928531.

22. Fernandez-Pol S, Costa HA, Steiner DF, et al. High-throughput sequencing of subcutaneous panniculitis-like T-cell lymphoma reveals candidate pathogenic mutations. Appl Immunohistochem Mol Morphol 2019;27:740–748. Available at: https://www.ncbi.nlm.nih.gov/pubmed/31702703.

23. Guenova E, Schanz S, Hoetzenecker W, et al. Systemic corticosteroids for subcutaneous panniculitis-like T-cell lymphoma. Br J Dermatol 2014;171:891–894. Available at: https://www.ncbi.nlm.nih.gov/pubmed/24725144.

24. Gayden T, Sepulveda FE, Khuong-Quang DA, et al. Germline HAVCR2 mutations altering TIM-3 characterize subcutaneous panniculitis-like T cell lymphomas with hemophagocytic lymphohistiocytic syndrome. Nat Genet 2018;50:1650–1657. Available at: https://www.ncbi.nlm.nih.gov/pubmed/30374066.

25. Alsomali DY, Bakshi N, Kharfan-Dabaja M, et al. Diagnosis and Treatment of Subcutaneous Panniculitis-like T-cell Lymphoma: A Systematic Literature Review. Hematol Oncol Stem Cell Ther 2023;16:110–116. Available at: https://www.ncbi.nlm.nih.gov/pubmed/34015273.

26. Gochhait D, Kekade S, Devi D, et al. Subcutaneous panniculitis-like T-cell lymphoma: approach to differential diagnosis on cytology. J Adolesc Young Adult Oncol 2020;9:120–123. Available at: https://www.ncbi.nlm.nih.gov/pubmed/31580741.

27. Lopez-Lerma I, Penate Y, Gallardo F, et al. Subcutaneous panniculitis-like T-cell lymphoma: Clinical features, therapeutic approach, and outcome in a case series of 16 patients. J Am Acad Dermatol 2018;79:892–898. Available at: https://www.ncbi.nlm.nih.gov/pubmed/30126736.

28. Hoque SR, Child FJ, Whittaker SJ, et al. Subcutaneous panniculitis-like T-cell lymphoma: a clinicopathological, immunophenotypic and

Version 2.2026 © 2026 National Comprehensive Cancer Network© (NCCN©), All rights reserved. NCCN Guidelines® and this illustration may not be reproduced in any form without the express written permission of NCCN.

PLEASE NOTE that use of this NCCN Content is governed by the End-User License Agreement, and you MAY NOT distribute this Content or use it with any artificial intelligence model or tool.
Printed by Galya Basol Kochav on 2/16/2026 9:44:21 AM. Copyright © 2026 National Comprehensive Cancer Network, Inc. All Rights Reserved.

molecular analysis of six patients. Br J Dermatol 2003;148:516–525. Available at: https://www.ncbi.nlm.nih.gov/pubmed/12653744.

29. Li Z, Lu L, Zhou Z, et al. Recurrent mutations in epigenetic modifiers and the PI3K/AKT/mTOR pathway in subcutaneous panniculitis-like T-cell lymphoma. Br J Haematol 2018;181:406–410. Available at: https://www.ncbi.nlm.nih.gov/pubmed/28294301.

30. Polprasert C, Takeuchi Y, Kakiuchi N, et al. Frequent germline mutations of HAVCR2 in sporadic subcutaneous panniculitis-like T-cell lymphoma. Blood Adv 2019;3:588–595. Available at: https://www.ncbi.nlm.nih.gov/pubmed/30792187.

31. Sonigo G, Battistella M, Beylot-Barry M, et al. HAVCR2 mutations are associated with severe hemophagocytic syndrome in subcutaneous panniculitis-like T-cell lymphoma. Blood 2020;135:1058–1061. Available at: https://www.ncbi.nlm.nih.gov/pubmed/32005988.

32. Cheng J, Xi L, Jang Y, et al. An investigation of germline variants of HAVCR2 in subcutaneous panniculitis-like T-cell lymphoma and related lesions in a North American population. Haematologica 2024;109:3363–3367. Available at: https://www.ncbi.nlm.nih.gov/pubmed/38867583.

33. Okamura Y, Makishima K, Suehara Y, et al. Genetic profiles and clinical features in subcutaneous panniculitis-like T-cell lymphomas. Cancer Sci 2024;115:3788–3794. Available at: https://www.ncbi.nlm.nih.gov/pubmed/39288772.

34. Zhang Y, Wang Z, Hu G, et al. A novel germline HAVCR2 (TIM-3) compound heterozygous mutation is related to hemophagocytic lymphohistiocytic syndrome in EBV-positive peripheral T-cell lymphoma (NOS) with down-regulated TIM-3 signaling. Front Oncol 2022;12:870676. Available at:

35. Moonla C, Polprasert C, Komvilaisak P, et al. Germline HAVCR2 mutations and their relation to the clinical spectrum of subcutaneous panniculitis-like T-cell lymphoma and hemophagocytic lymphohistiocytosis: results from a multicenter study and meta-analysis. Haematologica 2023;108:2743–2752. Available at: https://www.ncbi.nlm.nih.gov/pubmed/37051767.

36. Machan S, Rodriguez M, Alonso-Alonso R, et al. Subcutaneous panniculitis-like T-cell lymphoma, lupus erythematosus profundus, and overlapping cases: molecular characterization through the study of 208 genes. Leuk Lymphoma 2021;62:2130–2140. Available at: https://www.ncbi.nlm.nih.gov/pubmed/33966586.

37. La Rosee P, La Rosee F. HLH: diagnostics revisited and improved. Blood 2024;144:2274–2275. Available at: https://www.ncbi.nlm.nih.gov/pubmed/39607714.

38. Tran NT, Nguyen KT, Le LT, et al. Subcutaneous panniculitis-like T-cell lymphoma with hemophagocytic lymphohistiocytosis. J Investig Med High Impact Case Rep 2024;12:23247096241253337. Available at: https://www.ncbi.nlm.nih.gov/pubmed/38742532.

39. Jiang M, Zhao L, Zheng J, et al. Report of eleven patients of subcutaneous panniculitis-like T-cell lymphoma: clinicopathologic features, (18)F-FDG PET/CT findings and outcome. Front Oncol 2021;11:650822. Available at: https://www.ncbi.nlm.nih.gov/pubmed/34277404.

40. Oztek MA, Elhussein W, Parisi MT. SNMMI PIC case competition finalist: Subcutaneous panniculitis-like T-cell lymphoma on 18 F-FDG PET/CT. Clin Nucl Med 2025;50:e173–e174. Available at: https://www.ncbi.nlm.nih.gov/pubmed/39774428.

41. Kim JW, Chae EJ, Park YS, et al. Radiological and clinical features of subcutaneous panniculitis-like T-cell lymphoma. J Comput Assist Tomogr 2011;35:394–401. Available at: https://www.ncbi.nlm.nih.gov/pubmed/21586937.

42. Chen C, Yin J, Duan M, et al. Chemo-free salvage treatment outperforms traditional chemotherapy in advanced lines of relapsed/refractory subcutaneous panniculitis-like T-cell lymphoma. Front Immunol 2024;15:1476875. Available at: https://www.ncbi.nlm.nih.gov/pubmed/39717785.

Version 2.2026 © 2026 National Comprehensive Cancer Network© (NCCN©), All rights reserved. NCCN Guidelines® and this illustration may not be reproduced in any form without the express written permission of NCCN.

PLEASE NOTE that use of this NCCN Content is governed by the End-User License Agreement, and you MAY NOT distribute this Content or use it with any artificial intelligence model or tool.
Printed by Galya Basol Kochav on 2/16/2026 9:44:21 AM. Copyright © 2026 National Comprehensive Cancer Network, Inc. All Rights Reserved.

43. Duan Y, Gao H, Zhou C, et al. A retrospective study of 18 children with subcutaneous panniculitis-like T-cell lymphoma: multidrug combination chemotherapy or immunomodulatory therapy? Orphanet J Rare Dis 2022;17:432. Available at: https://www.ncbi.nlm.nih.gov/pubmed/36503528.

44. Rojnuckarin P, Nakorn TN, Assanasen T, et al. Cyclosporin in subcutaneous panniculitis-like T-cell lymphoma. Leuk Lymphoma 2007;48:560–563. Available at: https://www.ncbi.nlm.nih.gov/pubmed/17454599.

45. Al Zolibani AA, Al Robaee AA, Qureshi MG, Al Nosian H. Subcutaneous panniculitis-like T-cell lymphoma with hemophagocytic syndrome successfully treated with cyclosporin A. Skinmed 2006;5:195–197. Available at: https://www.ncbi.nlm.nih.gov/pubmed/16855414.

46. Mizutani S, Kuroda J, Shimura Y, et al. Cyclosporine A for chemotherapy-resistant subcutaneous panniculitis-like T cell lymphoma with hemophagocytic syndrome. Acta Haematol 2011;126:8–12. Available at: https://www.ncbi.nlm.nih.gov/pubmed/21411984.

47. Iqbal N, Raina V. Successful treatment of disseminated subcutaneous panniculitis-like T-cell lymphoma with single agent oral cyclosporine as a first line therapy. Case Rep Dermatol Med 2014;2014:201836. Available at: https://www.ncbi.nlm.nih.gov/pubmed/25506440.

48. Aragon-Miguel R, Calleja-Algarra A, Velasco-Tamariz V, et al. Is cyclosporine a good option for the treatment of subcutaneous panniculitis-like T-cell lymphoma associated with hemophagocytic syndrome? Indian J Dermatol Venereol Leprol 2019;85:656–659. Available at: https://www.ncbi.nlm.nih.gov/pubmed/31571617.

49. Jung HR, Yun SY, Choi JH, et al. Cyclosporine in relapsed subcutaneous panniculitis-like T-cell lymphoma after autologous hematopoietic stem cell transplantation. Cancer Res Treat 2011;43:255–259. Available at: https://www.ncbi.nlm.nih.gov/pubmed/22247712.

50. Tsukamoto Y, Katsunobu Y, Omura Y, et al. Subcutaneous panniculitis-like T-cell lymphoma: successful initial treatment with prednisolone and cyclosporin A. Intern Med 2006;45:21–24. Available at: https://www.ncbi.nlm.nih.gov/pubmed/16467600.

51. Bauman BM, Dorjbal B, Pittaluga S, et al. Subcutaneous panniculitis-like T-cell lymphoma in two unrelated individuals with BENTA disease. Clin Immunol 2023;255:109732. Available at: https://www.ncbi.nlm.nih.gov/pubmed/37562721.

52. Mehta N, Wayne AS, Kim YH, et al. Bexarotene is active against subcutaneous panniculitis-like T-cell lymphoma in adult and pediatric populations. Clin Lymphoma Myeloma Leuk 2012;12:20–25. Available at: https://www.ncbi.nlm.nih.gov/pubmed/22001256.

53. Ware O, Tarabadkar ES, Shustov A, Shinohara MM. Pralatrexate for refractory or recurrent subcutaneous panniculitis-like T-cell lymphoma with hemophagocytic syndrome. J Am Acad Dermatol 2020;82:489–491. Available at: https://www.ncbi.nlm.nih.gov/pubmed/31319088.

54. Mou E, Fernandez-Pol S, Li S, et al. Clinical characteristics, treatment patterns, and outcomes of cytotoxic cutaneous T-cell lymphomas. Am J Hematol 2024;99:985–988. Available at: https://www.ncbi.nlm.nih.gov/pubmed/38391088.

55. Ong SY, Phipps C, Kaur H, et al. Pralatrexate induces long-term remission in relapsed subcutaneous panniculitis-like T-cell lymphoma. Ann Acad Med Singap 2019;48:298–300. Available at: https://www.ncbi.nlm.nih.gov/pubmed/31737895.

56. Grinich E, Koon SM, Cascio MJ, Fett N. Subcutaneous panniculitis-like T-cell lymphoma responsive to combination therapy with methotrexate and corticosteroids. Dermatol Online J 2018;24. Available at: https://www.ncbi.nlm.nih.gov/pubmed/30677832.

57. Gibson JF, Alpdogan O, Subtil A, et al. Hematopoietic stem cell transplantation for primary cutaneous gammadelta T-cell lymphoma and refractory subcutaneous panniculitis-like T-cell lymphoma. J Am Acad Dermatol 2015;72:1010–1015 e1015. Available at: https://www.ncbi.nlm.nih.gov/pubmed/25981001.

Version 2.2026 © 2026 National Comprehensive Cancer Network© (NCCN©), All rights reserved. NCCN Guidelines® and this illustration may not be reproduced in any form without the express written permission of NCCN.

PLEASE NOTE that use of this NCCN Content is governed by the End-User License Agreement, and you MAY NOT distribute this Content or use it with any artificial intelligence model or tool.
Printed by Galya Basol Kochav on 2/16/2026 9:44:21 AM. Copyright © 2026 National Comprehensive Cancer Network, Inc. All Rights Reserved.

58. Bashey S, Krathen M, Abdulla F, et al. Romidepsin is effective in subcutaneous panniculitis-like T-cell lymphoma. J Clin Oncol 2012;30:e221–225. Available at: https://www.ncbi.nlm.nih.gov/pubmed/22753921.

59. Jothishankar B, Espinosa ML, Zain J, et al. Complete response to romidepsin as monotherapy in treatment-resistant subcutaneous panniculitis-like T-cell lymphoma. JAAD Case Rep 2020;6:1245–1247. Available at: https://www.ncbi.nlm.nih.gov/pubmed/33294555.

60. Ohtsuka M, Miura T, Yamamoto T. Clinical characteristics, differential diagnosis, and treatment outcome of subcutaneous panniculitis-like T-cell lymphoma: a literature review of published Japanese cases. Eur J Dermatol 2017;27:34–41. Available at: https://www.ncbi.nlm.nih.gov/pubmed/28120776.

61. Dholaria B, Patel RJ, Sluzevich JC, et al. Relapsed subcutaneous panniculitis-like T cell lymphoma: role of haploidentical hematopoietic stem cell transplant. Ann Hematol 2017;96:2125–2126. Available at: https://www.ncbi.nlm.nih.gov/pubmed/28879427.

62. Nakahashi H, Tsukamoto N, Yamane A, et al. Autologous peripheral blood stem cell transplantation to treat CHOP-refractory aggressive subcutaneous panniculitis-like T cell lymphoma. Acta Haematol 2009;121:239–242. Available at: https://www.ncbi.nlm.nih.gov/pubmed/19556752.

63. Yuan L, Sun L, Bo J, et al. Durable remission in a patient with refractory subcutaneous panniculitis-like T-cell lymphoma relapse after allogeneic hematopoietic stem cell transplantation through withdrawal of cyclosporine. Ann Transplant 2011;16:135–138. Available at: https://www.ncbi.nlm.nih.gov/pubmed/21959522.

64. Alaibac M, Berti E, Pigozzi B, et al. High-dose chemotherapy with autologous blood stem cell transplantation for aggressive subcutaneous panniculitis-like T-cell lymphoma. J Am Acad Dermatol 2005;52:S121–123. Available at: https://www.ncbi.nlm.nih.gov/pubmed/15858508.

65. Lin TA, Yang CF, Liu YC, et al. Hematopoietic stem cell transplantation for subcutaneous panniculitis-like T-cell lymphoma: single center experience in an Asian population. Int J Hematol 2019;109:187–196. Available at: https://www.ncbi.nlm.nih.gov/pubmed/30547418.

66. Mukai HY, Okoshi Y, Shimizu S, et al. Successful treatment of a patient with subcutaneous panniculitis-like T-cell lymphoma with high-dose chemotherapy and total body irradiation. Eur J Haematol 2003;70:413–416. Available at: https://www.ncbi.nlm.nih.gov/pubmed/12756026.

Version 2.2026 © 2026 National Comprehensive Cancer Network© (NCCN©), All rights reserved. NCCN Guidelines® and this illustration may not be reproduced in any form without the express written permission of NCCN.